

Comparison Between the Parietal Foramina Observed in Samples of African and European Population Groups

Comparación entre los Forámenes Parietales Observados en Muestras de Grupos de Población Africanos y Europeos

Soné van der Walt¹; Niels Hammer^{2,3,4} & Lané Prigge¹

VAN DER WALT, S.; HAMMER, N. & PRIGGE, L. Comparison between the parietal foramina observed in samples of African and European population groups. *Int. J. Morphol.*, 41(2):634-639, 2023.

SUMMARY: Parietal foramina of the human skull act as a passageway for emissary veins, connecting the superior sagittal sinus to the veins of the scalp. This passageway can lead to the spread of infection from the scalp to the dural venous sinuses, but may also assist in relieving intracranial pressure. However, variation in the prevalence of parietal foramina has been noted among population groups. This observational and descriptive study aimed to determine the incidence, size and location of parietal foramina by using osteological specimens of 252 African skulls from the Sefako Makgatho Health Sciences University, South Africa and 95 European skulls from the University of Leipzig, Germany. Parietal foramina were significantly more common in the African sample (61.9 %) compared to the European sample (55.8 %). Moreover, the Central European sample displayed more unilateral foramina (29.5 %), while the African sample exhibited more bilateral foramina (40.8 %). The diameter of the parietal foramen average 1.98 mm and 1.88 mm for the European and African samples, respectively. In this study, a median foramen on the sagittal suture was observed in 14 of the overall skull caps (4 %). This study demonstrated that parietal foramina are more prevalent than anticipated in both population groups. Findings of this study, indicating an increased prevalence, and the subsequent possibility of more emissary veins encountered, can be used to improve the understanding of the variations in the prevalence and clinical implications of the parietal foramen among various population groups located world-wide.

KEY WORDS Epidemiology; Intracranial pressure; Parietal foramen; Prevalence; Calvarium.

INTRODUCTION

The skull consists of two functionally and morphologically distinct structures, the cranial vault or neurocranium and the viscerocranium. The majority of the bones of the cranial vault consist of two layers of compact bone, enclosing a dense diploic bone. These bones are formed through intramembranous ossification of a highly vascular connective tissue membrane. The human skull comprises of twenty-two cranial and facial bones, including the parietal bones. The sagittal suture, in the midline, extends from the bregma anteriorly to the lambda posteriorly, separating the two parietal bones (Strandring *et al.*, 2008).

Emissary foramina are small foramina found in the neurocranium that transmit emissary veins which connect

the extracranial venous system with the dural venous sinuses and meningeal veins (Boyd, 1930). This passageway is clinically relevant as it acts as a route for the spread of an extracranial infection to intracranial structures, and may also lead to complications during neurosurgery (Freire *et al.*, 2013). Not all foramina transmitting emissary veins are referred to as emissary foramina. The term emissary foramina mostly refer to the parietal, mastoid, condyloid and the sphenoidal foramina (Boyd, 1930).

The parietal foramina play a daily role in the maintenance of intracranial pressure during changes in the position of the head, as well as intracranial temperature regulation (Ferreira *et al.*, 2021). Berge & Bergman (2001)

¹ Department of Anatomy, School of Medicine, Faculty of Health Sciences, Sefako Makgatho Health Sciences University, Gauteng, South Africa.

² Division of Macroscopic and Clinical Anatomy, Gottfried Schatz Research Center, Medical University of Graz, Graz, Austria.

³ Fraunhofer Institute for Machine Tools and Forming Technology (IWU), Dresden, Germany.

⁴ Department of Orthopedics, Trauma and Plastic Surgery, University Hospital Leipzig, Leipzig, Germany.

state “the absence of essential anatomic data on normal variations is a severe deficiency of modern anatomy textbooks, even those apparently designed for professional use”. Other authors support this statement by reporting that anatomical variations are often neglected by clinicians and only described as “rare” or “occasional” in anatomical textbooks (Keskil *et al.*, 2003; Moore & Dalley, 2008; Freire *et al.*, 2013). Anatomical variations of foramina encountered on the cranial vault are of interest for neuro-anatomists as the presence of these foramina may have clinical implications (Freire *et al.*, 2013).

Small parietal foramina (1- to 2 mm diameter) are considered a common variant in the ossification of the parietal bones and the prevalence have been recorded in 50-80 % of individuals, dependent on the population (Boyd, 1930; Stallworthy, 1932; Robinson, 1962; Rightmire, 1972; Milne *et al.*, 1983; Reddy *et al.*, 2000; Berge & Bergman, 2001; Gracia-Miñauri *et al.*, 2003; Tubbs *et al.*, 2003; Martins *et al.*, 2005; Wysocki *et al.*, 2006; Yoshioka *et al.*, 2006; Mann *et al.*, 2009; Freire *et al.*, 2013; Liu *et al.*, 2021). Parietal foramina are symmetrical, oval-shaped blemishes located in the parietal bones and are formed due to deficient or delayed ossification (Garcia-Miñauri *et al.*, 2003). In contradiction, Freire *et al.* (2013) quote several studies stating that the parietal foramen can be circular, oval or fissure-shaped. Enlarged parietal foramina (>5 mm) are transmitted through autosomal dominant inheritance and ranges in diameter from a few millimetres to several centimeters and may be present in combination with emissary parietal foramina (Reddy *et al.*, 2000; Tubbs *et al.*, 2003). A parietal foramen can be located uni- or bilaterally in the parietal bones near the sagittal suture (Standing *et al.*, 2008).

Some studies found that parietal foramina are more prevalent in males than in females. Milne *et al.* (1983) compared Australian male and female skulls, and found that the frequency percentage with regard to the parietal foramen was 56 % and 52 % in males and females, respectively. Wysocki *et al.* (2006) suggests that sexual dimorphism in parietal ossification exists, due to the perception that the parietal foramen is twice the size in females, than in males. In 2009, a study conducted by Mann *et al.* noted that parietal foramina were present in 85 % of male and 74 % of female Japanese skulls. In a recent study performed by de Souza Ferreira *et al.* (2021) on a Brazilian sample, parietal foramina were slightly more prevalent in males (84.3 %) compared to females (84.2 %), and more commonly located bilaterally in males (54.9 %) than in females (44.73 %).

The location of the parietal foramen has been determined in relation to various bony landmarks, which

often include the lambda and sagittal suture. The parietal foramen is usually located between 3 – 3.6 mm from the lambda, regardless of the population group studied (Robinson, 1962; Standing *et al.*, 2008; Ferreira *et al.*, 2021; Liu *et al.*, 2021). The distance between the sagittal suture and the parietal foramina, however, varies greatly among population groups as published in the literature (Robinson, 1962; Yoshioka *et al.*, 2006; Ferreira *et al.*, 2021). The anatomy of the parietal foramen has not yet been studied in a South African population group.

This study aimed to evaluate the incidence, exact location and size of the parietal foramen in a South African, as well as a European, osteological sample for comparative purposes.

MATERIAL AND METHOD

After ethical clearance was obtained from the Sefako Makgatho University Research Ethics Committee (MREC/P/393/2014:IR), a combined sample total of 347 skull caps were evaluated for this study. A total of 95 skull caps of Central European origin were examined at the Institute of Anatomy, University of Leipzig, Leipzig, Germany (‘European sample’) and 252 skull caps of South African origin were examined at Sefako Makgatho Health Sciences University (‘African sample’). All available human calvaria from each department were included in this study. Calvaria were excluded if parts of the sagittal suture were invisible on the external surface, or if any markings or trauma were found on the external or internal surface of the calvaria.

Within each respective anatomy department, measurements were taken by using a standard measuring tape to ensure that no errors were made regarding the dome of the calvaria. Through observations, the presence of the parietal foramina was noted, as well as the quantity and the laterality (bilateral vs. unilateral). The exact location was determined by measuring the distance from the foramen to the coronal, lambdoid and sagittal suture, respectively. The size of the foramina was determined by measuring the diameter of each foramen, using a sliding digital caliper. Descriptive statistics such as the mean value, standard deviation, minimum and maximum were conducted on the basis of the numerical data. A Shapiro-Wilk normality tests was conducted to assess normal distribution, whereafter a paired t-test was performed to determine whether a significant difference existed between the population groups, with regard to the location and size of the parietal foramina.

RESULTS

Prevalence: Following the Shapiro-Wilk normality test, which indicated a normal distribution in the data, the paired sample t-test indicated a statistical significant difference in the prevalence of the emissary parietal foramen between the European sample (55.8 %) and the African sample (61.9 %), as seen in Table I. It was noted that parietal foramina were more commonly found unilaterally in the European sample (26.6 %) and bilaterally (42.3 %) in the African sample. Multiple foramina were observed in both population groups. There was no significant difference in the size of the parietal foramina between the observed population groups.

Location. With regard to the location of the parietal foramen, no statistically significant difference was noted between the left and right sides for both groups, or among the population groups. When present, the parietal foramen was located, on average, 91 mm from the coronal suture, 7 mm from the sagittal suture and 32-36 mm from the lambdoid suture (Fig. 1). The parietal foramen was on average located closer to the lambdoid suture in the European sample, but this was not a statistically significant difference.

DISCUSSION

The prevalence of the parietal foramen is often described as “rare” or “most commonly absent” in the literature (Keskil *et al.*, 2003; Freire *et al.*, 2013), as well as in anatomical textbooks (Moore & Dalley, 2008). In more recent publications, including this study, the prevalence of the parietal foramen is more than 50 % (de Souza Ferreira *et al.*, 2021; Liu *et al.*, 2021).

The prevalence of the parietal foramina in the European sample (56 %) corresponds well with the findings of Milne *et al.* (1983), performed on an Australian sample (52-56 %). The prevalence of the parietal foramen in our African sample group (62 %) correlates well with the range of prevalence reported by Rightmire (1972) in the Rwanda (65.5 %) and Zulu (68 %) samples groups, as well as Keskil *et al.* (2003) who reported a 63 % prevalence in a Turkish sample. It appears that the parietal foramen is more prevalent in the Indian and Japanese population group when compared to our European and African groups. The location of the parietal foramen in our sample compares well to the location noted in the Indian population as described by Murlimanju *et al.* (2015), but is completely different from the measurements published by Yoshioka *et al.* (2006) on an American sample. Different results obtained from the literature in comparison to our study, is presented in Table II.

Table I. Prevalence and size of the parietal foramen/foramina in Europeans and Africans.

	European sample (n=95)	African sample (n=252)
Absent	44.2 % (42/95)	38.1 % (96/252)
Present	55.8 % (53/95)*	61.9 % (156/252)*
Unilateral presence (total)	29.5 % (28/95)	20.2 % (51/252)
Unilateral (right only)	17.9 % (17/95)	11.5 % (29/252)
Unilateral (right with midline)	1.1 % (1/95)	1.2 % (3/252)
Unilateral (left only)	10.9 % (10/95)	6.8 % (17/252)
Unilateral (left with midline)	0 % (0/95)	0.8 % (2/252)
Bilateral presence (total)	24.2 % (23/95)	40.8 % (103/252)
Bilateral (only)	22.8 % (21/95)	40.1 % (101/252)
Bilateral (with midline)	2.1 % (2/95)	0.8 % (2/252)
Midline foramen (total)	5.3 % (5/95)	3.6 % (9/252)
Midline foramen (only)	2.1 % (2/295)	0.8 % (2/252)
Second foramen (excl midline)	2.1 % (2/95)	2.0 % (5/252)
Third foramen (excl midline)	0 % (0/95)	0.8 % (2/252)
Average size	1.9 ± 0.9 mm	1.8 ± 0.8 mm

*statistical significant difference found in the prevalence between population groups (p=0.0205)

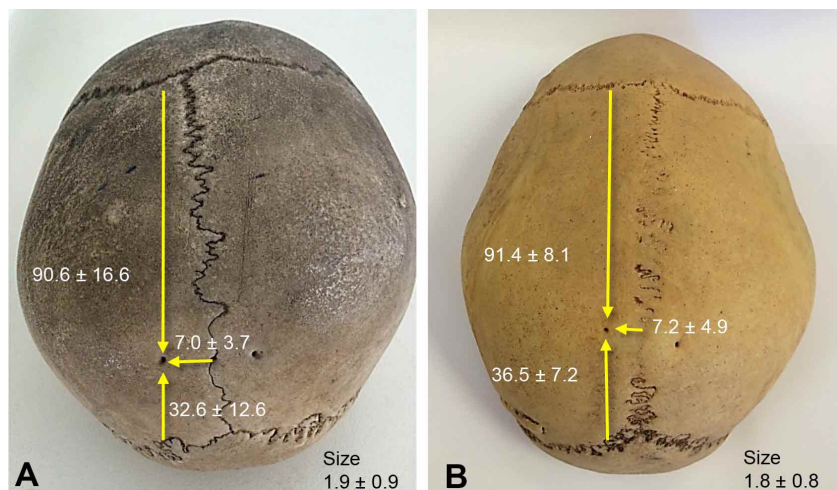


Fig. 1. Representative images showing the typical location of the parietal foramen in a. Europeans and b. Africans.

In this study, parietal foramina

Table II. Prevalence, location and size of the parietal foramina per population as recorded in the literature.

Study	Population	Prevalence (%)	Location (mm)			Size (mm)
			Foramen to lambdoid suture	Foramen to sagittal suture	Foramen to coronal suture	
Current study:	Europeans:	56	32.6 ± 12.6	7.0 ± 3.7	90.6 ± 16.6	1.9 ± 0.9
	Africans:	62	36.5 ± 7.2	7.2 ± 4.9	91.4 ± 8.1	1.8 ± 0.8
Berge & Bergman, 2001	American	80				0.7
Keskil <i>et al.</i> , 2003	Turkey	63				
Mann <i>et al.</i> , 2009	Japanese	Male: 85				
		Female: 75				
Milne <i>et al.</i> , 1983	Australian	52.2 - 56.2				
Murlimanju <i>et al.</i> , 2015	Indian	71.5		R: 6.7 ± 2.9		
				L: 6.8 ± 2.8		
Rightmire, 1972	African	54.9 – 70.6				
Wysocki <i>et al.</i> , 2006	Polish	60				2.0 ± 1.2
Yoshioka <i>et al.</i> , 2006	American	50	55 - 95	3 - 12		1.8

were more commonly seen unilaterally in the European sample (29.5 %) than in the African sample (20.2 %) and more commonly found bilaterally in the African sample (40.9 %) than in the European sample (24.2 %). When present, parietal foramina were more commonly recorded bilaterally rather than unilaterally (Stallworthy, 1932; Berge & Bergman, 2001; Yoshioka *et al.*, 2006; Mann *et al.*, 2009). Keskil *et al.* (2003) reported a unilateral presence of 31 % and a bilateral presence of the parietal foramen in 27 % of their Turkish sample, which correlates well with our findings noted in the European sample.

Interesting to note that in this study, a midline foramen in the sagittal suture was observed in both the European sample (5.3 %) and African sample (3.6 %). Of these cases, in 2/95 (2.1 %) and 2/252 (0.8 %) for the European and African samples respectively, the midline foramen appeared without an additional unilateral or bilateral accompanying

foramen. Different types of prevalence and laterality observed in this study is shown in Figure 2. The differences in the prevalence of parietal foramina could be due to racial or geographical differences as reported by Murlimanju *et al.* (2015), or due to the variations in the ossification of the anterior fonticulus as described by Freire *et al.* (2013).

Literature describes the location of parietal foramina as a unilateral or bilateral foramen in relation to the sagittal suture. It seems that significant variations exist in the position of parietal foramina with regard to the sagittal suture, however, no significant difference was noted between the European and African groups of this study. The location of the parietal foramina in our study corresponds well with the location noted by Murlimanju *et al.* (2015) in their Indian sample, however, Yoshioka *et al.* (2006) found the parietal foramina situated much closer to the sagittal suture. The position of the parietal foramen with regard to the lambdoid

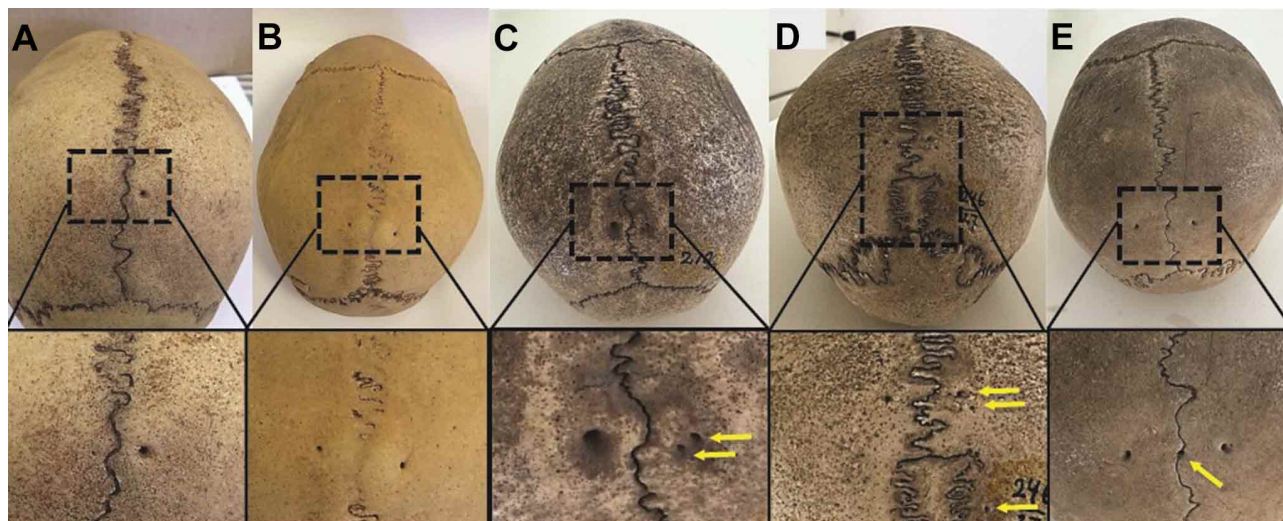


Fig. 2. Examples of the parietal foramen/foramina. A. Unilateral presence on the right, B. Bilateral presence, C. Two foramina present on the right, D. Three foramina present on the right, E. Bilateral foramina with midline foramen.

suture noted in this study, corresponds with the anatomy textbooks (Strandring *et al.*, 2008) which mentions a distance of 35 mm anterior to the lambda, as well as Robinson (1962) who noted the distance as 30 mm. Parietal foramina were again located more distant from the lambdoid suture in the American sample studied by Yoshioka *et al.* (2006).

According to literature, parietal emissary veins pass through parietal foramina connecting the superior sagittal sinus with the occipital vein. The occipital vein then joins the vertebral venous plexus. Parietal emissary veins also play a role in temperature regulation through their connections with diploic veins within the cranial (Mortazavi *et al.*, 2012). However, since the samples used in this study are all osteological specimens, the exact structure and connections may have become distorted and partially invisible, thus incomparable. Future studies should investigate the venous and arterial anastomoses between the extracranial and intracranial vessels to shed some light on the clinical implications of the presence of parietal emissary foramina.

In this study, only small parietal foramina with diameters of 1 to 2 mm were noted in both population groups, with no enlarged foramina (diameter >5 mm). European skulls displayed an average size of 1.9 ± 0.9 mm, while the African sample exhibited a somewhat smaller size of 1.8 ± 0.8 mm. This is in accordance with the Polish sample recorded by Wysocki *et al.* (2006) and the American sample reported on by Yoshioka *et al.* (2006), with average sizes of 2.0 ± 1.2 mm and 1.8 mm, respectively. The reported diameters above are however larger compared to the diameters observed in a Chinese population group (1.02 ± 0.72 mm on the left side and 1.07 ± 0.67 mm on the right side) (Liu *et al.*, 2021)

Knowledge about the location of the parietal foramen is clinically important, especially in the planning of neurosurgical procedures. Emissary veins can be ruptured during surgical procedures in the proximity of the sagittal suture which can result in spontaneous hemorrhaging.

This study is original as no data on the prevalence of the emissary parietal foramen could be found for the South African population of African ancestry. It is also the first study to report the location of the parietal foramen with regard to the coronal suture, which was on average 91 mm from the parietal foramen. This study also reports on a higher prevalence of parietal foramina than that observed from previous literature, with the European sample exhibiting a 56 % prevalence and the African sample 62 % prevalence, respectively. Anatomical variations with surgical implications are important to note in order to minimise possible complications that could occur during neurosurgical procedures.

ACKNOWLEDGEMENTS

The authors sincerely thank those who donated their bodies to science so that anatomical research could be performed. Results from such research can potentially increase mankind's overall knowledge that can then improve patient care. Therefore, these donors and their families deserve our highest gratitude. The authors would also like to thank the technical assistants at both the Sefako Makgatho Health Sciences University and the University of Leipzig for their assistance with handling the osteological specimens at these institutions. The authors acknowledge Mr Niel van Tonder and Mr Edwin de Jager for their assistance with the statistical analysis of the data, Ms Barbara Viljoen for her assistance with the language editing and Mrs Marinda Pretorius for her assistance with the preparation of the digital images.

VAN DER WALT, S.; HAMMER, N. & PRIGGE, L. Comparación entre los forámenes parietales observados en muestras de grupos de población africanos y europeos. *Int. J. Morphol.*, 41(2):634-639, 2023.

RESUMEN: Los forámenes parietales del cráneo humano actúan como una vía para las venas emisarias, conectando el seno sagital superior con las venas del cuero cabelludo. Este pasaje puede conducir a la propagación de infecciones desde el epicráneo (*calva*) hasta los senos venosos duros, pero también puede ayudar a aliviar la presión intracraneal. Sin embargo, se ha observado una variación en la prevalencia de los forámenes parietales entre los grupos de población. Este estudio observacional y descriptivo tuvo como objetivo determinar la incidencia, el tamaño y la ubicación de los forámenes parietales mediante el uso de muestras osteológicas de 252 cráneos africanos de la Universidad de Ciencias de la Salud Sefako Makgatho, Sudáfrica, y 95 cráneos europeos de la Universidad de Leipzig, Alemania. Los forámenes parietales fueron significativamente más comunes en la muestra africana (61,9 %) en comparación con la muestra europea (55,8 %). Además, la muestra centroeuropea mostró más forámenes unilaterales (29,5 %), mientras que la muestra africana mostró más forámenes bilaterales (40,8 %). El diámetro del foramen parietal promedió 1,98 mm y 1,88 mm para las muestras europeas y africanas, respectivamente. En este estudio, se observó un foramen medio en la sutura sagital en 14 de los cráneos en general (4 %). El estudio demostró que los forámenes parietales son más frecuentes de lo previsto en ambos grupos de población. Los hallazgos de este estudio, que indican una mayor prevalencia y la subsiguiente posibilidad de que se encuentren más venas emisarias, pueden ser útiles para mejorar la comprensión de las variaciones en la prevalencia y las implicaciones clínicas del foramen parietal entre varios grupos de población ubicados en el mundo.

PALABRAS CLAVE Epidemiología; Presión intracraneal; Foramen parietal; Predominio; *Calva*.

REFERENCES

- Berge, J. K. & Bergman, R. A. Variations in size and in symmetry of foramina of the human skull. *Clin. Anat.*, 14(6):406-13, 2001.
- Boyd, G. I. The emissary foramina of the cranium in man and the anthropoids. *J. Anat.*, 65(Pt. 1):108-21, 1930.
- de Souza Ferreira, M. R.; Galvão, A. P. O.; de Queiroz, P. T. M. B.; de Queiroz Lima, A. M. B.; Magalhães, C. P. & Valença, M. M. The parietal foramen anatomy: studies using dry skulls, cadaver and *in vivo* MRI. *Surg. Radiol. Anat.*, 43(7):1159-68, 2021.
- Freire, A. R.; Rossi, A. C.; De Oliviera, V. C. S.; Prado, F. B.; Caria, P. H. F. & Botacin, P. R. Emissary foramina of the human skull: Anatomical characteristics and its relations with clinical neurosurgery. *Int. J. Morphol.*, 31(1):287-92, 2013.
- Garcia-Miñauri, S.; Mavrogiannis, L. A.; Rannan-Eliya, S. V.; Hendry, M. A.; Liston, W. A.; Porteous, M. E. M. & Wilkie, A. O. M. Parietal foramina with cleidocranial dysplasia is caused by mutation in MSX2. *Eur. J. Hum. Genet.*, 11:892-5, 2003.
- Keskil, S.; Gözil, R. & Çalgüner, E. Common surgical pitfalls in the skull. *Surg. Neurol.*, 59(3):228-31, 2003.
- Liu, D.; Yang, H.; Wu, J.; Li, J. H. & Li, Y. K. Anatomical observation and significance of the parietal foramen in Chinese adults. *Folia Morphol. (Warsz.)*, 81(4):998-1004, 2021.
- Mann, R. W.; Manabe, J. & Byrd, J. E. Relationship of the parietal foramen and complexity of the human sagittal suture. *Int. J. Morphol.*, 27(2):553-64, 2009.
- Martins, C.; Yasuda, A.; Campero, A.; Ulm, A. J.; Tanriover, N. & Rhoton, A. Microsurgical anatomy of the dural arteries. *Neurosurgery*, 56(2 Suppl.):211-51, 2005.
- Milne, N.; Schmitt, L. H. & Freedman, L. Discrete trait variation in Western Australian Aboriginal skulls. *J. Hum. Evol.*, 12(2):157-68, 1983.
- Moore, K. & Dalley, A. *Clinically Oriented Anatomy*. 5th ed. Baltimore, 2008 Lippincott Williams and Wilkins.
- Mortazavi, M. M.; Tubbs, R. S.; Riech, S.; Verma, K.; Shoja, M. M.; Zurada, A.; Benninger, B.; Loukas, M. & Cohen Gadol, A. A. Anatomy and pathology of the cranial emissary veins: a review with surgical implications. *Neurosurgery*, 70(5):1312-9, 2012.
- Murlimanju, B. V.; Saralaya, V. V.; Somesh, M. S.; Prabhu, L. V.; Krishnamurthy, A.; Chettiar, G. K. & Pai, M. M. Morphology and topography of the parietal emissary foramina in South Indians: an anatomical study. *Anat. Cell Biol.*, 48(4):292-8, 2015.
- Reddy, A. T.; Hedlund, G. L. & Percy, A. K. Enlarged parietal foramina: association with cerebral venous and cortical anomalies. *Neurology*, 54(5):1175-8, 2000.
- Rightmire, G. P. Cranial measurements and discrete traits compared in distance studies of African Negro skulls. *Hum. Biol.*, 44(2):263-76, 1972.
- Robinson, R. G. Congenital perforations of the skull in relation to the parietal bone. *J. Neurosurg.*, 19(2):153-8, 1962.
- Stallworthy, J. A. A case of enlarged parietal foramina associated with metropism and irregular synostosis of the coronal suture. *J. Anat.*, 67(Pt. 1):168-74, 1932.
- Standring, S.; Borley, N. R.; Collins, P.; Crossman, A. R.; Gatzoulis, M. A.; Healy, J. C.; Johnson, D.; Mahadevan, V.; Newell, R. L. M. & Wigley, C. B. *Gray's Anatomy*. 40th ed. Baltimore, Elsevier, Churchill Livingstone, 2008.
- Tubbs, R. S.; Smyth, M. D. & Oakes, W. J. Parietal foramina are not synonymous with giant parietal foramina. *Pediatr. Neurosurg.*, 39(4):216-7, 2003.
- Wysocki, J.; Reymond, J.; Skarzynski, H. & Wróbel, B. The size of selected human skull foramina in relation to skull capacity. *Folia Morphol. (Warsz.)*, 65(4):301-8, 2006.
- Yoshioka, N.; Rhoton Jr., A. L. & Abe, H. Scalp to meningeal artery anastomosis in the parietal foramen. *Neurosurgery*, 58(1 Suppl.):ONS123-6, 2006.

Corresponding author:
Soné van der Walt
Department of Anatomy
School of Medicine
Sefako Makgatho Health Sciences University
PO Box 232
Medunsa, 0204
SOUTH AFRICA

E-mail: Sone.vanderwalt@smu.ac.za