

Distribution of Various Volumes of Methylene Blue Injection in Suprainguinal Fascia Iliaca Block Under Ultrasound Guidance: A Cadaveric Study

Distribución de Varios Volúmenes de Inyección de Azul de Metileno en el Bloque Suprainguinal de la Fascia Iliaca Bajo Guía por Ultrasonido: Un Estudio Cadavérico

Perada Kantakam^{1,2}; Naraporn Maikong^{1,2}; Prangmalee Leurcharusmee³; Apichat Sinthubua^{2,4} & Pasuk Mahakkanukrauh^{2,4}

KANTAKAM, P.; MAIKONG, N.; LEURCHARUSMEE, P.; SINTHUBUA, A. & MAHAKKANUKRAUH, P. Distribution of various volumes of methylene blue injection in suprainguinal fascia iliaca block under ultrasound guidance: A cadaveric study. *Int. J. Morphol.*, 40(3):678-682, 2022.

SUMMARY: The local anesthetic volume for a single-shot suprainguinal fascia iliaca block (SFIB) is a key factor of a block success because the courses of the three target nerves from the lumbar plexus (LP), the lateral femoral cutaneous nerve (LFCN), femoral nerve (FN), and obturator nerve (ON), at the inguinal area are isolated and within striking distance. Thus, this cadaveric study aims to demonstrate the distribution of dye staining on the LFCN, FN, ON, and LP following the ultrasound-guided SFIB using 15-50 ml of methylene blue. A total of 40 USG-SFIBs were performed on 20 fresh adult cadavers using 15, 20, 25, 30, 35, 40, 45, and 50 ml of methylene blue. After the injections, the pelvic and inguinal regions were dissected to directly visualize the dye stained on the LFCN, FN, ON, and LP. All FN and LFCN were stained heavily when the 15-50 ml of dye was injected. Higher volumes of dye (40-50 ml) spread more medially and stained on the ON and LP in 60 % of cases. To increase the possibility of dye spreading to all three target nerves and LP of the SFIB, a high volume (≥ 40 ml) of anesthetic is recommended. If only a blockade of the FN and LFCN is required, a low volume (15-25 ml) of anesthetic is sufficient.

KEY WORDS: Ultrasonography; Fascia iliaca block; Anesthetic volume; Cadaveric study.

INTRODUCTION

Ultrasound-guided suprainguinal fascia iliaca block (USG-SFIB) was first described by Hebbard *et al.* (2011). The SFIB is an analgesic technique for hip and knee surgery, such as hip/femur fracture surgery and hip/knee arthroplasty (Hadzic, 2017). A single injection of the SFIB aims to block the three nerves of the lumbar plexus (LP) that innervate the lower limb. Moreover, the USG-SFIB is an anterior approach to the lumbar plexus block (Vermeulen *et al.*, 2019). The LP is formed from the ventral rami of L1-L4. The ventral rami are the origin of the three nerves within the psoas muscle (PM). The first nerve is the lateral femoral cutaneous nerve (LFCN). It arises from the L2-L3 nerve roots and locates lateral to the PM and the anterior superior iliac spine (ASIS).

It is a sensory nerve that supplies the anterior and lateral aspects of the thigh. The LFCN travels underneath the inguinal ligament towards the sartorius muscle (Rigoard, 2017; Desmet *et al.*, 2019). The second nerve is the femoral nerve (FN). It originates from the L2, L3, and L4 nerve roots and provides sensory and motor innervation. The sensory branches supply the anterior aspect of the thigh and the anterior as well as the medial aspects of the knee. The motor branches supply a group of muscles in the anterior part of the thigh. The FN locates lateral to the femoral artery and deep to the fascia iliaca (Moore *et al.*, 2010; Rigoard, 2017). The third nerve is the obturator nerve (ON). It arises from the L2, L3, and L4 nerve roots and travels along the medial

¹ Program in Anatomy, Department of Anatomy, Faculty of Medicine, Chiang Mai University, Chiang Mai, 50200, Thailand.

² Department of Anatomy, Faculty of Medicine, Chiang Mai University, 52000, Thailand.

³ Department of Anesthesiology, Faculty of Medicine, Chiang Mai University, 52000, Thailand.

⁴ Excellence in Osteology Research and Training Center (ORTC), Chiang Mai University, Chiang Mai, Thailand.

Funding. The research leading to these results received funding from the Faculty of Medicine, Chiang Mai University under Grant Agreement No.54-2564

Received: 2021-11-19 Accepted: 2022-03-06

margin of the psoas major muscle and across the obturator foramen. It innervates the adductor muscles and supplies the skin at the medial part of the thigh (Rigoard, 2017). Currently, the USG-SFIB is commonly performed by anesthesiologists and emergency physicians. From 2011 to 2020, the volume of a local anesthetic to achieve the successful USG-SFIB varies among the literature. Vermeulen *et al.* (2018) suggested the effective volume of the USG-SFIB was 40 ml. The three target nerves were blocked. While Hebbard *et al.* (2011), Bullock *et al.* (2017) and Eastburn *et al.* (2017) identified the success of the USG-SFIB by using 20, 30, and 40 ml of injectate. The result showed that the sensory loss and the spreading of dye covered only the LFCN and FN. However, with a 40 ml of local anesthetic, Desmet *et al.* (2017) reported the analgesic efficacy of the USG-SFIB by a reduction of pain scores and morphine requirement after total hip arthroplasty. Recently, Gasanova *et al.* (2019) and Glomset *et al.* (2020) used 50-60 ml of local anesthetic for the USG-SFIB. Accordingly, the volume of local anesthetic for the USG-SFIB ranges from 20-60 ml. As mentioned above, they use the methylene blue that takes the place of the anesthetic in the injection protocol for the anesthesia (Bullock *et al.*, 2017; Vermeulen *et al.*, 2018). Thus, this study aims to demonstrate the distribution of dye staining on the LFCN, FN, ON, and LP following the USG-SFIB using 15-50 ml of methylene blue.

MATERIAL AND METHOD

A total of 20 fresh adult cadavers, donated to the Department of Anatomy, Faculty of Medicine, Chiang Mai University, Thailand, were included in the study from April to June 2020. The study protocol was approved by the Research Ethics Committee, Faculty of Medicine, Chiang Mai University, Thailand. (Research ID: ANA-2563-07179) The cadavers with previous surgery or pathology at the abdomen, hip, and inguinal regions were excluded.

Block Performance. An experienced regional anesthesiologist performed the USG-SFIB using a 6-13 MHz linear US probe (LOGIQ F8, GE Healthcare, Wisconsin, USA). Each cadaver was placed in a supine position. The US probe was firstly positioned in the sagittal plane on the junction between the lateral 1/3 and middle 1/3 of the imaginary line of the inguinal ligament. Then, the probe was moved medially to identify the sartorius, iliopsoas, and internal abdominal oblique muscles. These muscles form a "bow-tie-sign" (Desmet *et al.*, 2017). Using an in-plane approach, a blunt-tip needle (Stimuplex® A100, B Braun Medical AG, Melsungen, Germany) was

inserted in the caudal to cephalad direction. A 15-50 ml of 0.1 % methylene blue was injected when the tip of the needle was located underneath the fascia iliaca as shown in Figure 1.

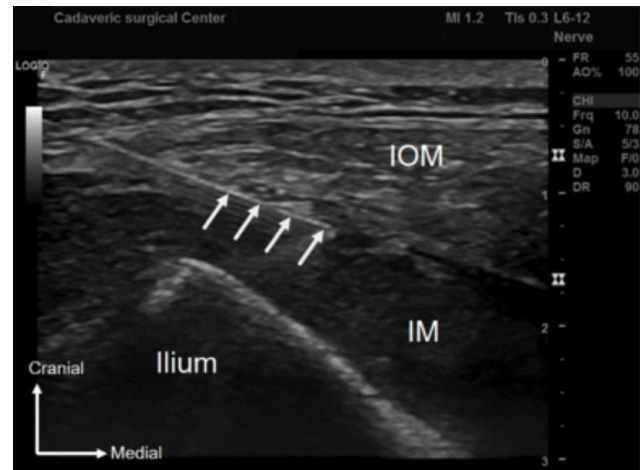


Fig. 1. Ultrasound image of the suprainguinal fascia iliaca block. IOM: internal abdominal oblique muscle, IM: iliacus muscle, and white arrows: a needle underneath the fascia iliaca

Cadaveric Dissection. One hour after bilateral SFIBs, all fresh cadavers were dissected using the same technique. The skin was incised along the costal margin, midaxillary line, and inguinal ligament from the xiphoid process to the pubic tubercle on both sides. The abdominal wall, visceral organs including stomach, intestines, and omentum, and the peritoneum of the posterior abdominal wall were removed. Carefully retract the psoas major muscle. Then, the fascia iliaca layer was dissected to identify the LFCN, FN, ON, and LP. Dye staining on the target nerves is demonstrated in Figure 2.

RESULTS

A mean age among the twenty cadavers was 71 ± 13.23 years old. Eight different volume of dye between 15-50 ml was injected in a total of 40 lower limbs (5 USG-SFIBs for each dye volume). Twenty USG-SFIBs were performed on the left side and the rest were done on the right side. The result showed that the staining of low volume (15- 25 ml) of dye is sufficient for blocking two nerves (LFCN and FN). The volume of dye that used 30-35 ml of dye spreading covered the LFCN (100 %), FN (100 %). Furthermore, the minimum volume of dye that covers the ON was 30 ml (20 %) and 35 ml (40 %). A higher dye volume (40-50 ml) was stained on the LFCN (100 %), FN (100 %), ON (60 %), and LP (60 %) of the cases (Table I).

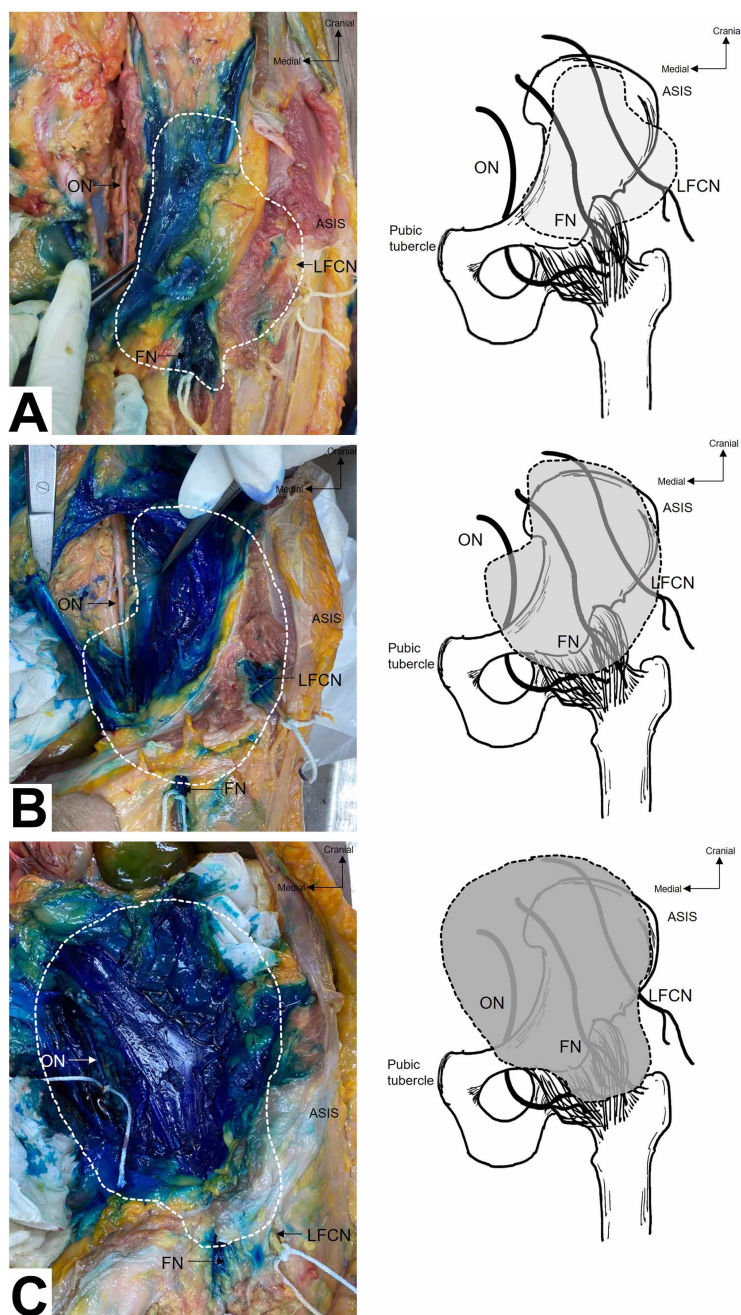


Fig. 2. Distribution of methylene blue on the three nerve target from the LP for USG-SFIB such as lateral femoral cutaneous nerve (LFCN), femoral nerve (FN), and obturator nerve (ON), a : 20 ml stained LFCN and FN, b : 40 ml stained LFCN, FN, and ON (fade), c : 50 ml stained LFCN, FN, and ON (deep).

DISCUSSION

This study investigated the distribution of dye staining on the LFCN, FN, ON, and LP following the USG-SFIB using 15-50 ml of dye. The result showed that only the LFCN and FN were dyed when 15-25 ml of methylene blue was injected. The volume of dye that could stain all the three nerves (i.e., successful block) was 30-50 ml. The percentages of the successful block with 30, 35, 40-50 ml of dye were 20 %, 40 %, and 60 %, respectively. The LP was stained by the volume (40-50 ml, 60 %) of dye (Table I). These findings are potentially applied to a local anesthetic volume selection during the USG-SFIB in the clinical setting.

The nerves innervating the hip joint that is related to the USG-SFIB are the LFCN, FN, and ON (Vermeylen *et al.*, 2019). Our study showed that the volume of dye ranging from 15 to 50 ml reliably stained the LFCN and FN. Only a higher volume (≥ 30 ml) possibly dyed the ON. These results are consistent with previous cadaveric and clinical reports. Yamada *et al.* (2020) demonstrated that the 50 % and 95 % effective volume of 0.25 % ropivacaine for the USG-SFIB was 15 and 27 ml. The definition of a successful block in that study was a loss of sensation of the LFCN and FN sensory distribution. In addition, Ueshima & Otake (2018) found that the LFCN and FN were successfully blocked when 20 ml of levobupivacaine was used for USG-SFIB in a cardiovascular-compromised patient undergoing femoral neck fracture surgery. Following the USG-SFIB with 30 ml of methylene blue, Bullock *et al.* (2017) and Vermeylen *et al.* (2018) reported that this volume was stained only on the LFCN and FN in a cadaveric study. With 40 ml of local anesthetic, a volume commonly used in the clinical setting, the SFIB effectively anesthetized the LFCN, FN, ON, and LP (Vermeylen *et al.*, 2019; Bravo *et al.*, 2020;

Table I. Number (%) of the nerves stained with dye following the suprainguinal fascia iliaca block using 15-50 ml of methylene blue.

NERVE, N (%)	VOLUME OF DYE INJECTION (ML)							
	15 ml	20 ml	25 ml	30 ml	35 ml	40 ml	45 ml	50 ml
LFCN	5 (100)	5 (100)	5 (100)	5 (100)	5 (100)	5 (100)	5 (100)	5 (100)
FN	5 (100)	5 (100)	5 (100)	5 (100)	5 (100)	5 (100)	5 (100)	5 (100)
ON	0 (0)	0 (0)	0 (0)	1 (20)	2 (40)	3 (60)	3 (60)	3 (60)
LP	0 (0)	0 (0)	0 (0)	0 (0)	0 (0)	3 (60)	3 (60)	3 (60)

Vergari *et al.*, 2020). Our result showed the least volume of dye was 40 ml that stained to the LP. Vermeylen *et al.* (2019) reported 80 % complete sensory blockade of the medial, lateral, and anterior regions of the thigh. They found that the SFIB spread toward the LP on MRI. This volume was safe and effective for postoperative analgesia after acetabular fracture surgery (Vergari *et al.*, 2020). Moreover, Bravo *et al.* (2020) demonstrated that the SFIB and the LPB provided comparable pain control in total hip arthroplasty. The SFIB produced a longer duration of analgesia and a shorter recovery period.

Determining the success of the SFIB depends mainly on the ON block. Therefore, the anatomical course of the ON deserves discussion. The ON locates deep to the medial margin of the psoas major muscle, travels into the lesser pelvic and passes through the obturator foramen to the medial thigh (Meier & Büttner, 2015). The location of the ON is adjacent to the point of needle insertion of the SFIB. For this reason, the use of a high anesthetic volume for the SFIB is necessary to reach the ON. However, a high volume of a local anesthetic to provide effective analgesia should be used with caution. The potential complications include nausea/vomit and local anesthetic systemic toxicity (LAST). Allegri *et al.* (2016) used the maximum volume (75 ml) of anesthetic and found ten out of 14 patients exhibiting symptoms of the LAST. Thus, weighing the risk versus benefit of using a high anesthetic volume is a consideration for anesthesiologists. This concern introduces analgesic options for hip surgery. Recently, the combination of USG-SFIB with the selective obturator nerve block effectively reduced postoperative opioid consumption and pain scores after hip arthroscopy (Lee *et al.*, 2020). However, the efficacy of the added ON block to the SFIB is still controversial. Nielsen *et al.* (2019) found that the ON block did not result in pain reduction after hip arthroplasty. Another alternative is the pericapsular nerve group (PENG) block. It focuses on the articular branches to the hip joint including the accessory of the obturator nerve (AON). The AON is located between the anterior inferior iliac spine (AIIS) and ilio-pubic eminence (IPE). 20 ml of local anesthetic for the PENG block effectively lessened the pain of the hip joint (Girón-Arango *et al.*, 2018). Moreover, the benefit of the PENG block over the SFIB is motor sparing. This study has some limitations. First, besides the volume of local anesthetics, the concentration of medications and technique of blockade are taken into account in the clinical setting (Helayel *et al.*, 2006). Second, the spreading of dye in cadaver differs from living humans. Vermeylen *et al.* (2021) showed that cephalad spread of dye was affected by passive movement in living subjects. Finally, our studies focused on the common volume used in the clinical setting. Further studies

specifically demonstrating the effective volume of the USG-SFIB have to be elucidated.

In summary, to increase the possibility of dye spreading to all three target nerves and LP of the SFIB, a high volume (≥ 40 ml) of anesthetic is recommended. However, potential complications following high anesthetic volume are existing concerns. If only a blockade of the FN and LFCN is required, a low volume (15-25 ml) of anesthetic is sufficient. Further studies specifically demonstrating the effective volume of the USG-SFIB are necessary to improve the efficacy of the USG-SFIB and prevent local anesthetic-related complications.

ACKNOWLEDGMENTS

A debt of gratitude is owed to the excellence of Osteology Research and Training Center (ORTC), Chiang Mai University. A special thanks to funding from the Faculty of Medicine, Chiang Mai University under Grant Agreement No.54-2564 and Patara Rattanachet for linguistic review.

KANTAKAM, P.; MAIKONG, N.; LEURCHARUSMEE, P.; SINTHUBUA, A. & MAHAKKANUKRAUH, P. Distribución de varios volúmenes de inyección de azul de metileno en el bloque suprainguinal de la fascia ilíaca bajo guía por ultrasonido: Un estudio cadavérico. *Int. J. Morphol.*, 40(3):678-682, 2022.

RESUMEN: El volumen de anestésico local para un bloqueo de la fascia ilíaca suprainguinal (FISI) de una sola inyección es un factor clave para el éxito del bloqueo, debido a que los cursos de los tres nervios objetivo del plexo lumbar (PL), el nervio cutáneo femoral lateral (NCFL), femoral (NF) y el nervio obturador (NO), en el área inguinal están aislados y dentro de la distancia de abordaje. Por lo tanto, este estudio cadavérico tiene como objetivo demostrar la distribución de la tinción de tinte en NCFL, NF, NO y PL siguiendo el FISI guiado por ultrasonido usando 15-50 ml de azul de metileno. Se realizaron un total de 40 USG-FISI en 20 cadáveres adultos frescos utilizando 15, 20, 25, 30, 35, 40, 45 y 50 ml de azul de metileno. Después de las inyecciones, se disecaron las regiones pélvica e inguinal para visualizar directamente el tinte teñido en NCFL, NF, NO y PL. Todos los NF y NCFL se tiñeron intensamente cuando se inyectaron los 15-50 ml de colorante. Volúmenes mayores de colorante (40-50 ml) se esparcen más medialmente y tiñen el NO y la PL en el 60 % de los casos. Para aumentar la posibilidad de que el colorante se propague a los tres nervios objetivo y al PL del FISI, se recomienda un volumen elevado (≥ 40 ml) de anestésico. Si solo se requiere un bloqueo de NF y NCFL, un volumen bajo (15-25 ml) de anestésico es suficiente.

PALABRAS CLAVE: Ultrasonografía; Bloqueo de fascia ilíaca; Volumen anestésico; Estudio cadavérico.

REFERENCES

- Allegrì, M.; Bugada, D.; Grossi, P.; Manassero, A.; Pincirolì, R. L.; Zadra, N.; Fanelli, G.; Zarcone, A.; Cataldo, R.; Danelli, G.; *et al.* Italian Registry of Complications associated with Regional Anesthesia (RICALOR). An incidence analysis from a prospective clinical survey. *Minerva Anesthesiol.*, 82(4):392-402, 2016.
- Bravo, D.; Layera, S.; Aliste, J.; Jara, Á.; Fernández, D.; Barrientos, C.; Wulf, R.; Muñoz, G.; Finlayson, R. J. & Tran, D. Q. Lumbar plexus block versus suprainguinal fascia iliaca block for total hip arthroplasty: A single-blinded, randomized trial. *J. Clin. Anesth.*, 66:109907, 2020.
- Bullock, W. M.; Yalamuri, S. M.; Gregory, S. H.; Auyong, D. B. & Grant, S. A. Ultrasound-guided suprainguinal fascia iliaca technique provides benefit as an analgesic adjunct for patients undergoing total hip arthroplasty. *J. Ultrasound Med.*, 36(2):433-8, 2017.
- Desmet, M.; Balocco, A. L. & Belleghem, V. V. Fascia iliaca compartment blocks: Different techniques and review of the literature. *Best Pract. Res. Clin. Anaesthesiol.*, 33(1):57-66, 2019.
- Desmet, M.; Vermeylen, K.; Van Herreweghe, I.; Carlier, L.; Soetens, F.; Lambrecht, S.; Croes, K.; Pottel, H. & Van de Velde, M. A longitudinal supra-inguinal fascia iliaca compartment block reduces morphine consumption after total hip arthroplasty. *Reg. Anesth. Pain Med.*, 42(3):327-33, 2017.
- Eastburn, E.; Hernandez, M. A. & Boretsky, K. Technical success of the ultrasound-guided supra-inguinal fascia iliaca compartment block in older children and adolescents for hip arthroscopy. *Paediatr. Anaesth.*, 27(11):1120-4, 2017.
- Gasanova, I.; Alexander, J. C.; Estrera, K.; Wells, J.; Sunna, M.; Minhajuddin, A. & Joshi, G. P. Ultrasound-guided suprainguinal fascia iliaca compartment block versus periarticular infiltration for pain management after total hip arthroplasty: a randomized controlled trial. *Reg. Anesth. Pain Med.*, 44(2):206-11, 2019.
- Girón-Arango, L.; Peng, P. W. H.; Chin, K. J.; Brull, R. & Perlas, A. Pericapsular nerve group (PENG) block for hip fracture. *Reg. Anesth. Pain Med.*, 43(8):859-63, 2018.
- Glomset, J. L.; Kim, E.; Tokish, J. M.; Renfro, S. D.; Seckel, T. B.; Adams, K. J. & Folk, J. Reduction of postoperative hip arthroscopy pain with an ultrasound-guided fascia iliaca block: a prospective randomized controlled trial. *Am. J. Sports Med.*, 48(3):682-8, 2020.
- Hadzic, A. *Hadzic's Textbook of Regional Anesthesia and Acute Pain Management*. 2nd ed. New York, McGraw-Hill Education, 2017.
- Hebbard, P.; Ivanusic, J. & Sha, S. Ultrasound-guided supra-inguinal fascia iliaca block: a cadaveric evaluation of a novel approach. *Anaesthesia*, 66(4):300-5, 2011.
- Helayel, P. E.; Lobo, G.; Vergara, R.; Conceição, D. B. D. & Oliveira Filho, G. R. D. Effective volume of local anesthetics for fascia iliaca compartment block: a double-blind, comparative study between 0.5% ropivacaine and 0.5% bupivacaine. *Rev. Bras. Anesthesiol.*, 56(5):454-60, 2006.
- Lee, S.; Hwang, J. M.; Lee, S.; Eom, H.; Oh, C.; Chung, W.; Ko, Y. K.; Lee, W.; Hong, B. & Hwang, D. S. Implementation of the obturator nerve block into a supra-inguinal fascia iliaca compartment block based analgesia protocol for hip arthroscopy: Retrospective pre-post study. *Medicina (Kaunas)*, 56(4):150, 2020.
- Meier, G. & Büttner, J. *Atlas of Peripheral Regional Anesthesia: Anatomy and Techniques*. 3rd ed. Stuttgart, Thieme, 2015.
- Moore, K. L.; Dalley, A. F. & Agur, A. M. R. *Clinically Oriented Anatomy*. 6th ed. Philadelphia, Walters Kluwer Health/Lippincott Williams & Wilkins, 2010.
- Nielsen, N. D.; Runge, C.; Clemmesen, L.; Børglum, J.; Mikkelsen, L. R.; Larsen, J. R.; Nielsen, T. D.; Søballe, K. & Bendtsen, T. F. An obturator nerve block does not alleviate postoperative pain after total hip arthroplasty: A randomized clinical trial. *Reg. Anesth. Pain Med.*, 44(4):466-71, 2019.
- Rigoard, P. *Atlas of Anatomy of the Peripheral Nerves: The Nerves of the Limbs—Student Edition*. Cham, Springer, 2017.
- Ueshima, H. & Otake, H. Supra-inguinal fascia iliaca block under ultrasound guidance for perioperative analgesia during bipolar hip arthroplasty in a patient with severe cardiovascular compromise: A case report. *Medicine (Baltimore)*, 97(40):e12746, 2018.
- Vergari, A.; Frassanito, L.; Tamburello, E.; Nestorini, R.; Sala, F.D.; Lais, G.; Ciolli, G. & Liuzza, F. Supra-inguinal fascia iliaca compartment block for postoperative analgesia after Acetabular fracture surgery. *Injury*, 51(12):2996-8, 2020.
- Vermeylen, K.; Desmet, M.; Leunen, I.; Soetens, F.; Neyrinck, A.; Carens, D.; Caerts, B.; Seynaeve, P.; Hadzic, A. & Velde, M.V.D. Supra-inguinal injection for fascia iliaca compartment block results in more consistent spread towards the lumbar plexus than an infra-inguinal injection: a volunteer study. *Reg. Anesth. Pain Med.*, 2019. Doi: <https://www.doi.org/10.1136/rapm-2018-100092>
- Vermeylen, K.; Soetens, F.; Leunen, I.; Hadzic, A.; Boxtael, S. V.; Pomes, J.; Prats-Galino, A.; Velde, M. V. D.; Neyrinck, A. & Sala-Blanch, X. The effect of the volume of supra-inguinal injected solution on the spread of the injectate under the fascia iliaca: a preliminary study. *J. Anesth.*, 32(6):908-13, 2018.
- Vermeylen, K.; Van Aken, D.; Versyck, B.; Roos, J.; Bracke, P.; Leunen, I.; Mariano, E. R. & Elsharkawy, H. The effect of passive muscle mobilization on the distribution of local anesthetics after supra-inguinal fascia iliaca compartment block, a pilot case study. *J. Clin. Anesth.*, 68:110100, 2021.
- Yamada, K.; Inomata, S. & Saito, S. Minimum effective volume of ropivacaine for ultrasound-guided supra-inguinal fascia iliaca compartment block. *Sci. Rep.*, 10:21859, 2020.

Corresponding author
Prof. Pasuk Mahakkanukrauh, MD
Department of Anatomy
Excellence in Osteology Research and Training Center (ORTC)
Faculty of Medicine
Chiang Mai University
Chiang Mai, 50200
THAILAND

E-mail: pasuk034@gmail.com