

# The Pterygopalatine Ganglion, Palatine Nerves and Vessels: Dissection and Pathway

El Ganglio Pterigopalatino, Nervios Palatinos y Vasos: Disección y Trayecto

Florin Lupu<sup>1</sup>; Catalina Iliuta<sup>1</sup>; Mihaly Enyedi<sup>2</sup>; Cosmin Pantu<sup>2</sup>;  
Razvan Stanciulescu<sup>2</sup>; Octavian Enciu<sup>3</sup> & Florin Filipoiu<sup>2</sup>

---

LUPU, F.; ILIUTA, C.; ENYEDI, M.; PANTU, C.; STANCIULESCU, R.; ENCIU, O. & FILIPOIU, F. The pterygopalatine ganglion, palatine nerves and vessels: Dissection and pathway. *Int. J. Morphol.*, 40(3):601-607, 2022.

**SUMMARY:** Background and Objectives: The palatine nerves and vessels cross the pterygopalatine fossa, the palatine canals, the palatine foramina and the submucosal space, at the level of the hard palate and the palatine recess of the maxillary sinus. Their trajectory is long, complicated and difficult to highlight on a single dissection piece. In the literature that we studied, we did not find clear images that fully highlight the real configuration of the pterygopalatine ganglion and nerves and of the palatine vessels. Our aim was to provide a clear and representative dissection of the pterygopalatine ganglion and of the palatine neurovascular bundle throughout its pathway in a simple, coherent and useful presentation for the practitioners interested in the regional pathology. We resected the posterior and inferomedial osseous walls of the maxillary sinus and highlighted the neurovascular structures in the pterygopalatine fossa and the wall of the maxillary sinus. We photographed the dissection fields and detailed the important relations. The images that we obtained are clear, simple and easy to interpret and use. We successfully highlighted the aspect and the main relations of the pterygopalatine ganglion and the pathway and distribution of the palatine nerves and vessels, from their origin to the terminal plexuses. There is a broad spectrum of clinical procedures or situations that require a proper knowledge and understanding of the anatomical pathway and relations of the palatine neurovascular elements. This includes the various types of regional anesthesia, tumor resection surgery, flaps of the palatine mucosa, the LeFort osteotomy etc. Demonstration of the pterygopalatine ganglion and its relations is useful in endoscopic interventions at the level of the pterygopalatine fossa.

**KEY WORDS:** Palatine nerves; Palatine arteries; Pterygopalatine ganglion; Maxillary sinus.

---

## INTRODUCTION

The palatine nerves and vessels originate in the pterygopalatine fossa. They first cross the palatine canals, then enter the palatine foramina and then cross the submucosal space from the level of the hard palate towards the terminal neurovascular plexuses. This submucosal space is separated from the palatine recess of the maxillary sinus by an osseous lamina, represented by the palatine process of the maxilla.

We first aimed to perform the dissection of the palatine neurovascular bundle in each topographical region. Another goal was to provide an overview of the route of the nerves and palatine vessels on a single dissection image. Last but not least, we wished to highlight the pterygopalatine ganglion and its main neurovascular relations.

## MATERIALS AND METHOD

We performed dissections on seven male cadavers in the laboratory of the Anatomy Department at «Carol Davila» University, Bucharest. The bodies were previously preserved by arterial injection with formalin (9 % concentration) and then kept in a formalin (9 % concentration) bath for two months. The anatomization of the corpses was done according to the national legislation and university regulations. The dissection pieces were photographed and the images were edited without modifying the scientific content. The dissection technique that we used consists in the resection of the bone structures around the neurovascular packages, and the preservation of anatomical landmarks necessary for a good regional orientation. The anterior, lateral and posterior walls of the left maxillary sinus were resected. The resulting images are all in an anterolateral view of the left maxillary sinus.

<sup>1</sup> Doctoral School, „Carol Davila” University of Medicine and Pharmacy, Str. Dionisie Lupu, No. 37, Sector 2, Bucharest, Romania.

<sup>2</sup> Department of Anatomy, Faculty of Medicine, Carol Davila” University of Medicine and Pharmacy, Bucharest, Romania.

<sup>3</sup> Department of Surgery, Faculty of Medicine, «Carol Davila» University of Medicine and Pharmacy, Bucharest, Romania.

## RESULTS

We will present the stages of the dissection process, in relation to the images that we obtained.

In Figure 1, after the resection of the anterolateral wall of the left maxillary sinus, we easily identified the inner antral aspect, at the level of the posterior, medial and inferior walls of the maxillary sinus. The sinus mucosa has been removed. Because the posterior and medial osseous walls are very thin, via transillumination, the palatine vessels can be observed on the maxillary tuberosity and especially at the boundary between the nasal and the palatine walls.

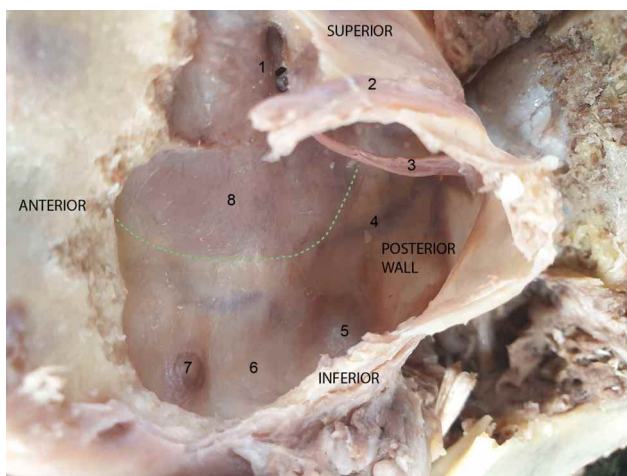


Fig. 1. The pathway of the palatine vessels at the level of the posterior, inferior and medial walls of the left maxillary sinus – anterolateral view, after the resection of the anterior and lateral walls of the maxillary sinus. Legend: 1. The sinusal aspect of the semilunar hiatus – the hiatal ostium of the maxillary sinus; 2. The infraorbital nerve, at the level of the orbital wall (roof) of the maxillary sinus; 3. Intrasinus fibrous band; 4. The palatine vessels, as seen via transillumination, on the maxillary tuberosity. Their pathway can be followed inside the medial wall of the sinus; 5. The prominence of the molar root inside the alveolar recess; 6. The palatine recess on the floor of the maxillary sinus; 7. Cyst inside the palatine recess of the maxillary sinus; 8. The lateral wall of the nasal cavity, corresponding to the medial wall of the maxillary sinus (superior to the green dotted line).

We emphasize the color difference between the nasal and the palatine walls. To ease the orientation, one can easily observe the orifice of the maxillary sinus and the protrusion of the molar root (Whyte & Boeddinghaus, 2019) in the alveolar sinus recess, as well as the existence of a cyst in the palatine recess of the maxillary sinus. On the sinus ceiling, the infraorbital nerve can be observed.

In Figure 2, by thorough dissection, the palatine process of the maxilla was resected (corresponding to the palatine recess of the maxillary sinus – a term unrecognized in the *Nomina Anatomica* (Omami *et al.*, 2013; Standing, 2016) up to the limit of the nasal wall. Thus, we highlighted the content of the submucosal space at the level of the hard palate, through which the palatine neurovascular bundle passes. The arteries and the nerves are directed mainly towards the gingival region. From the maxillary bone, we preserved, as landmark, the alveolar recess of the maxillary sinus.

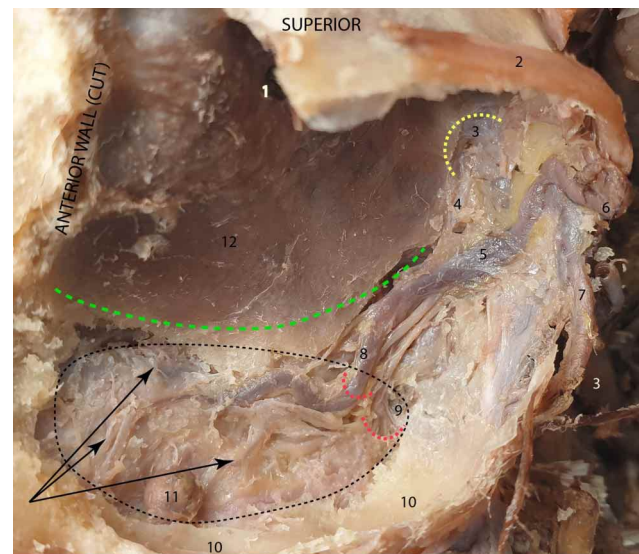


Fig. 2. The pathway of the palatine neurovascular bundle after the resection of the maxillary tuberosity and of the palatine process of the maxilla – anterolateral view, after the resection of the anterior, lateral and posterior walls of the left maxillary sinus. Legend: 1. The hiatal ostium of the maxillary sinus; 2. The infraorbital nerve, at the level of the orbital wall of the maxillary sinus; 3. The maxillary artery; 4. The common bundle of the palatine nerves; 5. The descending palatine artery; 6. The infraorbital artery; 7. The posterior superior alveolar artery; 8. The greater palatine artery; 9. Arterial branch originating in the greater palatine artery, that passes through the lesser palatine foramen, along with the lesser palatine nerve; 10. The alveolar recess of the maxillary sinus; 11. Cyst inside the palatine recess of the maxillary sinus; 12. The lateral wall of the nasal cavity, corresponding to the medial wall of the maxillary sinus (superior to the green dotted line). The yellow dotted line encircles the sphenopalatine foramen. The red dotted lines show the position of the greater (superior) and the lesser (inferior) palatine foramina. The black dotted line shows the limit of the palatine recess of the maxillary sinus. The black arrows point towards the palatine vessels situated on the palatine mucosa, at the level of the palatine recess of the sinus.

After the resection of the maxillary tuberosity, we gained access to the contents of the pterygopalatine fossa. The descending palatine, posterior-superior alveolar and

infraorbital arteries are surrounded by a mass of adipose tissue and have a direct relation to the maxillary bone.

The maxillary artery, from its entrance into the pterygopalatine fossa to the sphenopalatine foramen, has a transverse and sinuous trajectory. It passes inferior to the maxillary nerve, that crosses it almost perpendicularly. Afterwards, the maxillary nerve is continued by the infraorbital nerve. The maxillary artery and its branches occupy the anterior plane of the fossa. In its last segment, the maxillary artery has a slightly ascending path, anterior to the pterygopalatine ganglion, to which it is closely related.

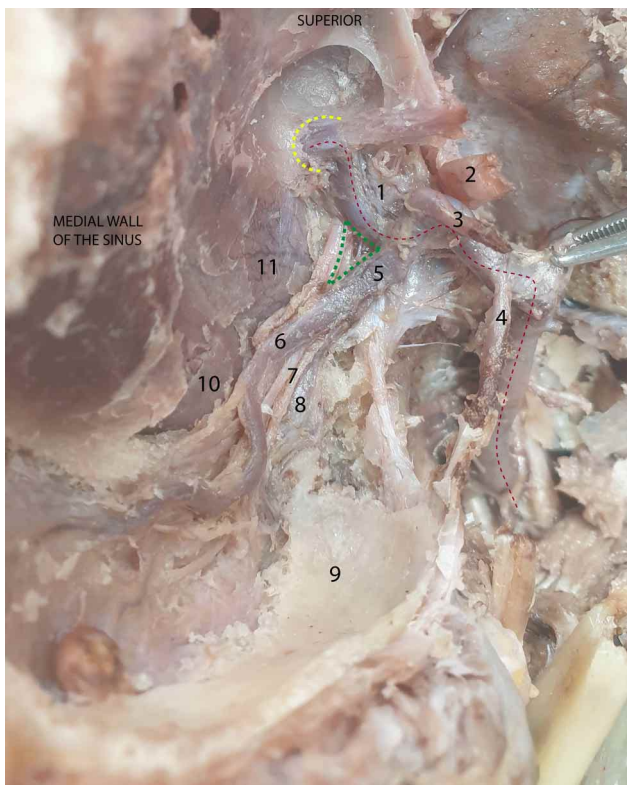


Fig. 3. The maxillary artery branches and relations in the pterygopalatine fossa – anterolateral view, after the resection of the anterior, lateral and posterior walls of the left maxillary sinus. For a better regional orientation, the main landmarks are the medial wall of the maxillary sinus and the alveolar recess of the maxillary sinus. Legend: 1. The pterygopalatine ganglion; 2. The infraorbital nerve, which continues the maxillary nerve; 3. The infraorbital artery; 4. The posterior superior alveolar artery; 5. The descending palatine artery; 6. The greater palatine artery; 7. The palatine nerves; 8. The lesser palatine artery; 9. The alveolar recess of the maxillary sinus; 10. The mucosa of the inferior nasal meatus; 11. The mucosa of the middle nasal meatus, after the removal of the osseous wall. The yellow dotted line encircles the sphenopalatine foramen. The red dotted line shows the maxillary artery. The green triangle is bordered medially by the common bundle of the palatine nerves, laterally by the descending palatine artery and superiorly by the maxillary artery.

We note that the anterior face of the pterygoid process is covered by a thin aponeurosis. From medial to lateral, the descending palatine, the infraorbital and the posterior-superior alveolar arteries emerge from the maxillary artery (Pearson *et al.*, 1969). Finally, the maxillary artery enters the nasal cavity through the sphenopalatine foramen (Lee *et al.*, 2002), together with branches of the pterygopalatine ganglion.

In Figure 4, one can see that the maxillary artery, which has a sinuous pathway, is located in the anterior plane of the pterygopalatine fossa, in close relation to the maxillary tuberosity. The artery passes inferior to the maxillary nerve and, immediately before entering the sphenopalatine foramen, it passes anterior to the pterygopalatine ganglion. Of the branches of the maxillary artery, we only kept the

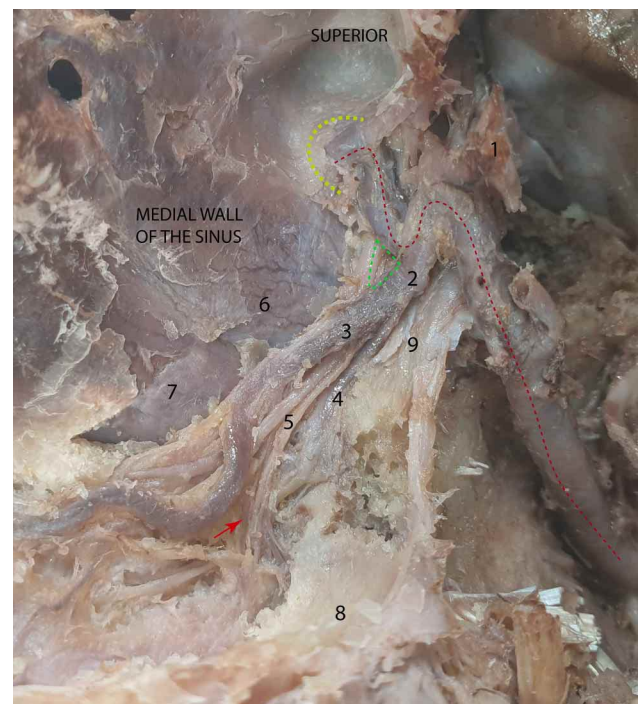


Fig. 4. The terminal segment of the maxillary artery and the descending palatine artery – anterolateral view, after the resection of the anterior, lateral and posterior walls of the left maxillary sinus. Legend: 1. The infraorbital nerve, which continues the maxillary nerve; 2. The descending palatine artery; 3. The greater palatine artery; 4. The lesser palatine artery; 5. The palatine nerves; 6. The mucosa of the middle nasal meatus; 7. The mucosa of the inferior nasal meatus; 8. The alveolar recess of the maxillary sinus; 9. The aponeurosis on the anterior aspect of the pterygoid process. The yellow dotted line encircles the sphenopalatine foramen. The red dotted line shows the maxillary artery. The green triangle is bordered medially by the common bundle of the palatine nerves, laterally by the descending palatine artery and superiorly by the maxillary artery. The red arrow points to a branch of the greater palatine artery that passes through the lesser palatine foramen, along with the lesser palatine nerve.

descending palatine artery in the foreground. It descends together with the palatine nerves into the narrow space between the maxillary tuberosity and the pterygoid process, and then its branches enter the palatine canals.

At the origin of the descending palatine artery, a triangle is formed between the artery (located laterally), the palatine nerve bundle (located medially), and the maxillary artery (located superiorly). This triangle can be an excellent landmark for the endoscopic identification of the formations in the pterygopalatine fossa.

About 1 cm after its emergence, the descending palatine artery divides into an anterior branch, the greater palatine artery, and a posterior one, the lesser palatine artery. These branches pass, along with the palatine nerves, through the palatine foramina, and arrive into the submucosal space of the hard palate. A special attention should be paid to the tight relation between the initial segment of the palatine neurovascular bundle and the middle and superior nasal meatuses – clearly visible in Figure 4, after the resection of the lateral nasal bony wall (Mellema & Tami, 2004). The greater palatine artery gives off branches that pass, together with the lesser palatine artery and the lesser palatine nerve, through the lesser palatine foramina.

In Figure 5, the pterygopalatine ganglion has the shape of an equilateral triangle (Robbins *et al.*, 2016), with the tip oriented inferiorly, a side of about 0.6 cm and the appearance of an anastomotic nervous network. It is found inferior and medial to the maxillary nerve, to which it is connected through the pterygopalatine nerves. These nerves approach the ganglion from lateral and superior. Some of the fibers of these nerves form anastomoses and synapses with the pterygopalatine ganglion, while others (sensitive fibers of the maxillary nerve, which do not form synapses in the pterygopalatine ganglion) continue on a downward trajectory and comprise the origin root of the palatine nerves. Anterior to the ganglion, and in close relation to it, passes the terminal segment of the maxillary artery, which also leaves a groove on the surface of the ganglion (Montgomery *et al.*, 1970). Posteriorly, the ganglion receives the Vidian nerve and has a close relation to the anterior surface of the pterygoid process. The medial corner of the ganglion corresponds to the sphenopalatine foramen, through which the ganglion sends the nasal nerves. The anterior part of the sphenopalatine foramen is related to the sphenopalatine artery and the posterior part to the nasal ganglionic nervous branches. The orbital nerve branches emerge from the upper side of the ganglion (Lovasova *et al.*, 2013).

The inferior corner of the pterygopalatine ganglion continues with the origin bundle of the palatine nerves. This

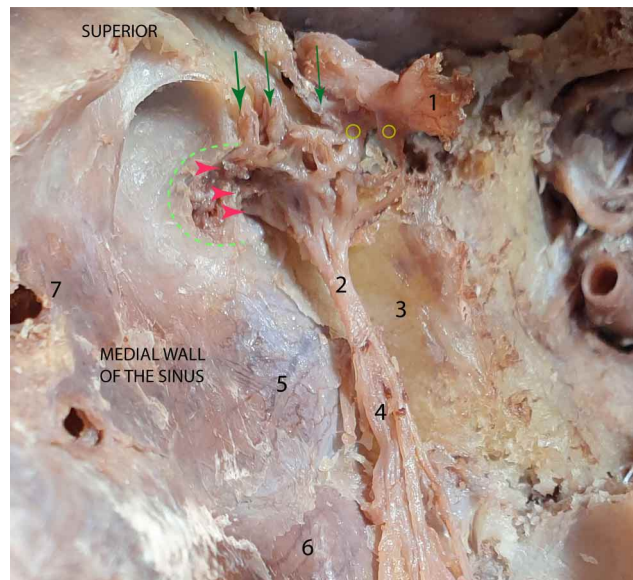


Fig. 5. Highlighting the pterygopalatine ganglion and the pathways of the palatine nerves – anterolateral view, after the resection of the anterior, lateral and posterior walls of the left maxillary sinus. The main landmarks are the anterior aspect of the pterygoid process, the sphenopalatine foramen and the medial wall of the maxillary sinus. Legend: 1. The infraorbital nerve, which continues the maxillary nerve; 2. The common bundle of the palatine nerves, originating in the inferior angle of the pterygopalatine ganglion; 3. The anterior aspect of the pterygoid process; 4. The origins of the palatine nerves; 5. The mucosa of the middle nasal meatus; 6. The mucosa of the inferior nasal meatus. The green dotted line encircles the sphenopalatine foramen. The green arrows point towards the orbital branches of the pterygopalatine ganglion. The yellow circles indicate the pterygopalatine nerves, which branch off the maxillary nerve and run towards the pterygopalatine ganglion. The red arrows point towards the nasal branches of the pterygopalatine ganglion, which enter the nasal cavity through the sphenopalatine foramen.

bundle enters the pterygomaxillary space, where it divides into branches. At the level of their origin, the greater and the intermediate palatine nerves are anastomosed and cannot be separated by dissection. The lesser palatine nerve detaches from the origin bundle.

For Figure 6, we preserved (to help orientation) two osseous landmarks: the anterior face of the pterygoid process and the alveolar recess of the maxillary sinus. One can easily recognize the middle and the lower nasal meatuses, after removing the lateral bony wall of the nasal cavity.

The pterygoid process and the tuberosity of the maxillary bone are very close in the lower part of the pterygopalatine fossa, forming a narrow space, the pterygomaxillary fissure, into which the common bundle of the palatine nerves and the pharyngeal nerve descend.

This bundle detaches from the lower corner of the pterygopalatine ganglion, has a length of about 0.5 cm, and is divided into three palatine nerves (Rouvière *et al.*, 1940). The greater and the intermediate palatine nerves enter the greater palatine canal, from which they exit at the level of the palate, through the greater palatine foramen. The lesser palatine nerve passes through the lesser palatine canal and arrives at the level of the palate through the lesser palatine foramen. The pharyngeal nerve, which is located posterior and medial to the common palatine nervous bundle, is a continuation of the pterygopalatine nerves, and descends towards the pharynx through the palatovaginal canal (Rumboldt *et al.*, 2002; Herzallah *et al.*, 2012). On the anterior surface of the pterygoid process, we must highlight the presence of a connective tissue structure with an aponeurotic aspect. From the pterygopalatine ganglion also emerge small nerve branches, that have been detached from the periarterial plexus.

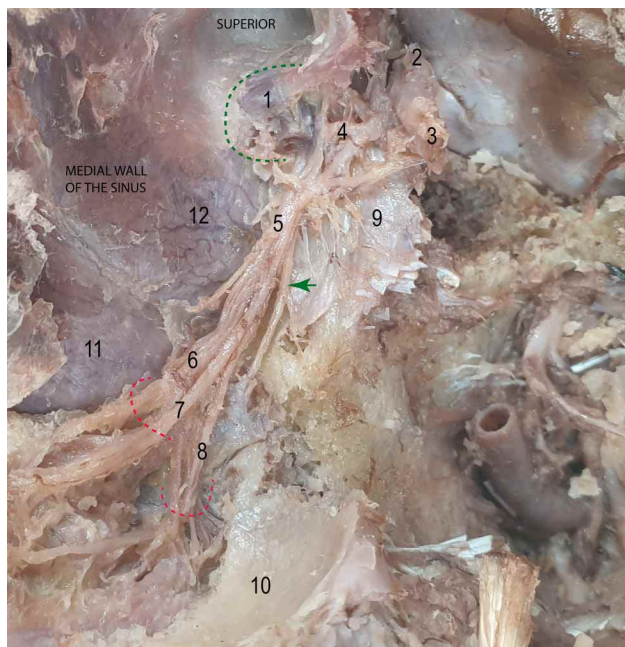


Fig. 6. The branching of the common bundle of the palatine nerves, in the pterygomaxillary space – the same orientation as in the previous figure. Legend: 1. The maxillary artery (cut) entering the sphenopalatine foramen; 2. The maxillary nerve, which gives off branches for the pterygopalatine ganglion; 3. The infraorbital nerve, which continues the maxillary nerve; 4. The pterygopalatine ganglion; 5. The common bundle of the palatine nerves; 6. The greater palatine nerve; 7. The intermediate palatine nerve; 8. The lesser palatine nerve; 9. The aponeurosis on the anterior aspect of the pterygoid process. Small ganglionic branches, that have been detached from the maxillary artery, can also be observed; 10. The alveolar recess of the maxillary sinus; 11. The mucosa of the inferior nasal meatus; 12. The mucosa of the middle nasal meatus. The green arrow points towards the pharyngeal nerve. The red dotted lines show the positions of the palatine foramina.

In Figure 7, after the resection of the palatine process of the maxilla, we demonstrated the submucosal space at the level of the hard palate, on the left side. This space corresponds to the so-called palatine recess of the maxillary sinus and is crossed by the palatine vessels and nerves (Stranding, 2016; Iwanaga *et al.*, 2019).

At the level of and around the palatine foramina, the palatine nerves are divided into a larger anterior branch and a smaller posterior branch.

In the case of the greater palatine nerve, the anterior branch passes anteriorly on the hard palate, at a level corresponding to the base of the lateral wall of the nasal cavity. In proximity to the incisive foramen, the nerve goes towards the gingival region of the lateral incisor. The posterior branch innervates the palatine mucosa anterior to the greater palatine foramen.

The intermediate palatine nerve has a similar distribution to the greater palatine nerve, but is located lateral to it. Its anterior branch heads towards the gingival region of the canine and the premolar. The posterior branch divides into branches into the mucous membrane of the palate, anterior to the greater palatine foramen.

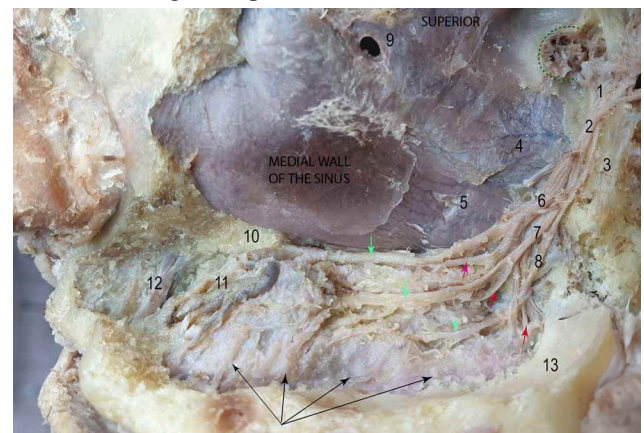


Fig. 7. The palatine nerves at the level of the submucosal space of the hard palate – anterolateral view, after the resection of the anterior, lateral and posterior walls of the left maxillary sinus. Legend: 1. The pterygopalatine ganglion; 2. The common bundle of the palatine nerves; 3. The anterior aspect of the pterygoid process; 4. The mucosa of the middle nasal meatus; 5. The mucosa of the inferior nasal meatus; 6. The greater palatine nerve; 7. The intermediate palatine nerve; 8. The lesser palatine nerve; 9. The maxillary sinus ostium; 10. The palatine process of the maxillary bone; 11. Gingival branches of the greater palatine nerve and artery; 12. The nasopalatine artery; 13. The alveolar recess of the maxillary sinus. The green dotted line encircles the sphenopalatine foramen. The green arrows point towards the anterior branches of the palatine nerves. The red arrows point towards the posterior branches of the palatine nerves. The black arrows indicate the terminal laterogingival arterial plexuses.

The anterior branch of the lesser palatine nerve passes through the submucous space, parallel to the alveolar recess, and gives lateral branches to the gingival region of the second premolar and the molars. The posterior branch heads inferiorly, along with the lesser palatine vessels, towards the soft palate.

Figure 7 depicts, in a clear and unequivocal manner, the existence of a vascular plexus situated at the level of the limit between the lateral blade of the alveolar recess and the palatine process of the maxilla (the palatine recess of the maxillary sinus). This plexus is represented by parallel gingival branches that anastomose to one another, delivering arterial blood to the gingival and alveolar regions.

## DISCUSSION

Our study does not refer to the fibrillary component of the palatine nerves, but to the macroscopic aspect, their trajectory and their relations to other structures. The usefulness of our study is given by the clarity of the description of the pathway and the relations to the other structures.

In the upper third of the pterygopalatine fossa, the palatine nerves emerge from the lower corner of the palatine ganglion. At their origin, they have the appearance of a common bundle that has an inferior trajectory into the pterygomaxillary fissure. After 0.5 cm from the origin, the three palatine nerves separate from each other. Posterior and medial to the nerve bundle and parallel to it descends the pharyngeal nerve, which heads towards the palatovaginal canal. The greater and the intermediate palatine nerves enter into the greater palatine canal, from which they emerge through the greater palatine foramen, located medial to the third molar (Hafeez *et al.*, 2015). The lesser palatine nerve reaches the palate after passing through the lesser palatine foramen (foramina), which has a variable position, as opposed to the greater one. At the level of these foramens, all the nerves divide into an anterior and a posterior branch. The branches of the palatine nerves are parallel to one another, from medial to lateral, inside the submucosal space of the palate.

The anterior branch of the greater palatine nerve has an anterior trajectory on the hard palate, in relation to the palatine process of the maxilla. Its pathway corresponds to the base of the lateral wall of the nasal cavity. It ends up in the gingival region of the lateral incisor, where it divides into terminal branches.

The anterior branch of the intermediate palatine nerve innervates the gum of the canine and of the premolar.

The anterior branch of the lesser palatine nerve innervates the gum of the second premolar and the three molars.

The posterior branches innervate the surface of the palate situated anterior to the foramina. The posterior branch of the lesser palatine nerve has a downward trajectory towards the palatine veil.

The descending palatine artery emerges from the maxillary artery, anterior to the pterygopalatine ganglion. It descends together with the common bundle of the palatine nerves into the narrow space between the maxillary tuberosity and the pterygoid process (named the pterygomaxillary fissure). A triangular area is formed at the origin of the descending palatine artery, between the artery (located laterally), the palatine nerve bundle (located medially), and the maxillary artery (located superiorly). This area represents a crucial landmark, useful for the endoscopic identification of structures located inside the pterygopalatine fossa.

After a short trajectory of about 1 cm, the descending palatine artery divides into an anterior branch, the greater palatine artery (Yu *et al.*, 2014), which descends into the greater palatine canal (Li *et al.*, 1996), and a posterior one, the lesser palatine artery, which descends into the lesser palatine canal. These branches pass, along with the palatine nerves, through the greater and the lesser palatine foramina and then enter the submucosal space of the hard palate. We must highlight the close relation between the initial segment of the palatine neurovascular bundle and the middle and upper nasal meatuses (located medial to the neurovascular bundle).

The greater palatine artery gives off branches that enter the palatine canal and pass, together with the lesser palatine artery and nerve, through the lesser palatine foramina (Mercer & MacCarthy, 1995). The greater palatine artery has an anterior trajectory, deep to the palatine nerves, and has a direct relation to the hard palate, on which it leaves multiple grooves (van den Bergh *et al.*, 2000). Most of its branches have a lateral distribution towards the gingival region, where it forms a vascular plexus. This plexus is represented by parallel gingival branches that anastomose to one another, delivering arterial blood to the gingival and alveolar regions.

## CONCLUSIONS

We managed to present, in a single dissection image, the entire course of the palatine vessels and nerves. At the same time, we have detailed their relations in each of the region they pass. There are various clinical instances in which

the anatomical approach we have performed can find its usefulness: different types of anesthesia, tumor resection surgeries, flaps of the palatine mucosa (Lovasova *et al.*, 2013; Cho *et al.*, 2013), LeFort osteotomy etc. (Li *et al.*, 1996). All these can benefit from a proper anatomical understanding and knowledge of the route of the palatine nerves and vessels.

The demonstration of the pterygopalatine ganglion and its anatomic relations facilitates endoscopic interventions at the level of the pterygopalatine fossa. Our results show that thorough dissection associated with a clear and accurate anatomical description, proper clinical utility can be found.

## ACKNOWLEDGMENTS

According to Romanian law no. 104/27.03.2003 (republished), the Departments of Anatomy of Faculties of Medicine can take over abandoned and unclaimed cadavers, for academic and scientific research purposes.

---

LUPU, F.; ILIUTA, C.; ENYEDI, M.; PANTU, C.; STANCIULESCU, R.; ENCIU, O. & FILIPOIU, F. El ganglio pterigopalatino, nervios palatinos y vasos: disección y trayecto. *Int. J. Morphol.*, 40(3):601-607, 2022.

**RESUMEN:** Los nervios y vasos palatinos atraviesan la fosa pterigopalatina, además de los canales palatinos, los forámenes palatinos y el espacio submucoso a nivel del paladar duro y el receso palatino del seno maxilar. Su trayectoria es larga, complicada y difícil de destacar en una sola pieza de disección. En la literatura que estudiamos, no encontramos imágenes claras que resalten completamente la configuración real del ganglio y los nervios pterigopalatinos y de los vasos palatinos. Nuestro objetivo fue proporcionar una disección clara y representativa del ganglio pterigopalatino y del haz neurovascular palatino a lo largo de su trayecto en una presentación simple, coherente y útil para los médicos interesados en la patología regional. Resecamos las paredes óseas posterior e inferomedial del seno maxilar y resaltamos las estructuras neurovasculares en la fosa pterigopalatina y la pared del seno maxilar. Fotografiamos los campos de disección y detallamos las relaciones importantes. Las imágenes que obtuvimos son claras, sencillas y de fácil interpretación. Resaltamos con éxito el aspecto y las principales relaciones del ganglio pterigopalatino y el trayecto y distribución de los nervios y vasos palatinos, desde su origen hasta los plexos terminales. En conclusión, existe un amplio espectro de procedimientos o situaciones clínicas que requieren un adecuado conocimiento y comprensión del trayecto anatómico y las relaciones de los elementos neurovasculares palatinos. Esto incluye los distintos tipos de anestesia regional, cirugía de resección tumoral, colgajos de mucosa palatina, osteotomía de LeFort, etc. La demostración del ganglio pterigopalatino y sus relaciones es útil en intervenciones endoscópicas a nivel de la fosa pterigopalatina.

**PALABRAS CLAVE:** Nervios palatinos; Arterias palatinas; Ganglio pterigopalatino; Seno maxilar.

## REFERENCES

- Cho, K. H.; Yu, S. K.; Lee, M. H.; Lee, D. S. & Kim, H. J. Histological assessment of the palatal mucosa and greater palatine artery with reference to subepithelial connective tissue grafting. *Anat. Cell Biol.*, 46(3):171-6, 2013.
- Hafeez, N. S.; Ganapathy, S.; Sondekoppam, R.; Johnson, M.; Merrifield, P. & Galil, K. A. Anatomical variations of the greater palatine nerve in the greater palatine canal. *J. Can. Dent. Assoc.*, 81:f14, 2015.
- Herzallah, I. R.; Amin, S.; El-Hariri, M. A. & Casiano, R. R. Endoscopic identification of the pharyngeal (palatovaginal) canal: An overlooked area. *J. Neurol. Surg. B Skull Base*, 73(5):352-7, 2012.
- Iwanaga, J.; Wilson, C.; Lachkar, S.; Tomaszewski, K. A.; Walocha, J. A. & Tubbs, R. S. Clinical anatomy of the maxillary sinus: Application to sinus floor augmentation. *Anat. Cell Biol.*, 52(1):17-24, 2019.
- Lee, H. Y.; Kim, H. U.; Kim, S. S.; Son, E. J.; Kim, J. W.; Cho, N. H.; Kim, K. S.; Lee, J. G.; Chung, I. H. & Yoon, J. H. Surgical anatomy of the sphenopalatine artery in lateral nasal wall. *Laryngoscope*, 112(10):1813-8, 2002.
- Li, K. K.; Meara, J. G. & Alexander Jr., A. Location of the descending palatine artery in relation to the Le fort I osteotomy. *J. Oral Maxillofac. Surg.*, 54(7):822-5, 1996.
- Lovasova, K.; Sulla, I. J.; Bolekova, A.; Sulla, I. & Kluchova, D. Anatomical study of the roots of cranial parasympathetic ganglia: A contribution to medical education. *Ann. Anat.*, 195(3):205-11, 2013.
- Mellema, J. W. & Tami, T. A. An endoscopic study of the greater palatine nerve. *Am. J. Rhinol.*, 18(2):99-103, 2004.
- Mercer, N. S. & MacCarthy, P. The arterial supply of the palate: Implications for closure of cleft palates. *Plast. Reconstr. Surg.*, 96(5):1038-44, 1995.
- Montgomery, W. W.; Katz, R. & Gamble, J. F. Anatomy and surgery of the pterygomaxillary fossa. *Ann. Otol. Rhinol. Laryngol.*, 79(3):606-18, 1970.
- Omami, G. Palatine recess of maxillary sinus masquerading as radiolucent lesion: case report. *Libyan Dent. J.*, 3:14815171, 2013.
- Pearson, B. W.; MacKenzie, R. G. & Goodman, W. S. The anatomical basis of transantral ligation of the maxillary artery in severe epistaxis. *Laryngoscope*, 79(5):969-84, 1969.
- Robbins, M. S.; Robertson, C. E.; Kaplan, E.; Ailani, J.; Charleston 4th, L.; Kuruvilla, D.; Blumenfeld, A.; Berliner, R.; Rosen, N. L.; Duarte, R.; *et al.* The sphenopalatine ganglion: anatomy, pathophysiology, and therapeutic targeting in headache. *Headache*, 56(2):240-58, 2016.
- Rouvière, H.; Delmas, A. & Delmas, V. *Anatomie Humaine Descriptive, Topographique Et Fonctionnelle*. Tome 1. Paris, Masson, 1940.
- Rumboldt, Z.; Castillo, M. & Smith, J. K. The palatovaginal canal: can it be identified on routine CT and MR imaging? *AJR Am. J. Roentgenol.*, 179(1):267-72, 2002.
- Standing, S. *Gray's Anatomy. The Anatomical Basis of Clinical Practice*. 41st ed. Philadelphia, Elsevier, 2016.
- van den Bergh, J. P.; ten Bruggenkate, C. M.; Disch, F. J. & Tuinzing, D. B. Anatomical aspects of sinus floor elevations. *Clin. Oral Implants Res.*, 11(3):256-65, 2000.
- Whyte, A. & Boeddinghaus, R. The maxillary sinus: Physiology, development and imaging anatomy. *Dentomaxillofacial Radiol.*, 48(8):20190205, 2019.
- Yu, S. K.; Lee, M. H.; Park, B. S.; Jeon, Y. H.; Chung, Y. Y. & Kim, H. J. Topographical relationship of the greater palatine artery and the palatal spine. Significance for periodontal surgery. *J. Clin. Periodontol.*, 41(9):908-13, 2014.

Corresponding author:  
Catalina Iliuta Doctoral School, «Carol Davila»  
University of Medicine and Pharmacy  
Str. Dionisie Lupu, no. 37  
Sector 2, Bucharest  
Zip Code 020021  
ROMANIA

E-mail: catalina.iliuta@rez.umfcd.ro