

Morphology and Morphometry of the Tendons of the Palmaris Longus and Radial Carpal Extensor Muscles in Humans

Morfología y Morfometría de los Tendones de los Músculos Palmar Largo y Extensores Radiales del Carpo en el Hombre

Aladino Cerda ^{*,**} & Mariano del Sol ^{***,****}

CERDA, A & DEL SOL, M. Morphology and morphometry of the tendons of the palmaris longus and radial carpal extensor muscles in humans. *Int. J. Morphol.*, 34(4):1515-1521, 2016.

SUMMARY: The tendons of the palmaris longus (PL) and radial carpal extensor (RCE) muscles have extensive applications in surgery, yet despite their constant use, information about their morphological and morphometric characteristics remains limited. The aim of this study was to describe the morphological and morphometric characteristics of the PL and RCE muscle tendons and compare them to each other in 30 upper limbs of adult individuals with no apparent deformations from anatomy units at four universities in Chile. The anterior side and lateral margin of the forearm and the back of the hand as far as the tendon plane were dissected. The average length, width at origin level and at the level of the radiocarpal joint line of the PL muscle tendon were 125.48 mm ± 8.93, 4.76 mm ± 1.35 and 3.76 mm ± 0.91, respectively. The average length, width at the levels of origin and insertion of the extensor carpi radialis longus muscle tendon were 180.46 mm ± 15.03, 14.69 mm ± 3.72 and 7.76 mm ± 1.44 respectively, whereas for the extensor carpi radialis brevis muscle they were 115.23 mm ± 11.81, 9.53 mm ± 2.58 and 7.33 mm ± 1.17, respectively. The most common origin of the tendons of the PL and extensor carpi radialis longus muscles was at the level of the middle third of the forearm, whereas the most common origin of the extensor carpi radialis brevis muscle tendon was at distal third level. The shape of the tendons of the PL and RCE muscles was broad and flat along their entire length. Simulating the longitudinal division of the tendons of the RCE muscles in two halves, the radial half of the tendons of both muscles has morphological and morphometric characteristics similar to the PL muscle tendon, such that it could be used as a graft in the case of agenesis of the PL muscle, or for tendon transfer where elongation of a tendon in the region is required.

KEY WORDS: Palmaris longus muscle; Extensor carpi radialis muscles; Extensor carpi radialis longus muscle; Extensor carpi radialis brevis muscle; Upper limb; Tendon transfer surgery.

INTRODUCTION

The tendons of the palmaris longus (PL) and radial carpal extensor (RCE) muscles are widely used in tendon transfer surgery. The PL muscle tendon is used particularly in esthetic and reconstructive procedures (Angelini Júnior *et al.*, 2012), whereas the RCE muscle tendons are used mainly to restore movement to the thumb (Georgiev *et al.*, 2006).

The PL muscle is fusiform, originating on the anterior side of medial epicondyle of the humerus, in a common tendon with medial epicondyle muscles, in the deep fascia of the forearm and in the fibrous septa that separate it from the surrounding muscles (Testut & Latarjet, 1975). It continues with its tendon, which is long and flat, at the middle third level of the forearm. At this level, the PL muscle tendon

is superficial at the retinaculum of the flexor muscles and is inserted in its anterior part, in the thenar eminence and in the palmar aponeurosis, with which it is continuous (Stecco *et al.*, 2009). The extensor carpi radialis longus (ECRL) is fusiform and originates in the lateral supracondylar crest of the humerus (Lippert, 2006; Moore *et al.*, 2010) and in the lateral intermuscular septum of the arm (Testut & Latarjet). In the middle third of the forearm, it continues with its tendon, wide and flat, to then be inserted on the dorsal side of the second metacarpal bone base (Moore *et al.*). The extensor carpi radialis brevis (ECRB) muscle is unipennate, originates on the posterior side of the lateral epicondyle of the humerus, along with superficial muscles of the posterior region of the forearm, in the deep fascia of the forearm, in the radial collateral ligament and fibrous septum that

* Unidad de Morfología, Departamento de Ciencias Básicas Biomédicas, Facultad de Ciencias de la Salud, Universidad de Talca, Talca, Chile.

** Programa de Magíster en Ciencias, mención Morfología, Facultad de Ciencias de la Salud, Universidad de La Frontera, Temuco, Chile.

*** Facultad de Medicina, Centro de Excelencia en Estudios Morfológicos y Quirúrgicos (CEMyQ), Universidad de La Frontera, Temuco, Chile.

**** Centro de Investigación en Ciencias Biomédicas, Universidad Autónoma de Chile, Chile

separates it from the extensor muscle of the fingers. At the level of the middle third of the forearm it continues with its tendon, wide and flat (Testut & Latarjet), which accompanies the ECRL muscle tendon until the radiocarpal joint, where both pass through the second tendinous compartment of the retinaculum of the extensor muscles (Llusá Pérez *et al.*, 2004; Lippert; Moore *et al.*). Distally, the ECRB muscle tendon is inserted on the dorsal side of the third metacarpal bone base (Moore *et al.*).

According to Angelini Júnior *et al.* and Ito *et al.* (2014), the PL muscle tendon presents a mean length of 119.9 mm and $116.6 \text{ mm} \pm 18.5$, respectively. According to Loren & Lieber (1995) and Murray *et al.* (2000), the ECRL muscle tendon has an average length of $182.1 \text{ mm} \pm 5.1$ and $248 \text{ mm} \pm 10$, respectively, whereas the ECRB muscle tendon has an average length of $102.7 \text{ mm} \pm 4.6$ (Loren & Lieber). Angelini Júnior *et al.* and Ito *et al.* determined that the mean width of the PL muscle tendon is $4.1 \text{ mm} \pm 1.5$ and $4.2 \text{ mm} \pm 0.8$, respectively. Brand (1985) reported that in the adult the ECRL muscle tendon presents a width between 14 and 17 mm.

The ample use of the PL and RCE muscles is due to their easy approach and because when transferring only one of them, they do not leave a significant deficit at the donor site. However, the PL muscle may be absent in 4.4 % (Kigera & Mukwaya, 2011) to 63.9 % of individuals (Ceyhan & Mavt, 1997), can be double (Testut, 1884; Le Double, 1897; del Sol & Vásquez, 2009), can be replaced by a fibrous fascicle (Testut; Le Double), can be totally fleshy (Le Double), can be inverted (tendinous in its proximal part and fleshy in its distal part) (Wood, 1867; Le Double), can be tendinous in its middle part and fleshy on its ends or fleshy in its middle part and tendinous on its ends (Le Double), making it difficult or impossible to transfer its tendon. In addition, on many occasions, neither the tendon of the PL muscle nor that of the RCE muscles is sufficiently long to reach the target site, making it necessary to extend it through a graft. Among the tendons available for graft material, the fascia lata is the most frequently used site due to its size and availability; the disadvantage lies in the fact that two sites must be operated on separately, which is time-consuming and leaves a scar on the thigh (Malaviya, 2003). To avoid the graft, several authors have used techniques in which the RCE muscle tendons are divided; nevertheless, there is limited data in the literature about their morphological and morphometric characteristics. Therefore, we decided to study the morphological and morphometric characteristics of the PL and RCE muscle tendons, and to compare them to each other to determine if transfer between them is possible where an elongation of the tendon is required or in the absence of the PL muscle.

MATERIAL AND METHOD

We conducted a cross-sectional descriptive study on 30 upper limbs from adult Caucasian individuals of both sexes (13 men and 2 women), fixed in formaldehyde, belonging to the Anatomy units of the Universidad de Talca, Universidad de La Frontera, Universidad Católica del Maule and Pontificia Universidad Católica de Chile.

The anterior side and lateral margin of the forearm and the back of the hand were dissected. Once the subcutaneous tissue was exposed, the fatty tissue and deep fascia were removed as far as the tendon plane of the PL and RCE muscles. The PL muscle tendon was cleared from its origin to the radiocarpal joint line and the RCE muscle tendons from their origin to their insertion.

To assess the morphological characteristics, the origin of the PL and RCE muscle tendons were identified using a magnifying glass at 4X. This origin was considered the distal portion of the myotendinous junction, i.e., the point at which there are no longer any muscle fibers associated with the tendon. The relations and shape of the PL and RCE muscle tendons were also observed, as well as the insertion of the RCE muscle tendons.

We measured the length of the forearm from the uppermost part of olecranon to the ulnar styloid process to determine the origin level of the tendons. In order to take the measurement of the length of the forearm, the reference points were marked using pins and a thread was put between them, which was later placed on a millimeter ruler. In addition, the PL muscle tendon was measured from its origin to the radiocarpal joint line and the length of the RCE muscle tendons and their radial half from their origin to their insertion.

We measured the width of the PL and RCE muscle tendons and their radial half at origin level, the width of the PL muscle tendon at the level of the radiocarpal joint line and the width of the RCE muscle tendons and their radial half at insertion level. To obtain the radial half of the RCE muscle tendons, the midpoint of their width was located in the previously indicated places, dividing these measurements in two and simulating a longitudinal separation of these tendons, thus obtaining two halves, radial and ulnar. It should be emphasized that the length of the RCE muscle tendons corresponds to the part of the tendon with no muscle fiber insertion; however, the muscle fiber insertions in the radial and ulnar parts are made at different heights. Additionally, the distance between the origin of the RCE muscle tendons and the vertex of the radial styloid process was measured.

A digital caliper to an accuracy of 0.01 mm was used to measure the PL and RCE muscle tendons.

RESULTS

Morphological characteristics of the tendons of the palmaris longus and extensor carpi radialis longus and brevis muscles

Agensis of the PL muscle was identified in 5 cases (16.7 %), all males. In 25 cases (83.3 %) the PL muscle was present and its tendon originated in the proximal part of the middle third of the forearm. The tendon of the ECRL muscle in 26 cases (86.7 %) originated in the middle part of the middle third of the forearm and in 4 cases (13.3 %) in the distal part of the proximal third of the forearm. The tendon of the ECRB muscle in 21 cases (70 %) originated in the

proximal part of the distal third one of the forearm, and in 9 cases (30 %) in the distal part of the middle third of the forearm.

The superficial side of the PL muscle tendon was covered by the forearm skin and the superficial and deep fascia, whereas its underside was related proximally to the superficial flexor muscle of the fingers and distally to the retinaculum of the flexor muscles (Fig. 1). The superficial side of the ECRL muscle tendon was covered by the forearm skin, superficial and deep fascia and partially by the brachioradialis, whereas its underside was covering the ECRB muscle fibers proximally and the ECRB muscle tendon distally (Fig. 2). In the most distal part of the forearm, the ECRL muscle tendon was located laterally to the tendon of the ECRB muscle, passing with it through the second tendinous compartment of

the retinaculum of the extensor muscles. The superficial side of the tendon of the ECRB muscle was related to the underside of the ECRL muscle tendon. The underside of the ECRB muscle tendon, from proximal to distal, was on the lateral and posterior side of the radius, respectively. The RCE muscle tendons at the distal third level of the forearm were found under the muscle fibers of the abductor pollicis longus and extensor pollicis brevis, and distally to the retinaculum of the extensor muscles under the extensor pollicis longus muscle tendon, forming part of the dorsoulnar corner of the anatomical snuffbox in 100 % of the samples in the case of the ECRL muscle tendon, and in 26.7 % (8 of 30 samples) in the case of the ECRB muscle tendon.

The PL and RCE muscle tendons were wide and flat throughout their extension. In all the samples, the ECRL and ECRB muscle tendons were inserted radially on the dorsal side at the base of the second and third metacarpal bones, respectively. (Fig. 3).

Morphometric characteristics of the tendons of the palmaris longus and extensor carpi radialis longus and brevis muscles

Table I summarizes the measurements of the length of the forearm, length of the PL muscle tendon and the length of the RCE muscle tendons and their radial half, by sex.

Table II summarizes the measurements of the width of the PL and RCE muscle tendons and their radial half at their origin level, the width of the PL muscle tendon at the level of the radiocarpal joint and the width of the RCE

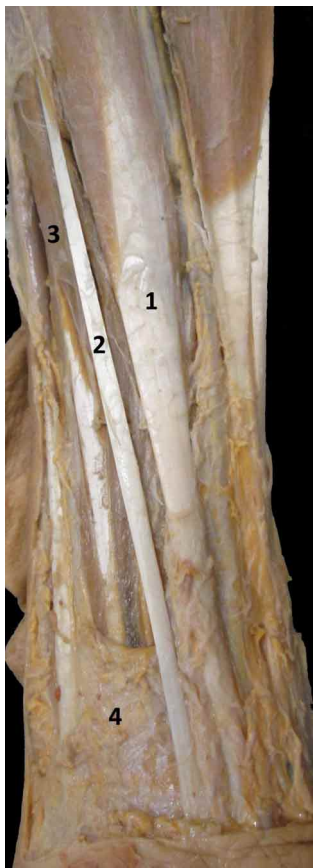

Fig 1. Anterior view of the left forearm. 1= tendon of the flexor carpi radialis muscle; 2= tendon of the palmaris longus muscle; 3= flexor digitorum superficialis muscle; 4= retinaculum of flexor muscles.




Fig 2. Posterior view of the radial margin of the right forearm. 1= extensor carpi radialis longus muscle; 2= extensor carpi radialis brevis muscle; 3= tendon of the extensor carpi radialis longus muscle; 4= tendon of the extensor carpi radialis brevis muscle; 5= abductor pollicis longus muscle.

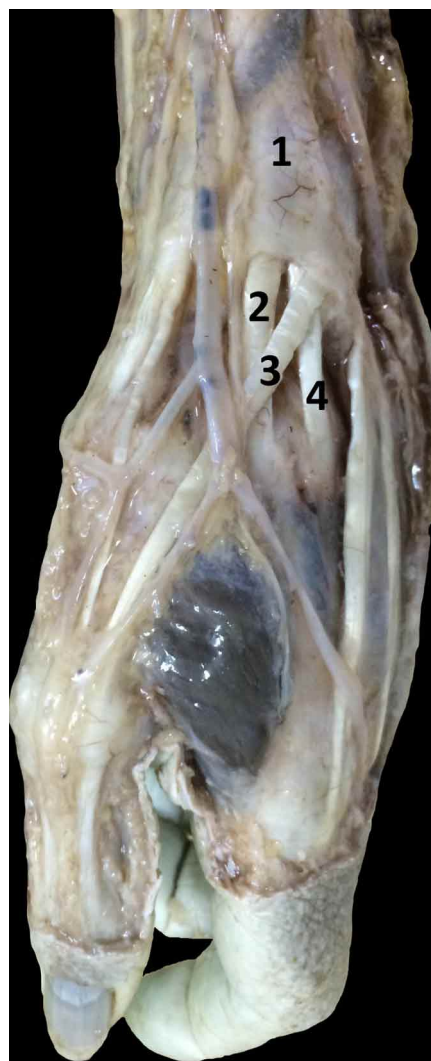


Fig 3. Posterior view of radial part of the left wrist. 1= retinaculum of the extensor muscles; 2= tendon of the extensor carpi radialis longus muscle; 3= tendon of the extensor pollicis longus muscle; 4= tendon of the extensor carpi radialis brevis muscle.

muscle tendons and their radial half at the level of their insertion, by sex.

In Table III, a comparison is made between the main morphometric characteristics of the PL muscle tendon and the radial half of the RCE muscle tendons.

The overall mean distance between the origin of the ECRL muscle tendon and the radial styloid process was 155.46 mm ± 17.13, in the males it was 155.57 mm ± 18.08 and in the females 154.69 mm ± 10.57, whereas the overall mean distance between the origin of the tendon of the ECRB muscle and the radial styloid process was 79.20 mm ± 11.26, in the males it was 78.87 mm ± 11.97 and in the females 81.36 mm ± 4.99.

No statistically significant differences were observed between sex and the side of the forearm.

Table I. Length of the forearm, length of the PL muscle tendon and the length of the RCE muscle tendons and their radial half, by sex (in mm and with radial deviation).

	Overall	Male	Female
L of forearm	253.62 ± 19.89	253.15 ± 19.91	256.64 ± 22.31
L PL	125.48 ± 8.93	124.85 ± 9.37	128.76 ± 5.9
L ECRL	180.46 ± 15.03	180.46 ± 15.63	180.47 ± 12.2
L radial half ECRL	189.07 ± 15.43	189.11 ± 15.77	188.80 ± 15.11
L ECRB	115.23 ± 11.81	115.22 ± 12.50	115.28 ± 6.9
L radial half ECRB	118.09 ± 12.13	118.27 ± 12.68	116.97 ± 8.8

L: Length.

Table II. Width of the PL muscle tendon and width of the RCE muscle tendons and their radial half at different levels, by sex (in mm and with radial deviation)

	Overall	Male	Female
WO PL	4.76 ± 1.35	4.78 ± 1.32	4.67 ± 1.70
WO ECRL	14.69 ± 3.72	15.14 ± 3.63	11.80 ± 3.38
WO radial half ECRL	7.34 ± 1.86	7.56 ± 1.81	5.90 ± 1.68
WO ECRB	9.53 ± 2.58	9.72 ± 2.67	8.35 ± 1.73
WO radial half ECRB	4.76 ± 1.29	4.85 ± 1.33	4.17 ± 0.86
WRL PL	3.76 ± 0.91	3.76 ± 0.96	3.71 ± 0.67
WT ECRL	7.76 ± 1.44	7.84 ± 1.45	7.25 ± 1.45
WT radial half ECRL	3.87 ± 0.72	3.91 ± 0.72	3.63 ± 0.72
WT ECRB	7.33 ± 1.17	7.42 ± 1.16	6.77 ± 1.25
WT radial half ECRB	3.66 ± 0.58	3.70 ± 0.57	3.38 ± 0.62

WO: Width at origin level; WLR: Width at level of radiocarpal line; WT: Width at level of tendinous insertion.

Table III. Comparison of the length, width at origin and width at the most distal part of the PL muscle tendon and radial half of the RCE muscle tendons (in mm and with standard deviation)

	PL	Radial half ECRL	Radial half ECRB
Length	125.48 ± 8.93	189.07 ± 15.43	118.09 ± 12.13
Width at origin	4.76 ± 1.35	7.34 ± 1.86	4.76 ± 1.29
Width most distal part	3.76 ± 0.91	3.87 ± 0.72	3.66 ± 0.58

* The most distal part of each tendon is considered the place at which it is divided during tendon transfer surgery. Thus, the most distal part of the PL muscle tendon corresponds to the radiocarpal joint line, whereas the most distal part of the RCE muscle tendons corresponds to their insertion.

DISCUSSION

Most anatomy texts, including the one by Testut & Latarjet; Llusá Pérez *et al.* and Standring (2008), indicate that the origin of the PL and RCE muscle tendons is found at the level of the middle third of the forearm. This is correct, as long as the origin of the tendons is taken to be its most proximal portion, which is associated with the lowest muscle fibers. However, for surgical purposes and on the basis of previous studies (Angelini Júnior *et al.* and Ito *et al.*), we consider the origin of the tendon to be the lowest part of the myotendinous junction, since the useful portion of the tendon, i.e., the part that is divided during tendon transfer surgery, begins exactly at this level.

Considering Baek's surgical technique (Baek *et al.*, 1999), in which the RCE muscle tendons are divided at the junction of the middle and distal thirds of the forearm, we agree with him that the ECRL muscle tendon is a good candidate for opponensplasty given that it is sufficiently long as to be divided longitudinally into two halves and reach the base of the thumb without needing to use a graft from another tendon. However, in the majority of our cases, the tendon of the ECRB muscle at this level still presents muscle fibers associated with it; therefore, an incision at this height would not be advisable for its extraction.

The percentage of agenesis of the PL muscle in our case was greater than that reported by Kigera & Mukwaya in corpses in Southern Africa, similar to that reported by Thompson *et al.* (2001) in Caucasian subjects in Northern Ireland (16%), lower than that reported by Alves *et al.* (2011) in Chilean adults, and lower than that reported by Ceyhan & Mavt in Indians. The differences in the incidences may be associated with the ethnic origin of the subjects.

The relations of the PL and RCE muscle tendons in all the samples were similar to those described in the anatomical texts consulted; however, the relations of the muscle fibers and those of the tendon are not described separately. This distinction is important during surgical procedures, since it makes it possible to approach the region to be treated with greater accuracy. Doyle & Botte (2003) affirmed that the dorsoulnar corner of the anatomical snuffbox contains only the tendon of the ECRL muscle, but in agreement with Tubbs *et al.* (2006), the tendon of the ECRB muscle can also be found in the anatomical snuffbox depending on how distal the retinaculum is from the extensor muscles and how medial the dorsal tubercle is from the radius. In 26.7% of our cases, the ECRB muscle tendon was found to be part of the dorsoulnar corner of the anatomical snuffbox, which is why intersection syndrome,

where symptomatic friction is created between the tendons of the RCE muscles and extensors of the thumb, can occur at that level (Doyle & Botte).

Of the anatomy texts consulted, only Testut & Latarjet described the shape of the proximal portion of the PL and RCE muscle tendons, similar to that found in our dissections; in the distal part, however, we do not agree with any of the authors. Most anatomy texts do not detail the zone of the dorsal side of the metacarpal bones, where the RCE muscle tendons are inserted. In all our samples, the ECRL muscle tendon was inserted radially on the dorsal side of the second metacarpal bone base, whereas the ECRB muscle tendon was inserted radially on the dorsal side of the third metacarpal bone base, as described by Ferreira Caetano *et al.* (2004) and Standring. The insertion of the tendon is relevant to the functioning of the muscle. The axis of the hand is in relation to the third finger, and therefore the ECRB muscle is the primary motor in the extension of the radiocarpal joint and aids in its radial deviation, whereas the ECRL muscle is an agonist both in the extension and in the radial deviation of the radiocarpal joint.

The overall mean length of the forearm and overall mean length of the PL muscle tendon are similar to that reported by Angelini Júnior *et al.* in adult corpses of African descent and to that reported by Ito *et al.* in Japanese adult corpses. Overall mean length of both the ECRL and ECRB muscle tendons is similar to that described by Loren & Lieber, and shorter than that reported by Murray *et al.* in the case of the ECRL muscle tendon. This difference can be determined by the ethnic origin of the subjects studied, although Murray *et al.* does not detail this background. We agree with Malaviya, in that the radial half of the ECRL muscle tendon is greater than the length of the tendon, since it is associated with the lowest muscle fibers of the ulnar half; the same occurs with the radial half of the ECRB muscle tendon. However, we did not find any background of authors who had quantified this measurement.

The overall mean width of the PL muscle tendon at origin level is similar to that reported by Angelini Júnior *et al.* and Ito *et al.* The overall mean width of the ECRL muscle tendon at origin level is similar to that described by Brand. We did not find any articles that indicated the width of the ECRB muscle tendon at its origin level, the width of the radial half of the RCE muscle tendons at their origin level, the width of the PL muscle tendon at the level of the radiocarpal joint line or the width of the RCE muscle tendons and their radial half at the level of their insertion. Therefore,

this study is the first to provide such a morphometric report. When the overall mean width of the tendon of both the ECRL and ECRB muscles is analyzed at both origin and insertion level, and a longitudinal division in two halves is simulated, the radial half of both presents a length and width similar to the PL muscle tendon, which is why this half can be used in the case of agenesis of the PL muscle, or for transferring between them in the case of requiring the elongation of a tendon in the region. We decided to compare the radial half of the RCE muscle tendons with the PL muscle tendon because when the ulnar half is maintained, the muscle can continue to function without affecting the mobility of the radiocarpal joint.

Chetta *et al.* (2012) used the radial half of the ECRL muscle tendon to reconstruct the tendon of the extensor pollicis longus muscle, since a graft from the inserted tendon was not possible given the absence of the PL muscle, and they obtained excellent results, comparable to those obtained using the fascia lata. They indicated that when the ECRL muscle tendon is divided, it becomes too voluminous to adjust to the size of the tendon of the extensor pollicis longus muscle, regardless of the location of the break; nevertheless, their article does not contain any morphological data on the ECRL muscle tendon nor on the tendon of the extensor pollicis longus muscle.

Malaviya used the radial half of the ECRL muscle tendon as a graft to extend the muscle-tendon unit of the same ECRL and thus to correct claw fingers. This author indicated that the ECRL muscle tendon in the adult is sufficiently wide to be used as a graft in the correction of claw fingers because it can be divided into four strips of equal width for their individual use in the fingers. It should be noted that the results obtained were comparable to those obtained using the fascia lata.

Park *et al.* (2012) described a surgical technique that uses the radial half of the ECRB muscle tendon to extend the muscle-tendon unit of the same ECRB for adductorplasty. In their article they recount the case of a patient on whom they used this technique and for whom they obtained very good results.

We did not find any data in the literature of authors who have measured the distance between the radial styloid process and the origin of the RCE muscle tendons. Location of the origin of the RCE muscle tendons from the vertex of the radial styloid process is a surgically significant parameter, as it takes a rather easy bone accident as a reference to recognize before or during any procedure that uses the RCE muscles tendons. Based on our dissections, we can report that the safest zone for the incision and extraction of the ECRL muscle tendon is right in the distal part of the middle

third of the forearm, whereas the safest zone for the incision when extracting the ECRB muscle tendon is in the middle part of the distal third of the forearm.

CONCLUSION

Since the PL muscle tendon is used frequently in tendon transfer surgery and the radial half of the RCE muscle tendons presents morphological and morphometric characteristics similar to it, we believe based on our results that the radial half of the RCE muscle tendons is a good candidate for tendon transfer surgery when the PL muscle is absent. In addition, the tendons of both RCE muscles are sufficiently wide to divide them longitudinally into two halves and reach the thumb, thereby avoiding a graft from another tendon when they are used for a transfer.

ACKNOWLEDGEMENTS

Professor Aglae Soto, Head of the Morphology Unit at the Universidad Católica del Maule and Dr. Oscar Inzunza, Director of the Department of Anatomy at the Pontificia Universidad Católica de Chile for providing the cadaver material used in this study.

CERDA, A & DEL SOL, M. Morfología y morfometría de los tendones de los músculos palmar largo y extensores radiales del carpo en el hombre. *Int. J. Morphol.*, 34(4):1515-1521, 2016.

RESUMEN: Los tendones de los músculos palmar largo (PL) y extensores radiales del carpo (ERC) tienen extensas aplicaciones en cirugía, pero a pesar de su constante uso, es escasa la información respecto a sus características morfológicas y morfométricas. El objetivo de este estudio fue describir las características morfológicas y morfométricas de los tendones de los músculos PL y ERC y compararlas entre sí, en 30 miembros superiores de individuos adultos, sin deformaciones aparentes, pertenecientes a unidades de anatomía de cuatro universidades de Chile. Se diseccionó la cara anterior y el margen lateral del antebrazo, y el dorso de la mano, hasta llegar al plano de los tendones. Los promedios de longitud, anchos a nivel del origen y a nivel de la línea articular radiocarpiana del tendón del músculo PL fueron de 125,48 mm \pm 8,93, 4,76 mm \pm 1,35 y 3,76 mm \pm 0,91, respectivamente. Los promedios de longitud, anchos a nivel de origen y a nivel de la inserción del tendón del músculo extensor radial largo del carpo fueron de 180,46 mm \pm 15,03, 14,69 mm \pm 3,72 y 7,76 mm \pm 1,44, mientras que para el tendón del músculo extensor radial corto del carpo fueron de 115,23 mm \pm 11,81, 9,53 mm \pm 2,58 y 7,33 mm \pm 1,17, respectivamente. El origen más común de los tendones de los músculos PL y extensor radial largo del carpo fue a nivel del tercio medio del antebrazo, mientras que el origen más común del tendón del músculo extensor radial corto del carpo fue a nivel del

tercio distal del antebrazo. La forma de los tendones de los músculos PL y ERC era ancha y plana durante toda su extensión. Al simular la división longitudinal de los tendones de los músculos ERC en dos mitades, la mitad radial de los tendones de ambos músculos presenta características morfológicas y morfométricas similares al tendón del músculo PL, por tanto, eventualmente podrían ser utilizadas para injerto en caso de agenesia del músculo PL, o para transferencia tendinosa, en caso de que se requiera un alargamiento de algún tendón de la región.

PALABRAS CLAVE: Músculo palmar largo; Músculos extensores radiales del carpo; Músculo extensor radial largo del carpo; Músculo extensor radial corto del carpo; Miembro superior; Cirugía de transferencia de tendón.

REFERENCES

- Angelini Júnior, L. C.; Angelini, F. B.; de Oliveira, B. C.; Soares, S. A.; Angelini, L. C. & Cabral, R. H. Use of the tendon of the palmaris longus muscle in surgical procedures: study on cadavers. *Acta Ortop Bras.*, 20(4):226-9, 2012.
- Alves, N.; Ramírez, D. & Deana, N. F. Study of frequency of the palmaris longus muscle in Chilean subjects. *Int. J. Morphol.*, 29(2):485-9, 2011.
- Baek, G. H.; Jung, J. M.; Yoo, W. J. & Chung, M. S. Transfer of extensor carpi radialis longus or brevis for opponensplasty. *J. Hand Surg. Br.*, 24(1):50-3, 1999.
- Brand, P. W. *Clinical Mechanics of the Hand*. St. Louis, Mosby, 1985.
- Ceyhan, O. & Mavt, A. Distribution of agenesis of palmaris longus muscle in 12 to 18 years old age groups. *Indian J. Med. Sci.*, 51(5):156-60, 1997.
- Chetta, M. D.; Ono, S. & Chung, K. C. Partial extensor carpi radialis longus turn-over tendon transfer for reconstruction of the extensor pollicis longus tendon in the rheumatoid hand: case report. *J. Hand Surg. Am.*, 37(6):1217-20, 2012.
- del Sol, M & Vásquez, B. Supernumerary fascicle of the abductor digiti minimi muscle of the hand. Anatomical and clinical importance. *Int. J. Morphol.*, 27(4):1069-72, 2009.
- Doyle J. R. & Botte, M. J. *Surgical Anatomy of the Hand and Upper Extremity*. Philadelphia, Lippincott Williams & Wilkins, 2003.
- Ferreira Caetano, M.; Manna Albertoni, W.; Benedito Caetano, E. & Montano Pérez, R. Estudio anatómico de las inserciones de los músculos extensor radial largo y corto del carpo. *Int. J. Morphol.*, 22(4):245-51, 2004.
- Georgiev, G.; Surchev, L. & Jeleu, L. Transposition of parts between the extensor carpi radialis muscles and their significance for hand surgery. *Bul. J. Orthop. Trauma*, 43(3):130-4, 2006.
- Ito, M. M.; Aoki, M.; Kida, M. Y.; Ishii, S.; Kumaki, K. & Tanaka, S. Length and width of the tendinous portion of the palmaris longus: a cadaver study of adult Japanese. *J. Hand Surg. Am.*, 26(4):706-10, 2001.
- Kigera, J. W. & Mukwaya, S. Frequency of agenesis of Palmaris longus through clinical examination--an East African study. *PLoS ONE.*, 6(12):e28997, 2011.
- Le Double, A. F. *Traité des Variations du Système Musculaire de L'homme*. Vol. 2. Paris, Schleicher Frères, 1897.
- Lippert, L. S. *Clinical Kinesiology and Anatomy*. 4th ed. Philadelphia, F. A. Davis, 2006.
- Llusá Pérez, M.; Meri, A. & Ruano Gil, D. *Manual y Atlas Fotográfico de Anatomía del Aparato Locomotor*. Madrid, Editorial Médica Panamericana, 2004.
- Loren, G. J. & Lieber, R. L. Tendon biomechanical properties enhance human wrist muscle specialization. *J. Biomech.*, 28(7):191-9, 1995.
- Malaviya, G. N. Radial half of extensor carpi radialis longus tendon as graft to elongate muscle tendon unit for correction of finger clawing. *Plast. Reconstr. Surg.*, 111(6):1914-7, 2003.
- Moore, K. L.; Dalley, A. F. & Agur, A. M. R. *Anatomía con Orientación Clínica*. 6a ed. Baltimore, Wolters Kluwer/Lippincott Williams & Wilkins, 2010.
- Murray, W. M.; Buchanan, T. S. & Delp, S. L. The isometric functional capacity of muscles that cross the elbow. *J. Biomech.*, 33(8):943-52, 2000.
- Park, J. S.; Baek, G. H. & Gong, H. S. Modified extensor carpi radialis brevis adductorplasty for ulnar nerve palsy. *Tech. Hand Up Extrem. Surg.*, 16(2):86-90, 2012.
- Standring, S. *Gray's Anatomy: The Anatomical Basis of Clinical Practice*. 40th ed. Philadelphia, Churchill Livingstone/Elsevier, 2008.
- Stecco, C.; Lancerotto, L.; Porzionato, A.; Macchi, V.; Tiengo, C.; Parenti, A.; Sanudo, J. R. & De Caro, R. The palmaris longus muscle and its relations with the antebrachial fascia and the palmar aponeurosis. *Clin. Anat.*, 22(2):221-9, 2009.
- Testut, L. *Les Anomalies Musculaires chez L'homme*. Paris, Masson, 1884.
- Testut, L. & Latarjet, A. *Compendio de Anatomía Descriptiva*. 22ª ed. Barcelona, Salvat, 1975.
- Thompson, N. W.; Mockford, B. J. & Cran, G. W. Absence of the palmaris longus muscle: a population study. *Ulster Med. J.*, 70(1):22-4, 2001.
- Tubbs, R.S.; Salter, E.G. & Oakes, W.J. The tabatière anatomique. *Clin. Anat.*, 19(4):299-303, 2006.
- Wood, J. Variations in human myology observed during the winter session of 1866-67 at King's College, London. *Proc. R. Soc. Lond.*, 15:518-46, 1867.

Correspondence to:
Prof. Dr. Mariano del Sol
Facultad de Medicina
Universidad de La Frontera
Temuco
CHILE

E-mail: mariano.delsol@ufrontera.cl

Received: 16-07-2016

Accepted: 25-09-2016