

A Truncus Bicaroticus and an Aberrant Right Subclavian Artery. A Rare Case and Literature Review

Un Tronco Bicarótico y una Arteria Subclavia Derecha Aberrante.
Un Caso Raro y Revisión de la Literatura

Duygu Vuralı¹; Sema Polat¹; Ferhat Can Piskin² & Pınar Göker¹

VURALI, D.; POLAT, S.; PISKIN, F. C. & GÖKER, P. A truncus bicaroticus and an aberrant right subclavian artery; A rare case and literature review. *Int. J. Morphol.*, 41(3):785-788, 2023.

SUMMARY: An aberrant right subclavian artery described by David Bayford, is rare and one of the aortic arch anomalies. It gives usually incidental findings. We present the case of a 57-year-old woman who was admitted to a neurology outpatient clinic due to a headache and no obvious pathology was detected during a physical examination. In consequence of the brain and chest CT angiography, incidental anomalies of the aortic arch branches were found and asymptomatic aberrant right subclavian artery and bicarotid trunk was diagnosed. The presence of this anomaly is becoming increasingly important in avoiding vascular injuries and cerebral complications in patients undergoing endovascular intervention on the aorta aortic arch surgery, thyroidectomy, or cervicothoracic surgery. So, detailed knowledge of variations of the subclavian artery and bicarotid trunk is paramount for radiologists and surgeons operating on the region of the anterior neck.

KEY WORDS: Aberrant right subclavian artery; Aortic arch malformation; Truncus bicaroticus; Dysphagia lusoria.

INTRODUCTION

In An Aberrant right subclavian artery (ARSA) arises as the last branch off a left-sided aortic arch and represents one of the most common aortic arch anomalies. It was first described by David Bayford in 1794 at the autopsy of a 62-year-old female patient who had been complaining of dysphagia for many years (Bayford, 1794a).

The largest vessels such as aorta and cardinal veins are formed with vasculogenesis mechanism. Classically, the RSA develops from the distal fusion of a persistent right proximal dorsal aorta with the right seventh intersegmental artery. The ARSA is caused by the involution of the right fourth vascular arch and proximal right dorsal aorta and the persistence of the seventh intersegmental artery originating from the proximal descending thoracic aorta, forming the abnormal course of the artery lusoria (Polgıj *et al.*, 2014). Normally, between the 4th and 5th weeks of embryonic life, blood leaves the heart with the truncus arteriosus. The carotic system consists of the first three arch segments. The right fourth arch, a portion of the right ventral aorta, and a part of the right dorsal aorta develop

into the right subclavian artery. The left fourth arch continues as the adult aortic arch with the anlage of the seventh dorsal intersegmental artery, and the left subclavian artery constitutes. Both fifth arches are resorbed (Polgıj *et al.*, 2014, 2016).

Abnormal development of the 4th aortic arch causes the ARSA to arise distal to the left subclavian artery (Inman *et al.*, 2008). Its incidence is between 0.5 % and 1.8 % (Carrizo & Marjani, 2004). Although most cases of this anomaly are asymptomatic and may be discovered incidentally on imaging or at postmortem studies but around 10 % of cases may complain of tracheo-esophageal symptoms, such as dysphagia, cough, and stridor. If compression of the esophagus occurs, this condition is called 'Dysphagia lusoria'. The word lusoria comes from the Latin phrase *lusus naturae*, meaning "freak of nature", which refers to the anomalous course of the artery (Bayford, 1794b).

In this anomaly, the right subclavian artery usually passes behind the esophagus and trachea and travels to the

¹ Cukurova University, Faculty of Medicine, Department of Anatomy, Adana, Turkey.

² Cukurova University, Faculty of Medicine, Department of Radiology, Adana, Turkey.

right axillary region. Less often it can also pass between the trachea and esophagus or in front of the trachea (Kau *et al.*, 2007).

If there is an aneurysmal enlargement of the near-aorta segment of the aberrant subclavian artery, this is called the 'Kommerell diverticulum'. This diverticulum can compress the tracheoesophageal, expand excessively, resulting in dissection or rupture. 20-60 % of people with abnormal subclavian arteries also have Kommerell's diverticulum (Lee & Kim, 2019).

CASE REPORT

A 57-year-old female patient who was admitted to a neurology outpatient clinic due to a headache and no obvious pathology was detected during a physical examination, it was planned to perform a brain CT angiography. No truncus brachiocephalicus was observed on CT angiography, and both common carotid arteries emerged from a common truncus (Fig. 1). ARSA originating from the posterior wall of the aortic arch as its last branch and it passed obliquely between trachea and vertebral column and then coursed upwards on the right side (Fig. 2). ARSA passed behind the trachea and esophagus. The vessel diameters of the branches of the aortic arch are shown, and there is no significant difference between the diameters of the ARSA and the left subclavian artery and There was no significant difference between the diameters of both common carotid arteries (Fig. 3). In the study of Manole *et al.* (2013) the relative caliber of the arterial branches of the aortic arch depends on the position of their origin from the aortic arch. The right common carotid artery had a diameter of 4.7 to 5.5 mm in females, the left common carotid artery diameter was 4.6 to 5.7 mm in females (Manole *et al.*, 2013).

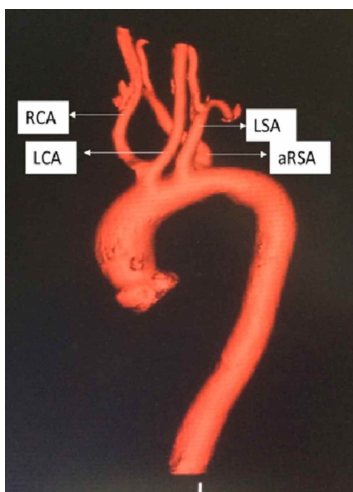


Fig. 1. This aberrant anatomy was clearly visible in computed tomography images reconstructed 3-dimensionally using a volume-rendering technique. Truncus bicaroticus arises as the first branch of the aortic arch, the right and left carotid arteries originate from truncus bicaroticus. Left subclavian artery (LSA) arises as the second branch of the aortic arch. ARSA arises at the distal end of the aortic arch from the right side.

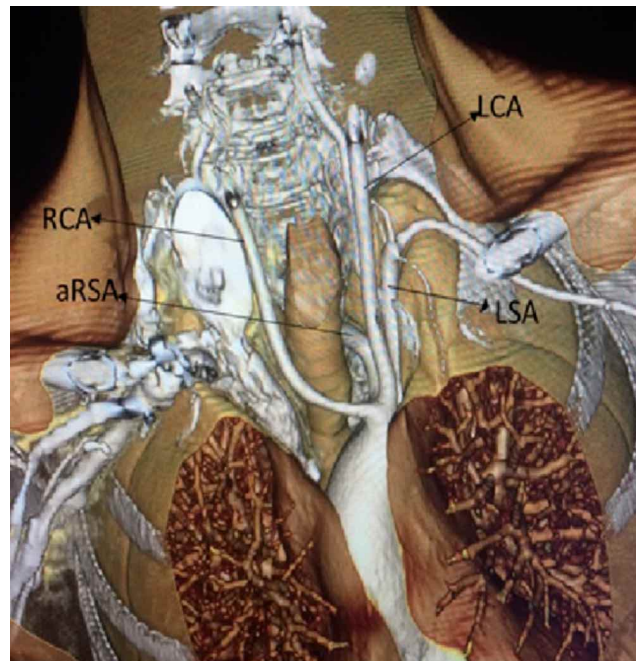


Fig. 2. ARSA originating from the posterior wall of the aortic arch as its last branch distal to the origin of the left subclavian artery and it passed obliquely between trachea and vertebral column and then coursed upwards on the right side.

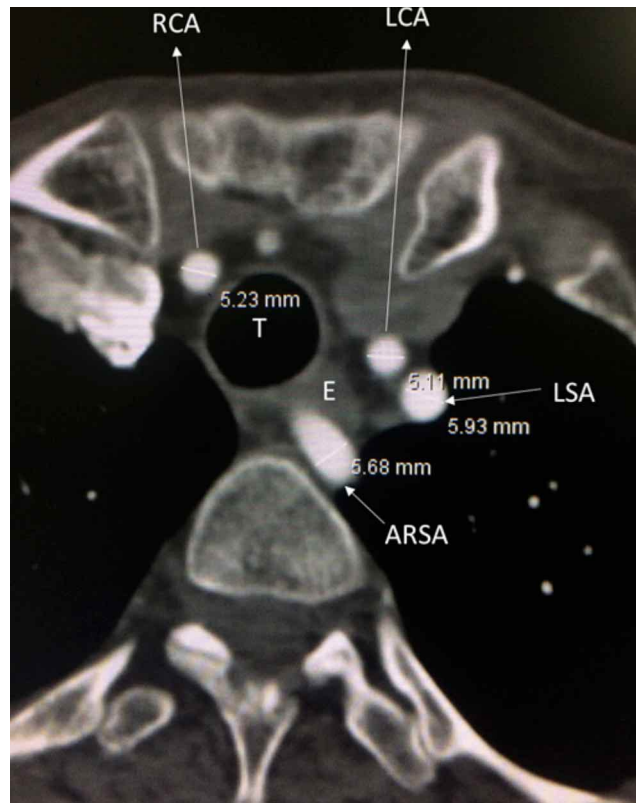


Fig. 3. ARSA passed behind the trachea and esophagus. The diameter of the ARSA is 5.68 mm and LSA is 5.93 mm. The diameter of the RCA is 5.23 mm and LCA is 5.11 mm.

In the case we presented, the diameter of the right common carotid artery was 5.23 mm, and the diameter of the left common carotid artery was 5.11 mm, which was within normal limits.

The right subclavian artery showed a caliber of 5.7 to 7.5 mm in females and The left subclavian artery had a diameter of 6-10 mm in females. In the case we presented, the diameter of the ARSA was 5.68 mm, the diameter of the left subclavian artery was 5.93 mm, and it looked thinner than normal, which may be due to the existing aortic arch anomaly (Manole *et al.*, 2013).

The right subclavian artery was the last branch of the arcus aorta and passed behind the trachea and esophagus and continued to the right axilla (Fig. 2). No pathology was observed in the vertebrobasilar system and cranial arterial structures. There were no signs and symptoms related to ARSA in the patient.

DISCUSSION

Surgical In patients with ARSA, dysphagia becomes more pronounced with advancing age include decreased flexibility of the esophagus itself and compression of the esophagus by the aberrant right subclavian artery can be exacerbated by atherosclerosis or aneurysmal dilatation with advanced age (Kantarceken *et al.*, 2004).

The presence of truncus bicaroticus in combination with the ARSA increases the likelihood of dysphagia, by disruption of esophageal motility. In the case of an associated common carotid trunk, the tracheoesophageal tract is limited in its anterior movements (Klinkhamer, 1963, 1966).

The recurrent laryngeal nerve (RLN), also known as the inferior laryngeal nerve, is a branch of the vagus nerve (CN X) which has a characteristic loop around the right subclavian artery on the right and the aortic arch on the left before returning up to achieve the tracheoesophageal groove and then the larynx.

Furthermore in the presence of ARSA, right inferior laryngeal nerve will be abnormally nonrecurrent. As can be expected from the embryological development of the artery, the right recurrent laryngeal nerve is entering the larynx directly (Work, 1941).

The presence of ARSA together with an absence of the right recurrent laryngeal nerve is clinically important; during thyroid surgery, the right laryngeal nerve cannot be

found at the lower pole of the thyroid, and it may be injured by the surgeon if it is not identified in the aberrant area or found lateral to the thyroid (Nakatani *et al.*, 1996; Kaidoh & Inoué, 2011).

In cases of ARSA where esophageal and thyroid surgery will be performed even the asymptomatic cases of this arterial anomaly become challenging. Due to the proximity of the aberrant artery to the esophagus, if the ARSA was not identified preoperatively, any surgical procedure involving the esophagus without sufficient care may result in life-threatening issues (Lacout *et al.*, 2012).

Prolonged nasogastric and endotracheal intubation can lead to gastrointestinal bleeding in patients who have an aberrant right subclavian artery or other vascular ring. Long-term intubation and nasogastric administration should be avoided along with ARSA and if necessary, tracheostomy and gastrostomy should be performed at an early stage. The mechanism underlying the fistulous connection could involve limited necrosis of the mucosal and arterial walls caused by pulsatile compression of the esophageal wall between the ARSA and a semirigid catheter. This would lead to thrombosis of the vasa vasorum and ischemia of the digestive wall (Dores *et al.*, 1991).

ARSAs have a course close to the thoracic vertebrae. Attention should be paid to the surgery for the thoracic vertebrae in the patient with ARSA and precautions should be taken for complications that may occur. Thorpe *et al.* (2011) reported that ARSA bleeding in a case of debridement of T2 for osteomyelitis resulted in a complication and eventual mortality.

Cross-sectional imaging, such as CT and MR imaging will show the relationship of the various mediastinal vessels and structures with out the need for conventional catheter angiography. In asymptomatic patients the nonaneurysmal aberrant subclavian artery is a normal variant. Unassociated with intracardiac defects and requires no further evaluation or treatment (Freed & Low, 1997).

A diagnosis of ARSA should be suspected if the guide wire repeatedly enters the descending aorta from the right subclavian artery rather than the ascending aorta during aortography via the right radial artery. In this case, catheterization of the ascending aorta may be difficult or even impossible because of the angular course of the ARSA to the ascending aorta (Jiang & Zhu, 2017).

CONCLUSION .ARSA cases carries a risk of injury during the esophageal and thyroid surgery therefore should be evaluated preoperatively through proper imaging studies.

In conclusion, previous identification of aberrant right subclavian artery is important in avoiding vascular injuries and cerebral complications in patients undergoing endovascular intervention on the aorta, aortic arch surgery, thyroidectomy or cervicothoracic surgery.

ARSA is rare variation of the branch from the aortic arch. Clinicians should be aware of the anatomy and clinical importance of an ARSA. In particular, to avoid long-term use of a nasogastric tube and the devastating consequences of an ARSA-esophageal fistula, it is important to be aware ARSA, as well as preoperative identification of ARSA before surgical approaches to upper thoracic vertebrae in order to avoid complications and effect proper treatment. In patients with a known ARSA, a right transradial approach for aortography or cerebral angiography should be changed to a left radial artery or transfemoral approach.

VURALI, D.; POLAT, S.; PISKIN, F. C. & GÖKER, P. Un tronco bicarótico y una arteria subclavia derecha aberrante; Un caso raro y revisión de la literatura. *Int. J. Morphol.*, 41(3):785-788, 2023.

RESUMEN: Una arteria subclavia derecha aberrante descrita por David Bayford, es rara y es una de las anomalías del arco aórtico. Además, suele ser hallazgos accidentales. Presentamos el caso de una mujer de 57 años que ingresó a una consulta de neurología por dolor de cabeza, sin embargo, no se le detectó patología evidente al examen físico. En el angio-TC de cerebro y tórax, se encontraron anomalías incidentales de las ramas del arco aórtico y se diagnosticó arteria subclavia derecha aberrante asintomática y tronco bicarotídeo. Determinar la presencia de esta anomalía es cada vez más importante, para así evitar lesiones vasculares y complicaciones cerebrales en pacientes sometidos a intervención endovascular de la aorta, cirugía del arco aórtico, tiroidectomía o cirugía cervicotórácica. Por lo tanto, el conocimiento detallado de las variaciones de la arteria subclavia y el tronco bicarotídeo es primordial para los radiólogos y cirujanos que operan en la región anterior del cuello.

PALABRAS CLAVE: Arteria subclavia derecha aberrante; Malformación del arco aórtico; Tronco bicarótico; Disfagia lusoria.

REFERENCES

Bayford, D. An account of a singular case of deglutition. *Mem. Med. Soc. Lond.*, 2:271, 1794b.
Bayford, D. An account of a singular case of obstructed deglutition. *Mem. Med. Soc. Lond.*, 2:275-86, 1794a.
Carrizo, G. J & Marjani, M. A. Dysphagia lusoria caused by an aberrant right subclavian artery. *Tex Heart Inst. J.*, 31(2):168-71, 2004.
Dores, G. M.; Miller, M. E. & Kaufman, D. G. A herald bleed: a case of aorto-esophageal fistula and a review of the literature. *R. I. Med. J.*, 74(3):123-6, 1991.
Freed, K. & Low, V. The aberrant subclavian artery. *AJR Am. J. Roentgenol.*, 168(2):481-4, 1997.

Inman, J. C.; Kim, P. & McHugh, R. Retroesophageal subclavian artery--esophageal fistula: a rare complication of a salivary bypass tube. *Head Neck*, 30(8):1120-23, 2008.
Jiang, X. H. & Zhu, X. Y. Abnormal origin of the right subclavian artery: a case report. *Chin. Med. J. (Engl.)*, 130(12):1508-9, 2017.
Kaidoh, T. & Inoué, T. Simultaneous occurrence of an aberrant right subclavian artery and accessory lobe of the liver. *Anat. Sci. Int.*, 86(3):171-4, 2011.
Kantarceken, B.; Bulbuloglu, E.; Yuksel, M. & Cetinkaya, A. Dysphagia lusoria in the elderly: a case report. *World J. Gastroenterol.*, 10(16):2459-60, 2004.
Kau, T.; Sinzig, M.; Gasser, J.; Lesnik, G.; Rabitsch, E.; Celedin, S.; Eicher, W.; Illiasch, H. & Hausegger, K. A. Aortic development and anomalies. *Semin. Intervent. Radiol.*, 24(2):141-52, 2007.
Klinkhamer, A. C. Aberrant right subclavian artery. Clinical and roentgenologic aspects. *Am. J. Roentgenol. Radium. Ther. Nucl. Med.*, 97(2):438-46, 1966.
Klinkhamer, A. C. Het vaststellen van aberrante arterien in het mediastinum superius door middel van oesophagogram. *Ned. Tijdschr. Geneesk.*, 107:510, 1963.
Lacout, A.; Khalil, A.; Figl, A.; Liloku, R. & Marcy, P. Y. Vertebral arteria lusoria: a life-threatening condition for oesophageal surgery. *Surg. Radiol. Anat.*, 34(4):381-3, 2012.
Lee, M. W. & Kim, G. H. Kommerell's diverticulum: a rare cause of esophageal subepithelial lesion. *Korean J. Intern. Med.*, 34(6):1392-3, 2019.
Manole, A. M.; Ilescu, D. M.; Rusali, A. & Bordei, P. Morphometry of the aortic arch and its branches. *ARS Med. Tomitana*, 19(3):154-9, 2013.
Nakatani, T.; Tanaka, S.; Mizukami, S.; Okamoto, K.; Shiraiishi, Y. & Nakamura, T. Retroesophageal right subclavian artery originating from the aortic arch distal and dorsal to the left subclavian artery. *Ann. Anat.*, 178(3):269-71, 1996.
Polguy, M.; Chrzanowski, ?.; Kasprzak, J. D.; Stefan ´czyk, L.; Topol, M. & Majos, A. The aberrant right subclavian artery (arteria lusoria): the morphological and clinical aspects of one of the most important variations--a systematic study of 141 reports. *ScientificWorldJournal*, 2014:292734, 2014.
Polguy, M.; Stefan ´czyk, L. & Topol, M. *The Epidemiological, Morphological, and Clinical Aspects of the Aberrant Right Subclavian Artery (Arteria Lusoria)*. Web. IntechOpen, 2016.
Thorpe, S. W.; Hohl, J. B.; Gilbert, S.; Tannoury, C. A. & Lee, J. Y. Aberrant right subclavian artery encountered during debridement of T2 osteomyelitis and associated phlegmon. *Spine J.*, 11(2):e6-10, 2011.
Work, W. P. Unusual position of the right recurrent laryngeal nerve. *Ann. Otol. Rhinol. Laryngol.*, 50(3):769-75, 1941.

Corresponding author:

Duygu Vuralı
Çukurova University
Faculty of Medicine
Department of Anatomy
01330 Balcalı – Adana
TURKEY

E-mail: d.vuralı@hotmail.com

Orcid number:

Duygu Vuralı	0000-0002-8213-6387
Sema Polat	0000-0001-7330-4919
Ferhat Can Piskin	0000-0003-4092-1077
Pınar Göker	0000-0002-0015-3010