

# Has the Literature Thoroughly Categorized the Lower Third Molars? A New Classification of the Various Lower Third Molar Root Forms for a Better Understanding of their Morphology

¿La Literatura ha Categorizado Minuciosamente los Terceros Molares Inferiores? Una Nueva Clasificación de las Diversas Formas Radiculares del Tercer Molar Inferior para una Mejor Comprensión de su Morfología

Nedal Abu-Mostafa

**ABU-MOSTAFA, N.** Has the literature thoroughly categorized the lower third molars? A new classification of the various lower third molar root forms for a better understanding of their morphology. *Int. J. Morphol.*, 41(1):278-285, 2023.

**SUMMARY:** Impacted lower third molars (IL3M) have different root shapes and numbers. This study aimed to create a classification for IL3M root forms, that should aid in understanding roots morphology. A retrospective cross-sectional study on patients had IL3M at the university clinics between 2017 and 2019. Panoramic radiographs were retrieved to classify the roots into fused roots (FR): one or two roots connected from furcation to apices, and separated roots (SR): two or more roots not connected from furcation to apical third, and each type has different forms. Statistical analysis was done by Chi-Square test. Five-hundred patients, males (54.6 %) and females (45.4 %) were included. SR were in 591 teeth (75.5 %), and FR in 192 teeth (24.5 %). Statistically significant associations emerged between SR and males (60 %) and between FR and females (66 %) ( $p = .000$ ). SR forms were straight (45.8 %), joined roots (28.2 %), one straight and one curved (13.3 %), roots curved distal (9.1 %), roots curved mesial (2.5 %), and more than two roots (0.3 %). FR forms were straight (87.5 %), curved distal (9.4 %), S-shaped (2.1 %), and curved mesial (1 %). The common angulations of IL3M with SR were vertical (39 %) followed by mesioangular (25.7 %), while FR were mostly vertical (39.1 %) or horizontal (23.9 %). The classification is applicable on panoramic radiographs, and complements Winter and Pell & Gregory to provide a better description of IL3M status by adding root morphology to the angulation, occlusal, and ramus relationship.

**KEY WORDS:** Impacted lower third molar; Root morphology; Root shapes; Fused roots; Separated roots.

## INTRODUCTION

The third molars erupt between the ages of 17 and 25 years old (Sidow *et al.*, 2000), and they are considered impacted when they have not erupted or will not erupt into normal occlusal position due to lack of space or abnormal angulation (Akarşlan & Kocabay, 2009). Failure of eruption results in multiple complications, including pericoronitis, localized pain, mucosal ulceration, odontogenic cysts (Dog̃an *et al.*, 2007). The bad effects of the impacted lower third molars (IL3M) on the adjacent 2nd molar include caries on the distal wall and cervical area, root resorption, and distal bone loss (Irja, 2014).

Panoramic radiograph, a two-dimensional image, is widely used in dentistry. It is useful for determining the locations, angulations, and roots of IL3M and their relationships with surrounding structures, such as the inferior

alveolar canal, ramus, and lower 2nd molars (Dalili *et al.*, 2011). Cone-Beam Computed Tomography (CBCT), on the other hand, is more accurate and shows 3-dimensional details, but it is more expensive and exposes the patient to a higher dosage of radiation than a panoramic radiograph (Peker *et al.*, 2014).

The IL3M classification systems based on position and degree of impaction improves interdisciplinary communication and treatment planning. Pell and Gregory's classifications are commonly used in clinical practice to categorize the position of IL3M according to its spatial relationships with the ascending ramus of the jaw and the occlusal plane (Brasil *et al.*, 2019). Winter's classification is based on the inclination of IL3M that can be measured between its long axis and the occlusal plane (Akarşlan & Kocabay, 2009) or the long axis

Department Oral and Maxillofacial Surgery and Diagnostic Science Riyadh Elm University, Kingdom of Saudi Arabia.

Received: 2022-10-27 Accepted: 2022-11-24

of the second molar (Khojastepour *et al.*, 2019). However, neither Winter nor Pell & Gregory classification systems included a description of the roots.

The purpose of this study was to produce a new classification system for the diverse root forms of IL3M which have various numbers and curvatures that may involve one or two roots with different directions. These variations in the root anatomy are observed on panoramic radiographs and can be categorized into particular forms. The specific aims of the study were to describe the frequency of the different root forms, determine whether they manifested unilaterally or bilaterally, and analyze their associations with sex and other impaction classification systems.

## MATERIAL AND METHOD

**Study design:** A retrospective cross-sectional study was carried out on patients who presented to the University's screening clinics between 2017 and 2019. The clinical progress notes and the dental panoramic radiographs for the patients were retrieved from the digitized filing system of the IT department. Inclusion criteria were patients with IL3M diagnosed clinically and radiographically as partially or fully impacted and with fully formed roots. Exclusion criteria included missed clinical information, unclear panoramic radiograph, incomplete apex formation, and root resorption.

The Institute Review Board approved the study, and the University's Research Center registered it under the registration number "RC/IRB/2019/307." The study complied with the World Medical Association's Declaration of Helsinki, and the patients' information was kept confidential and available only to the author.

**Sample size:** A sample of 500 patient's file was decided based on the effect size of (0.193), alpha error probabilities of (0.05), and power of (0.95) required for the goodness of fit tests with four degrees of freedom. The sample size calculation was performed using G power 3.1.9.7 sample size calculator.

**Study variables:** The roots of the included IL3M were categorized based on the new classification system into two types, fused and separated which were considered as the primary predictor variables in this study. "Fused roots" were defined as one or two roots connected from the furcation to the apices. "Separated roots" were defined as two or more roots not connected from the furcation to the apical third. Each type has different forms which were defined and assigned codes that consist of first letters of the root type followed by the root form's number (Table I). The frequency of root's types was recorded whether they presented bilaterally or unilaterally. The presence of hypercementosis was added as a modification to the form. Moreover, Figure 1 and Figure 2 demonstrate the different forms of fused and separated roots respectively.

Other predictor variables were the angulations of IL3M and their classes based on Pell & Gregory Classifications. The IL3M were categorized according to Winter's classification by measuring the angle between the long axis of the tooth and the occlusal plane. The IL3M was considered horizontal when the angle was 0° to 30°, mesioangular from 31° to 60°, vertical from 61° to 90°, and distoangular greater than 90°. Pell & Gregory Classification of the IL3M occlusion was done according to the following criteria. Class A: The occlusal surface of the IL3M above or at the same level as the second molar. Class B: The occlusal surface of the IL3M between the occlusal plane and cemento-enamel junction of the second molar. Class C: the occlusal surface of the IL3M is completely below the cemento-enamel junction of the second molar. The classifications of Pell & Gregory in relation to the ramus were defined as Class 1: The whole crown of the IL3M is anterior

Table I. The definition and the code for each form of fused and separated roots according to the new classification.

Root Type	Code	Forms	Definition
Fused roots	FR.1*	Straight	The root is Straight
	FR.2	Curved distal	The root apical third is curved distal
	FR.3	Curved mesial	The root apical third is curved mesial
	FR.4	S-shaped	The root has two curvatures to present like S-shape
Separated roots	SR.1**	Straight	The roots are straight or has slight curvature on the long axis of the tooth but they do not contact to each other
	SR.2	Both roots are curved distal	The roots' apical thirds are curved distal
	SR.3	Both roots are curved mesial	The roots' apical thirds are curved mesial
	SR.4	Joined roots	The roots have a gap at the furcation and the middle third then contact to each other at the apices
	SR.5	One root is straight and one is	One root is straight and the other is curved wither mesial or distal root
	SR.6	More than two roots	More than two roots appear clearly in the X-ray film

\* C letter is added to the code in the presence of hypercementosis roots; FR.1.C. \*\* C letter is added to the code in the presence of hypercementosis roots; SR.1.C

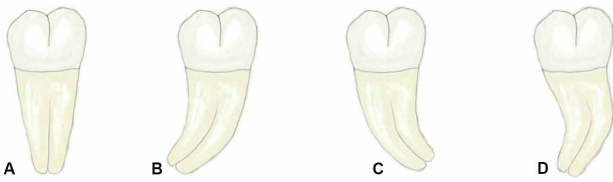


Fig. 1. Different forms of fused roots A. Straight. B. Curved distal. C. Curved mesial. D. S-shaped.

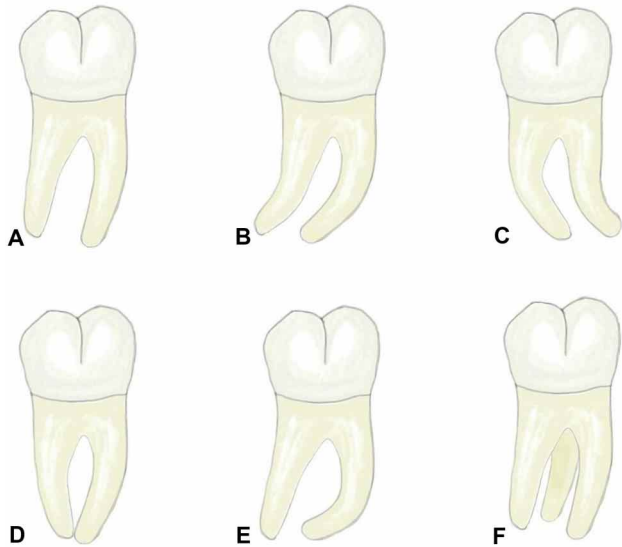


Fig. 2. Different forms of separated roots A. Straight. B. Both roots are curved distal. C. Both roots are curved mesial. D. Joined roots. E. One root is straight and one is curved. F. More than two roots.

to the ramus, Class 2: Part of the crown of the IL3M is covered by the ramus bone, Class 3: The whole crown of the IL3M is covered by the ramus bone.

The primary outcomes variables are the associations between root forms and Winter and Pell & Gregory Classifications. The common angulations, occlusal and ramus relationships were calculated per each root form.

**Data collection methods:** The patients' age and sex were documented on the data collection form. The author and an Oral and Maxillofacial Surgeon from the same institute evaluated and calibrated independently the panoramic radiographs and classified the roots of IL3M into two types, fused and separated. The data was then reviewed to look for any discrepancies between the chosen root forms. These cases were rejected and omitted from the study samples due to the radiograph's lack of clarity.

**Data analysis:** Descriptive statistics were done by SPSS software (version.24) to calculate the frequencies and percentages of IL3M root forms, angulations, occlusal, and ramus classifications. Chi-square test was used to assess the association between various root forms and the other variables.

## RESULTS

The retrieved data from the digitized system included 3177 patients' files that had panoramic X-ray. Five hundred patients fulfilled the study's inclusion criteria; 273 (54.6 %) were males, and 227 (45.4 %) were females. The patients' ages ranged from 21 to 52 years, and the mean age was 30 years. A total of 783 IL3M were included; 591 (75.5 %) IL3M had separated roots and 192 (24.5 %) IL3M had fused roots.

Sixty-six percent of patients with fused roots were females, and the difference between males and females was statistically significant ( $p=0.000$ ). In contrast, 60 % of patients with separated roots were males, which has statistically significant difference from females ( $p=0.000$ ).

The most frequent form of fused roots was straight (87.5 %), followed by curved distal (9.4 %), S-shaped (2.1 %), and curved mesial (1 %). Regarding separated roots, the most common form was straight (45.8 %), followed by joined roots (28.2 %), and one straight and one curved root (13.3 %), with variation in the root's curvature or direction. The most common variant was mesial root curved distal, which was recorded in 65 out of 79 IL3M (82.3 %), followed by distal root curved mesial in 12 IL3M (15.2 %) and distal root curved distal in 2 IL3M (2.5 %). The least common forms of separated roots were roots curved mesial (2.5 %) and more than two roots (0.3 %). Twenty-four IL3M had hypercementosis and the percentage was (3.1 %). Four cases were IL3M with fused roots and 20 cases were IL3M with separated roots. There was no statistically significant difference between the two types ( $p=0.474$ ).

The relationship between the fused and separated roots' forms and Winter and Pell & Gregory classifications are available in Tables II and III. The study found a statistically significant association between the forms of separated roots and the IL3M angulation ( $p=0.000$ ). On the other hand, the associations of the forms of separated roots with Pell & Gregory classifications of occlusion and ramus were statistically non-significant, with  $p$ -values of .223 and .098 respectively. No statistically significant associations emerged between the forms of fused roots and other variables, including angulation, Pell & Gregory occlusal and ramus classifications, with  $p$ -values of .562, .557, and .679, respectively.

IL3M presented unilaterally in 217 patients (43.4 %) and bilaterally in 283 patients (56.6 %). The bilateral IL3M may had similar or different root forms on the two sides, and the distributions whether the roots were fused or separated are available in Table IV.

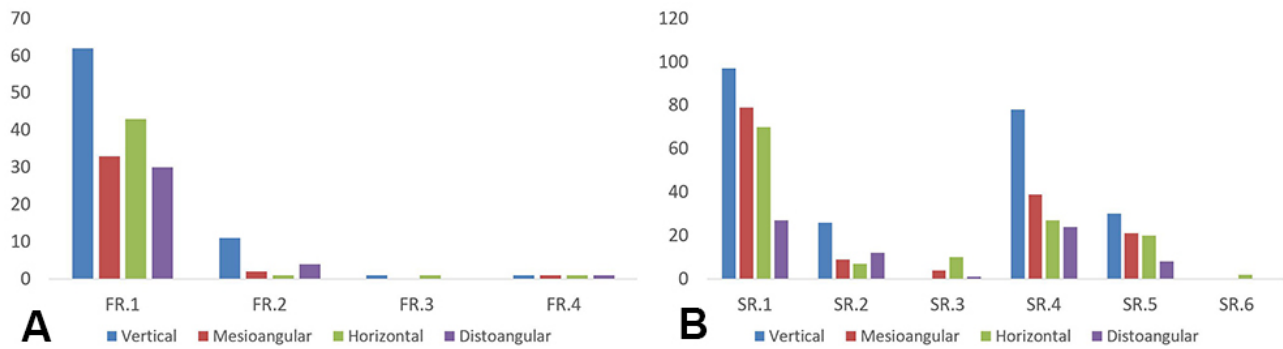


Fig. 3. The association between various root forms and Winter classification. A. Fused root forms and angulations. B. Separated root forms and angulations.

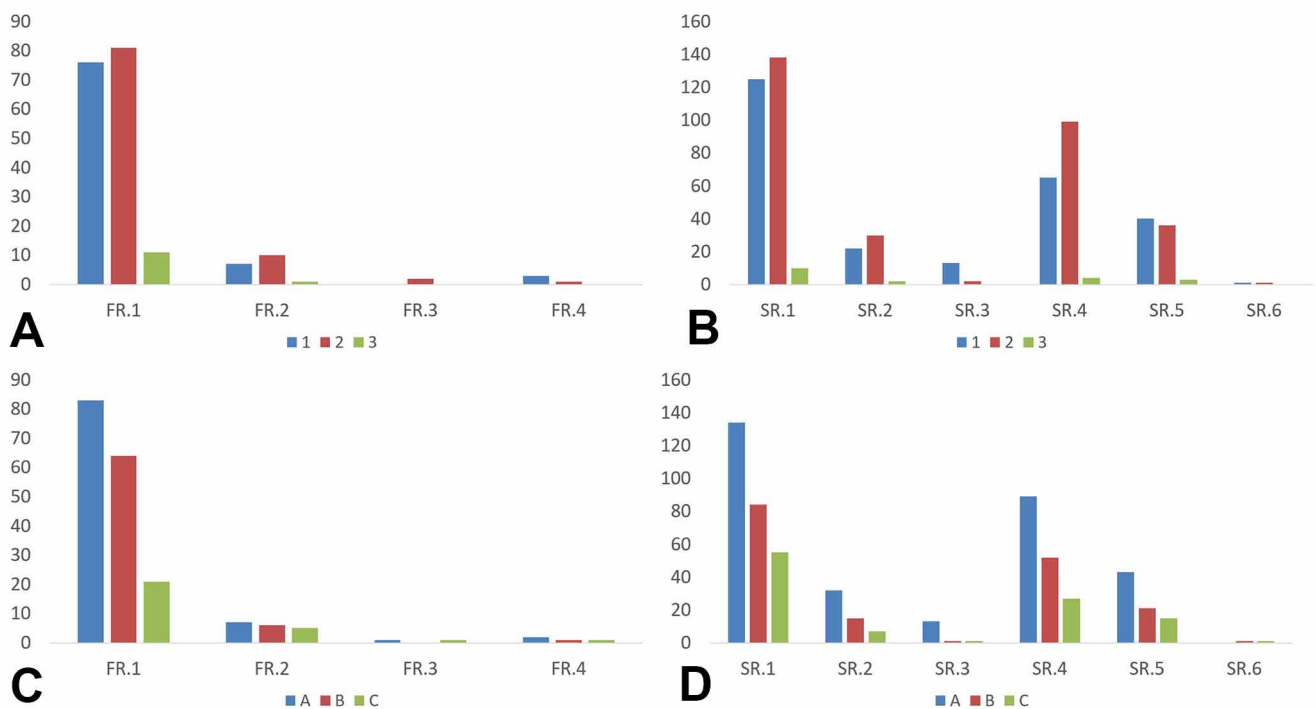


Fig. 4. Association between root forms and Pell & Gregory classifications. A. Fused root forms and ramus relationship. B. Separated root forms and ramus relationship. C. Fused root forms and occlusal relationship with the 2nd molar. D. Separated root forms and occlusal relationship with the 2nd molar

Table II. The frequency of fused roots' forms and their association with Winter and Pell & Gregory classifications. The percentages were calculated within the root form.

	Separated roots	SR.1 Straight	SR.2 Both curved distal	SR.3 Both curved mesial	SR.4 Joined roots	SR.5 One root is straight one is curved	SR.6 More than two roots	Total separated roots
Winter	Number	273	54	15	168	79	2	591
	Vertical	97(35.5 %)	26 (48.1 %)	0 (0 %)	78 (46.4 %)	30 (38.0 %)	0 (0 %)	231 (39 %)
	Mesioangular	79 (28.9 %)	9 (16.7 %)	4 (26.7 %)	39 (23.2 %)	21 (26.6 %)	0 (0 %)	152 (25.7 %)
	Horizontal	70 (25.6 %)	7 (13 %)	10 (66.7 %)	27 (16.1 %)	20 (25.3 %)	2 (100 %)	136 (23 %)
	Distoangular	27 (9.9 %)	12 (22.2 %)	1 (6.7 %)	24 (14.3 %)	8 (10.1 %)	0 (0 %)	72 (12.2 %)
Pell & Gregory occlusion	A	134 (49 %)	32 (59.3 %)	13 (86.7 %)	89 (53.0 %)	43 (54.4 %)	0 (0 %)	311 (52.6 %)
	B	84 (30.8 %)	15 (27.8 %)	1 (6.7 %)	52 (31.0 %)	21 (26.7 %)	1 (50.0 %)	174 (29.4 %)
	C	55 (20.2 %)	7 (13 %)	1 (6.7 %)	27 (16.1 %)	15 (18.9 %)	1 (50.0 %)	106 (18 %)
Pell & Gregory	1	125 (45.8 %)	22 (40.7 %)	13 (86.7 %)	65 (38.7 %)	40 (50.6 %)	1 (50.0 %)	266 (45 %)
	2	138 (50.5 %)	30 (55.6 %)	2 (13.3 %)	99 (58.9 %)	36 (45.6 %)	1 (50.0 %)	306 (51.8 %)
	3	10 (3.7 %)	2 (3.7 %)	0 (0 %)	4 (2.4 %)	3 (3.8 %)	0 (0 %)	19 (3.25 %)

Table III. The frequency of separated roots' forms and their association with Winter and Pell & Gregory classifications. The percentages were calculated within the root form.

	Separated roots	SR. 1 Straight	SR.2 Both curved distal	SR. 3 Both curved mesial	SR.4 Joined roots	SR.5 One root is straight one is curved	SR.6 More than two roots	Total separated roots
	Number	273	54	15	168	79	2	591
Winter	Vertical	97(35.5 %)	26 (48.1 %)	0 (0 %)	78 (46.4 %)	30 (38.0 %)	0 (0 %)	231 (39 %)
	Mesioangular	79 (28.9 %)	9 (16.7 %)	4 (26.7 %)	39 (23.2 %)	21 (26.6 %)	0 (0 %)	152 (25.7 %)
	Horizontal	70 (25.6 %)	7 (13 %)	10 (66.7 %)	27 (16.1 %)	20 (25.3 %)	2 (100 %)	136 (23 %)
	Distoangular	27 (9.9 %)	12 (22.2 %)	1 (6.7 %)	24 (14.3 %)	8 (10.1 %)	0 (0 %)	72 (12.2 %)
Pell & Gregory occlusion	A	134 (49 %)	32 (59.3 %)	13 (86.7 %)	89 (53.0 %)	43 (54.4 %)	0 (0 %)	311 (52.6 %)
	B	84 (30.8 %)	15 (27.8 %)	1 (6.7 %)	52 (31.0 %)	21 (26.7 %)	1 (50.0 %)	174 (29.4 %)
	C	55 (20.2 %)	7 (13 %)	1 (6.7 %)	27 (16.1 %)	15 (18.9 %)	1 (50.0 %)	106 (18 %)
Pell & Gregory	1	125 (45.8 %)	22 (40.7 %)	13 (86.7 %)	65 (38.7 %)	40 (50.6 %)	1 (50.0 %)	266 (45 %)
Pell & Gregory	2	138 (50.5 %)	30 (55.6 %)	2 (13.3 %)	99 (58.9 %)	36 (45.6 %)	1 (50.0 %)	306 (51.8 %)
Ramus	3	10 (3.7 %)	2 (3.7 %)	0 (0 %)	4 (2.4 %)	3 (3.8 %)	0 (0 %)	19 (3.25 %)

Table IV. The distributions of bilateral impacted lower third molars (IL3M) that had similar or different root forms in both sides. IL3M: impacted lower third molars. B: bilateral.

Bilateral IL3M: 283			
Side of impaction	Bilateral separated	Bilateral Fused	Bilateral Separated and fused
Cases	190 (67.13 %)	53 (18.7 %)	40 (14.13 %)
Different root forms	106	8	-
Similar root forms	84	45	-
	B SR.1: 47 (56 %)	B FR.1: 43 (95.55 %)	
	B SR.4: 27 (32 %)	B FR.2: 1 (2.22 %)	
	B SR.2:5 (6 %)	B FR.4: 1 (2.22 %)	
	B SR.5: 3 (3.6 %)		
	B SR.3: 2 (2.4 %)		

## DISCUSSION

The lower third molars are the last teeth to erupt into the oral cavity and commonly get impacted. They were a popular topic in the literature due to the frequency of their problems and the requirement for surgical extraction (Dog'an *et al.*, 2007). Although Winter and Pell & Gregory are well-known classifications that describe the angulations and positions of IL3M, they ignore the description of roots which vary in number and shape, so studying them requires extra attention. The current study's goals were to describe and classify the anatomical variants of IL3M roots, as well as to investigate the association of different forms with Winter and Pell & Gregory classifications. The new classification system for the roots of IL3M should be applied and rely on a widely used X-ray. Therefore, a panoramic radiograph was selected in this study, as it is still the standard imaging method for the preoperative evaluation of IL3M. It is also available in most dental clinics at a reasonable cost and emits a modest dosage of radiation (Brasil *et al.*, 2019).

IL3M present with different number of roots, which could be one or more (Mohammadi *et al.*, 2015). In this study, the higher percentage of IL3M (75.5 %) had separated

roots and most had two roots. This result consistent with other studies in the literature. da Silva Sampieri *et al.* (2018) studied the positions and root anatomy of lower third molars, and recorded that the higher percentage had 2 roots (98.3 %), followed by 1 root (1.5 %), and the least common was 3 roots (0.2 %). Several literature studies have focused on the shapes of canals and the number of roots of IL3M for endodontic purposes without considering root morphologies. Sidow *et al.* (2000), Gulabivala *et al.* (2001), Lübbers *et al.* (2011), and Kuzekanani *et al.* (2012) found that mandibular third molars commonly have two roots, and they reported the percentages of 77 %, 68 %, 80.5 %, and 73 %, respectively.

The IL3M root' classification in this study issues a specific code for each form of fused and separated roots. These codes are simple and can be recorded in the patient's file to indicate the roots' anatomy of IL3M after radiological examination or surgical extraction. Furthermore, the classification defines root types and forms of IL3M depending on root's number, shape, and curvature. The presence of hypercementosis was not considered as a

separate entity, because it can associate any root form regardless the direction or curvature. Therefore, it should be added to the root form as a modification. Conical or fused roots were classified as one type because they produce less resistance to luxation forces and have the least extraction difficulty (Carvalho & do Egito Vasconcelos, 2011). Straight root (Fig. 1a) was the most commonly recorded form of fused roots (87.5 %). However, the presence of one or two curvatures (S-shaped) makes the extraction more difficult, especially when the curvature is in the opposite direction or against the path of root elevation (Gbotolorun *et al.*, 2007). The most frequent root curvature was distal (Fig. 1b), followed by S-shaped (Fig. 1d), while mesial curvature was the least common (Fig. 1c). The IL3M with separated two roots are more likely to result in root fractures if extracted by elevators and forceps. As a result, crown sectioning and root separation should be considered for such molars to reduce the retention areas and facilitate the extraction without injury to the bone or inferior alveolar canal (Genú & Vasconcelos, 2018). The presence of curved roots makes the extraction more complicated, and the appreciation of the curvature direction is necessary before extraction (Gbotolorun *et al.*, 2007). Fortunately, the most common recorded form of separated roots was the straight (45.8 %) (Fig. 2a). Distal curvature of both roots (Fig. 2b) was presented only in 9.1 % of cases, which was more common than mesial curvature (2.5 %) (Fig. 2c). Furthermore, 13.3 % of cases had one curved root and one straight root (Fig. 2e). However, the distal curvature of the mesial root was the most common. The second common form of separated roots was joined roots (28.2 %) (Fig. 2d), characterized by a gap of bone between the middle of the two roots while the apices are connected. This connection between the roots resists the movement during luxation and may cause breakage of the root apex. Furthermore, during the procedure of root separation, the bur will cut the pulp chamber's floor to create a gap between the coronal portions of the roots, while the apices will remain linked. As a result, luxation of roots by a straight elevator may inappropriately split the apex or break part of the root. The least recorded form of separated roots was the presence of more than two roots (0.3 %) (Fig. 2f). The additional 3rd or 4th roots will be small and increase the extraction difficulty (Gay-Escoda *et al.*, 2022).

The study revealed that bilateral IL3M tend to have the same root types on both sides (85.8 %), separated or fused. Furthermore, bilateral IL3M with fused roots had similar root forms in 84.9 % of cases, with the straight root being the most common (95.55 %). On the other hand, bilateral IL3M with separated roots had similar root forms only in (44.2 %), and the straight form was the most common, followed by joined roots. A statistically significant

association emerged between sex and roots types of IL3M. Male patients were more likely to have separated roots (60 %), while fused roots were more common among female patients (66 %) (p=.000).

The literature on the frequency of IL3M' angulations has reported different results. Lübbers *et al.* (2011) found that mesial angulation was the main type (40.2 %), followed by vertical (29 %), horizontal (13.9 %), distal (10.2 %), and transverse (6.8 %) positions. da Silva Sampieri *et al.* (2018) found a similar order of frequencies, with mesial angulation being the most common (53.8 %), followed by vertical (23.2 %), horizontal (20.6 %), and distoangular (2.4 %). Vertical angulation was reported by Yilmaz *et al.* (2016) (19) as the most common (53 %), followed by mesioangular (29 %), distoangular (13 %), and horizontal (5 %). The current study revealed that vertical angulation was the most common among IL3M (39.1 %), followed by mesioangular (24.1 %), horizontal (23.2 %), and distoangular (13.5 %).

The study analyzed the relationship between different root forms and Winter classification. The straight form of IL3M with fused roots was frequently associated with vertical angulation (36.9 %), while the least common angulation was distoangular (17.9 %) (Fig. 3a). In the same way, vertical angulation was the most common for the majority of separated roots forms, while distoangular was the least common (Fig. 3b). The IL3M with their roots curved mesial were less common and presented only in 2.5 %; however, this form was mostly associated with horizontal and mesial angulations.

This study investigated the correlation between the roots' forms and Pell & Gregory classifications. Class 2 was the most common ramus classification of Pell & Gregory for both types of IL3M, followed by Class 1 and Class 3 (Figs. 4a,b). Moreover, Class A of occlusion was the most common, followed by class B and Class C (Figs. 4c,d). These results of ramus and occlusal classifications agreed with the study of da Silva Sampieri *et al.* (2018). On the other hand, our results contradicted Yilmaz *et al.* (2016) findings that indicating Class C was the most common (61 %), followed by Class A (20 %) and Class B (19 %).

Surgical extraction of IL3M is a very common procedure in oral surgery (Susarla & Dodson, 2004). The difficulty of surgical extraction was linked by multiple studies to the length of operation time (Barreiro-Torres *et al.*, 2010; Roy *et al.*, 2015; Al-Samman, 2017; Sainz de Baranda *et al.*, 2019). Pederson scale was one of the earliest scales designed to assess extraction difficulty based on Winter and Pell & Gregory classifications. The following situations were regarded as the most challenging for surgical

extraction of IL3M, distal angulation, Class C, and Class 3 (Bali *et al.*, 2013). The modified Parant scale was based on the complexity of the extraction, with difficulty increasing with the sequence of extraction procedures: forceps only, osteotomy, osteotomy with coronal section, or root section (Diniz-Freitas *et al.*, 2007). Other key risk factors determining extraction difficulty are periodontal space and the adjacent second molar, relationship with the mandibular canal, changes in bone density linked with age, and sex (Carvalho & do Egito Vasconcelos, 2011). Gay-Escoda *et al.* (2022) performed a systematic review of the literature and proposed a measure for assessing the surgical difficulties of removing IL3M. The scale took root morphology into account and considered the IL3M with conical fused roots as low extraction difficulty; multi-radicular ( $\geq 2$  roots) as moderate extraction difficulty; then germ, hypercementosis, and dilacerated roots as high extraction difficulty. Nonetheless, the multi-rooted teeth were classified as having a single category of difficulty regardless of whether the roots are straight or curved on one or two roots, the curvature direction is mesial or distal, or even if the roots are connected at the apex. Therefore, new studies are recommended to evaluate the impact of these variations of root morphology on extraction difficulty.

The study created a new categorization that effectively divides the roots of IL3M into types and forms that are observed on panoramic radiographs. Future studies should investigate the prevalence of IL3 M root forms in different nations and races.

## CONCLUSION

The IL3M vary in their root morphology and may present with fused roots or separated roots, which are the most common. Separated and fused roots were frequently straight. The study found a statistically significant association between the root type and the patients' sex. Furthermore, bilateral IL3M tend to have similar root types on both sides.

The new classification is applicable on panoramic radiographs, and complements Winter and Pell & Gregory classifications to provide a better description of the IL3M' status by adding root morphology to the angulation, occlusal height, and relation to the ramus.

---

ABU-MOSTAFA, N. ¿La literatura ha categorizado minuciosamente los terceros molares inferiores? Una nueva clasificación de las diversas formas radicales del tercer molar inferior para una mejor comprensión de su morfología. *Int. J. Morphol.*, 41(1):278-285, 2023.

**RESUMEN:** Los terceros molares inferiores impactados (3MII) tienen diferentes formas y números de raíces. Este estudio tuvo como objetivo crear una clasificación para las formas de raíz 3MII, que debería ayudar a comprender la morfología de las raíces. Realizamos un estudio transversal retrospectivo de pacientes con 3MII en las clínicas universitarias entre 2017 y 2019. Se recuperaron radiografías panorámicas para clasificar las raíces en raíces fusionadas (RF): una o dos raíces conectadas desde la zona de furca a los ápices y raíces separadas (RS): dos o más raíces no conectadas desde la bifurcación al tercio apical, y cada tipo con formas diferentes. El análisis estadístico se realizó mediante la prueba Chi-Cuadrado. Se incluyeron 500 pacientes, hombres (54,6 %) y mujeres (45,4 %). RS se observó en 591 dientes (75,5 %) y RF en 192 dientes (24,5 %). Surgieron asociaciones estadísticamente significativas entre RS y hombres (60 %) y entre RF y mujeres (66 %) ( $p = .000$ ). Las formas de RS eran rectas (45,8 %), raíces unidas (28,2 %), una recta y una curva (13,3 %), raíces curvas distales (9,1 %), raíces curvas mesiales (2,5 %) y más de dos raíces (0,3 %). Las formas RF eran rectas (87,5 %), curvas distales (9,4 %), en forma de S (2,1 %) y curvas mesiales (1 %). Las angulaciones comunes de 3MII con RS fueron verticales (39 %), seguidas de mesioangular (25,7 %), mientras que RF fueron mayoritariamente verticales (39,1 %) u horizontales (23,9 %). La clasificación es aplicable en radiografías panorámicas y complementa a Winter y Pell & Gregory para proporcionar una mejor descripción del estado de 3MII al agregar la morfología de la raíz a la relación de angulación, oclusal y rama.

**PALABRAS CLAVE:** Tercer molar inferior incluido; Morfología de la raíz; Formas de raíz; Raíces fusionadas; Raíces separadas.

## REFERENCES

- Akarslan, Z. Z. & Kocabay, C. Assessment of the associated symptoms, pathologies, positions and angulations of bilateral occurring mandibular third molars: is there any similarity? *Oral Surg. Oral Med. Oral Pathol. Oral Radiol. Endod.*, 108(3):e26-32, 2009.
- Al-Samman, A. A. Evaluation of Kharma scale as a predictor of lower third molar extraction difficulty. *Med. Oral Patol. Oral Cir. Bucal*, 22(6):e796-9, 2017.
- Bali, A.; Bali, D.; Sharma, A. & Verma, G. Is Pederson index a true predictive difficulty index for impacted mandibular third molar surgery? A meta-analysis. *J. Maxillofac. Oral Surg.*, 12(3):359-64, 2013.
- Barreiro-Torres, J.; Diniz-Freitas, M.; Lago-Méndez, L.; Gude-Sampedro, F.; Gándara-Rey, J. M. & García-García, A. Evaluation of the surgical difficulty in lower third molar extraction. *Med. Oral Patol. Oral Cir. Bucal*, 15(6):e869-74, 2010.
- Brasil, D. M.; Nascimento, E. H. L.; Gaêta-Araujo, H.; Oliveira-Santos, C. & Maria de Almeida, S. Is panoramic imaging equivalent to cone-beam computed tomography for classifying impacted lower third molars? *J. Oral Maxillofac. Surg.*, 77(10):1968-74, 2019.
- Carvalho, R. W. F. & do Egito Vasconcelos, B. C. Assessment of factors associated with surgical difficulty during removal of impacted lower third molars. *J. Oral Maxillofac. Surg.*, 69(11):2714-21, 2011.
- da Silva Sampieri, M. B.; Viana, F. L. P.; Cardoso, C. L.; Vasconcelos, M. F.; Vasconcelos, M. H. F. & Gonçalves, E. S. Radiographic study of mandibular third molars: evaluation of the position and root anatomy in Brazilian population. *Oral Maxillofac. Surg.*, 22(2):163-8, 2018.

- Dalili, Z.; Mahjoub, P. & Sigaroudi, A. K. Comparison between cone beam computed tomography and panoramic radiography in the assessment of the relationship between the mandibular canal and impacted class C mandibular third molars. *Dent. Res. J. (Isfahan)*, 8(4):203-10, 2011.
- Diniz-Freitas, M.; Lago-Méndez, L.; Gude-Sampedro, F.; Somoza-Martin, J. M.; Gándara-Rey, J. M. & García-García, A. Pederson scale fails to predict how difficult it will be to extract lower third molars. *Br. J. Oral Maxillofac. Surg.*, 45(1):23-6, 2007.
- Dogan, N.; Orhan, K.; Günaydin, Y.; Köymen, R.; Okçu, K. & Uçok, O. Unerupted mandibular third molars: symptoms; associated pathologies; and indications for removal in a Turkish population. *Quintessence Int.*, 38(8):e497-505, 2007.
- Gay-Escoda, C.; Sánchez-Torres, A.; Borrás-Ferreres, J. & Valmaseda-Castellón, E. Third molar surgical difficulty scales: systematic review and preoperative assessment form. *Med. Oral Patol. Oral Cir. Bucal.*, 27(1):e68-e76, 2022.
- Gbotolorun, O. M.; Arotiba, G. T. & Ladeinde, A. L. Assessment of factors associated with surgical difficulty in impacted mandibular third molar extraction. *J. Oral Maxillofac. Surg.*, 65(10):1977-83, 2007.
- Genú, P. R. & Vasconcelos, B. C. Influence of the tooth section technique in alveolar nerve damage after surgery of impacted lower third molars. *Int. J. Oral Maxillofac. Surg.*, 37(10):923-8, 2008.
- Gulabivala, K.; Aung, T. H.; Alavi, A. & Ng, Y. L. Root and canal morphology of Burmese mandibular molars. *Int. Endod. J.*, 34(5):359-70, 2001.
- Irja, V. Impacted third molars increase the risk for caries and periodontal pathology in neighboring second molars. *J. Evid. Based Dent. Pract.*, 14(2):89-90, 2014.
- Khojastepour, L.; Khaghaninejad, M. S.; Hasanshahi, R.; Forghani, M. & Ahrari, F. Does the Winter or Pell and Gregory classification system indicate the apical position of impacted mandibular third molars? *J. Oral Maxillofac. Surg.*, 77(11):2222.e1-2222.e9, 2019.
- Kuzekanani, M.; Haghani, J. & Nosrati, H. Root and canal morphology of mandibular third molars in an Iranian population. *J. Dent. Res. Dent. Clin. Dent. Prospects.*, 6(3):85-8, 2012.
- Lübbers, H. T.; Matthews, F.; Damerau, G.; Kruse, A. L.; Obwegeser, J. A.; Grätz, K. W. & Eyrich, G. K. Anatomy of impacted lower third molars evaluated by computerized tomography: is there an indication for 3-dimensional imaging? *Oral Surg. Oral Med. Oral Pathol. Oral Radiol. Endod.*, 111(5):547-50, 2011.
- Mohammadi, Z.; Jafarzadeh, H.; Shalavi, S.; Bandi, S. & Patil, S. Root and root canal morphology of human third molar teeth. *J. Contemp. Dent. Pract.*, 16(4):310-3, 2015.
- Peker, I.; Sarikir, C.; Alkurt, M. T. & Zor, Z. F. Panoramic radiography and cone-beam computed tomography findings in preoperative examination of impacted mandibular third molars. *BMC Oral Health*, 14:71, 2014.
- Roy, I.; Baliga, S. D.; Louis, A. & Rao, S. Importance of clinical and radiological parameters in assessment of surgical difficulty in removal of impacted mandibular 3rd molars: a new index. *J. Maxillofac. Oral Surg.*, 14(3):745-9, 2015.
- Sainz de Baranda, B.; Silvestre, F. J. & Silvestre-Rangil, J. Relationship between surgical difficulty of third molar extraction under local anesthesia and the postoperative evolution of clinical and blood parameters. *J. Oral Maxillofac. Surg.*, 77(7):1337-45, 2019.
- Sidow, S. J.; West, L. A.; Liewehr, F. R. & Loushine, R. J. Root canal morphology of human maxillary and mandibular third molars. *J. Endod.*, 26(11):675-8, 2000.
- Susarla, S. M. & Dodson, T. B. Risk factors for third molar extraction difficulty. *J. Oral Maxillofac. Surg.*, 62(11):1363-1371, 2004.
- Yılmaz, S.; Adisen, M. Z.; Misirlioglu, M. & Yorubulut, S. Assessment of third molar impaction pattern and associated clinical symptoms in a Central Anatolian Turkish population. *Med. Princ. Pract.*, 25(2):169-75, 2016.

Corresponding author:  
Dr. Nedal Abu-Mostafa. BDS. MSc.  
Assistant Professor  
Oral and Maxillofacial Surgery and Diagnostic Science  
Department  
Riyadh Elm University  
P.O. Box 84891  
Riyadh 11681  
SAUDI ARABIA

E-mail: nabumostafa@gmail.com  
nedal@riyadh.edu.sa