

# An Experimental Study of Tangzhouling on Morphological Changes of Nissl Bodies in the Dorsal Root Ganglion of DM Rats

Un Estudio Experimental de Tangzhouling sobre los Cambios Morfológicos de los Cuerpos de Nissl en el Ganglio de la Raíz Dorsal de Ratas DM

Jun Li<sup>1</sup>; Jian-Ting Hou<sup>2</sup>; Yan Zhu<sup>2</sup>; Shuo-Miao Li<sup>2</sup>; Yong-Ren Zheng<sup>3</sup>; Zhong-Yi Qian<sup>4</sup> & Yao-Ming Xue<sup>1</sup>

LI, J.; HOU, J. T.; ZHU, Y.; LI, S. M.; ZHENG, Y. R.; QIAN, Z. Y. & XUE, Y. M. An experimental study of Tangzhouling on morphological changes of nissl bodies in the dorsal root ganglion of dm rats. *Int. J. Morphol.*, 40(1):233-241, 2022.

**SUMMARY:** This study aims to investigate the effect of Tangzhouling on the morphological changes of Nissl bodies in the dorsal root ganglion of DM Rats. In this study, 69 rats were randomly divided into a control group (n = 10) and a model group (n = 59). The rats in the model group were randomly divided into a diabetic group (n = 11), a vitamin C group (n = 12), a low dose Tangzhouling group (n = 12), a medium dose Tangzhouling group (n = 12) and a high dose Tangzhouling group (n = 12). The dose of Tangzhouling in the low dose group was 5 times that of the adult dose, being 0.44g/kg/d. The dose of Tangzhouling in the medium dose group was 10 times that of the adult dose, being 0.88g/kg/d. The dose of Tangzhouling in the high dose group was 20 times that of the adult dose, being 1.75g/kg/d. All doses above are crude drug dosages. Rats in the vitamin C group were given 10 times the dose of an adult, being, 0.05 g/kg/d. The diabetic group and the control group were given the same amount of distilled water. Drug delivery time is 16 weeks. The dorsal root ganglion was placed in a freezing tube at the end of the experiment. The morphological changes of Nissl bodies in the dorsal root ganglion were detected by HE and Nissl staining. The study results showed that vitamin C had no significant effect on the quantity, size and nucleolus. Tangzhouling can improve the morphology, quantity and nucleolus of Nissl bodies to a certain extent, and the high dose is better than the lower dose. Tangzhouling capsules can improve the nerve function of DM rats through Nissl bodies.

**KEY WORDS:** Tangzhouling; HE staining; Dorsal root ganglion; diabetic peripheral neuropathy.

## INTRODUCTION

Diabetic peripheral neuropathy (DPN) is one of the most common complications of diabetes. The chronic hyperglycemia state and its physiological and pathological changes can cause peripheral nervous system injury and neuropathy, which is the main cause of disabilities in diabetic patients (Eldabe *et al.*, 2018; Goddard *et al.*, 2018; Iqbal *et al.*, 2018). It easily occurs in the extremities and the trunk, showing mainly in limb numbness, pain, muscle weakness and atrophy, which seriously affect the patient's quality of life (Singh *et al.*, 2017; Rinkel & Coert, 2019). In this study, the morphological changes of Nissl bodies under the action of Tangzhouling were observed under the microscope. The Nissl bodies reflect the function of the ganglion cells. There are few clinical pieces of research related to Tangzhouling.

Therefore, this study plans to investigate the effect of Tangzhouling on the morphological changes of Nissl bodies in the root ganglion of DM rats, so as to provide a certain basis for the action of the drug from a cytology point of view.

## MATERIAL AND METHOD

**Experimental rats and pharmaceutical purchases.** The 8-9-week SPF male SD rats with a body mass of between 220-260 g were purchased from the Yunnan University of Chinese Medicine. Animal License No.: SCXK (Yun) 2015-0001. Tangzhouling capsules (mainly composed of

<sup>1</sup> Department of Endocrinology and Metabolism, Nanfang Hospital, Southern Medical University, Guangzhou 510515, Guangdong, China.

<sup>2</sup> Department of Endocrinology and Metabolism, The Third Affiliated Hospital, Yunnan University of Chinese Medicine, Kunming 650011, Yunnan, China.

<sup>3</sup> Animal Experiment Public Platform, Yunnan University of Chinese Medicine, Kunming 650500, Yunnan, China.

<sup>4</sup> Experimental Teaching Center of Basic Medical College, Kunming Medical University, Kunming 650500, Yunnan, China.

**FUNDING.** This study was supported by Kunming Science and Technology Plan-Key Project [No. 2015-2-S-02003].

Astragalus, pseudo-ginseng and scorpion, etc.), a kind of hospital preparation of the Kunming Municipal Hospital of Traditional Chinese Medicine, are produced by the Drug Manufacturing Room of the Kunming Municipal Hospital of Traditional Chinese Medicine. Vitamin C (VC) was purchased from the Beijing Double-crane Pharmaceutical Co., Ltd., with a dose of 0.1 g/tablet, approval No. of H11021503, and batch No. of 080213. This study was approved by the Ethics Committee of our hospital.

**Establishment of animal models.** After one week of adaptive feeding, the rats were randomly divided into a normal control group and a model group. After fasting for 12 hours before modeling, the rats in the model group were given a one-off left inferior intra-abdominal injection with 0.45 % of STZ solution according to a dose of 60mg/kg body weight, while the rats in the normal control group received the same amount of citrate buffer 0.1 mol/L (60 mg/kg, pH 4.5). After 72 hours, the blood sugar collected from the tip of the tail was measured with a glucose meter. The blood sugar content  $\geq 16.7$  mmol/L was considered as successful modeling.

Random group. In this study, 69 rats were randomly divided into a control group (n = 10) and a model group (59), and 50 DM rats with a successful model were randomly divided into 5 groups: a diabetes mellitus (DM) group, a low dose Tangzhouling (J-small) group, a medium dose Tangzhouling (J-group) group, a high dose Tangzhouling (J-group) group and a vitamin C (VC) group, with 10 rats in each group.

**Drug interventions.** The dose of Tangzhouling in the low dose group was 5 times that of the adult dose, being 0.44 g/kg/day. The dose of Tangzhouling in the medium dose group was 10 times that of the adult dose, being 0.88 g/kg/d. The dose of Tangzhouling in the high dose group was 20 times that of the adult dose, being 1.75 g/kg/d. All the above doses were crude drug dosages. Rats in the vitamin C group were given 10 times the adult dose, being 0.05 g/kg/d. Rats in the diabetic group and the control group were given the same amount of distilled water with a 0.1 mL/kg daily dose of gavage. They were fed for 16 weeks.

**HE staining.** At the end of the experiment, the rats were killed, and the dorsal root ganglion was taken and placed in a freezing tube and stored at  $-8^{\circ}\text{C}$  for molecular biological detection. The specimens were made, and the tissue sections were observed using an Olympus-CX31 optical microscope. The tissue structure, cell components, staining characteristics and pathological changes were observed.

The morphological changes of the dorsal root

ganglion were detected by Nissl staining. At the end of the experiment, the rats were killed, and the dorsal root ganglion was taken and placed in a freezing tube and stored at  $-8^{\circ}\text{C}$  for molecular biological detection. The specimens were made and stained by Nissl staining. The tissue sections were observed under an Olympus-CX31 optical microscope, and the components and changes and staining characteristics of Nissl bodies in the ganglion neurons were observed.

**Statistical analysis.** In this study, SPSS 20.0 statistical software was used to process the data. The measurement data were expressed by mean  $\pm$  standard deviation ( $\bar{x} \pm S$ ). Enumeration data were expressed by percentage (%).  $P < 0.05$  means the difference was statistically significant.

## RESULTS

HE staining results of dorsal root ganglion of rats. Many ganglion cells (neurons) were found in the ganglia of each group. The nuclei were stained blue and the cytoplasm was stained red. Ganglion cells were gathered into a small group, and the ganglion cells were arranged in parallel with nerve fiber bundles mostly located between the nerve fiber bundles. Ganglion cells (neurons) were ovoid, with different sizes. Most large ones were stained lightly and the small ones were stained dark. The nucleus was round, located in the center of the cell body and the nucleolus was obvious. Nissl bodies were stained red and more bluish in the cytoplasm, which was granular.

The results of the HE staining in the normal group showed that the size of neurons was different and the cell membrane was intact. The cytoplasm presented fine grains and stained red and more bluish. The nucleus of the neuron was large and round, the nucleolus was centered and clear. The results of the HE staining in the model group showed that the size of neurons was different and the cell membrane was intact. The cells were stained red and the particles were absent. The nucleus of the neuron was large and round, and the nucleolus was centered and clear. A small number of shrinking neurons were seen. The neurons were separated from the surrounding satellite cells, but the cell membrane was complete, the nucleus was large and round, and the nucleolus was clear. The results of the HE staining in the vitamin C group showed that the size of neurons was different and the cell membrane was intact. The cytoplasm was stained red, and the particles were few or none. The nucleus of the neuron was large and round and the nucleolus was centered and clear. A small number of shrinking neurons were seen. The neurons were separated from the surrounding satellite cells, but the cell membrane was complete, the nucleus was large and round,

and the nucleolus was clear. The HE staining results of the low dose group showed that the membrane was intact. The cytoplasm was stained red, and the particles were few or none. The nucleus of the neuron was large and round, the nucleolus was centered and clear. A small number of shrinking neurons were seen. The neurons were separated from the surrounding satellite cells, but the cell membrane was complete, the nucleus was large and round, and the nucleolus was clear. The results of the HE staining in the medium dose group showed that the size of the neurons was different and the cell membrane was

intact. The cytoplasm was stained red with a lot of particles. The nucleus of the neuron was large and round, the nucleolus was centered and clear. The difference was not significant when compared to the control group. The results of the HE staining in the high dose group showed that the size of the neurons was different and the cell membrane was intact. The cytoplasm was stained red with a lot of particles. The nucleus of the neuron was large and round, the nucleolus was centered and clear. The difference was not significant when compared to the control group (Figs. 1 and 2).

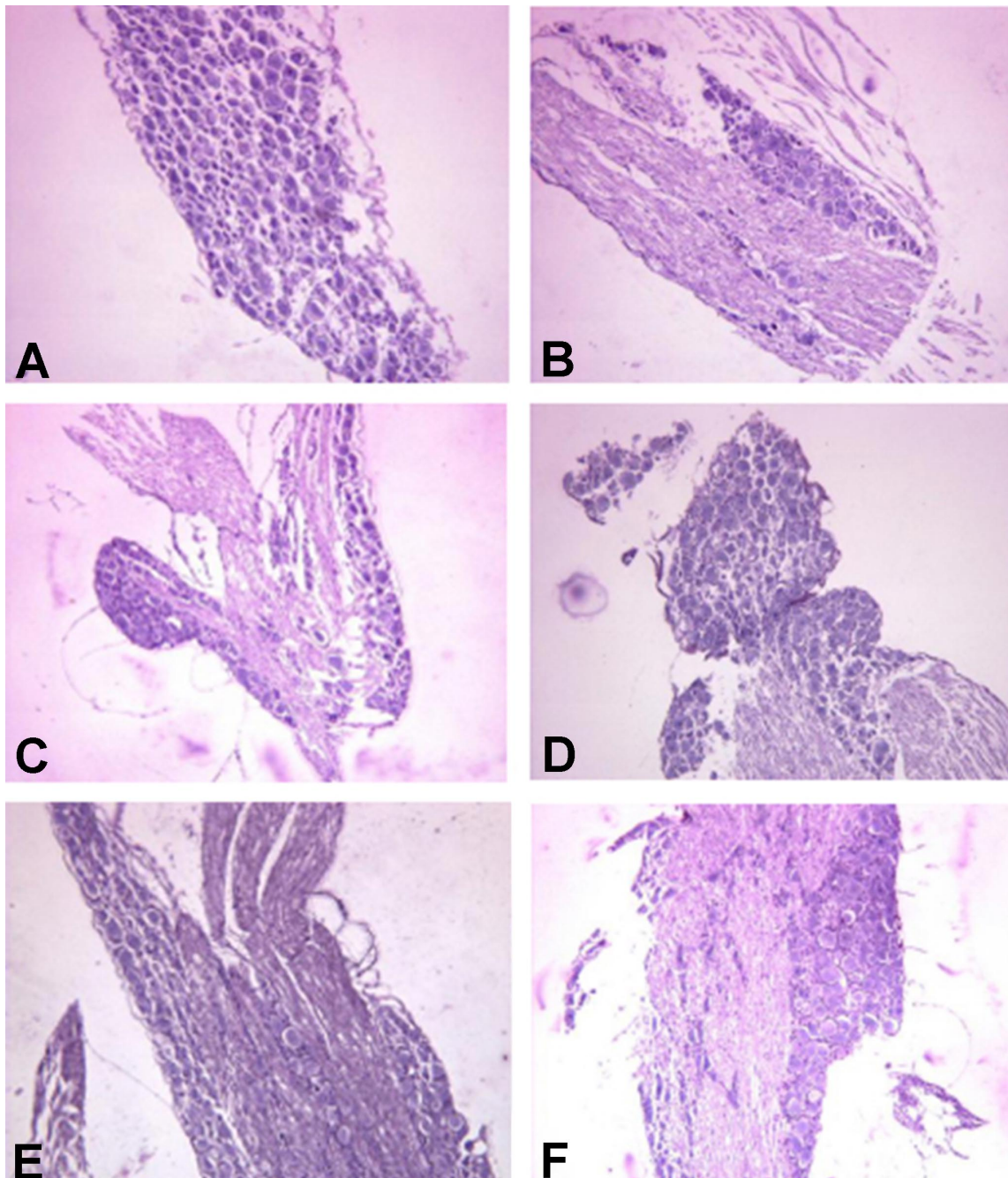


Fig. 1. Results of HE staining in dorsal root ganglion of rats (×100).



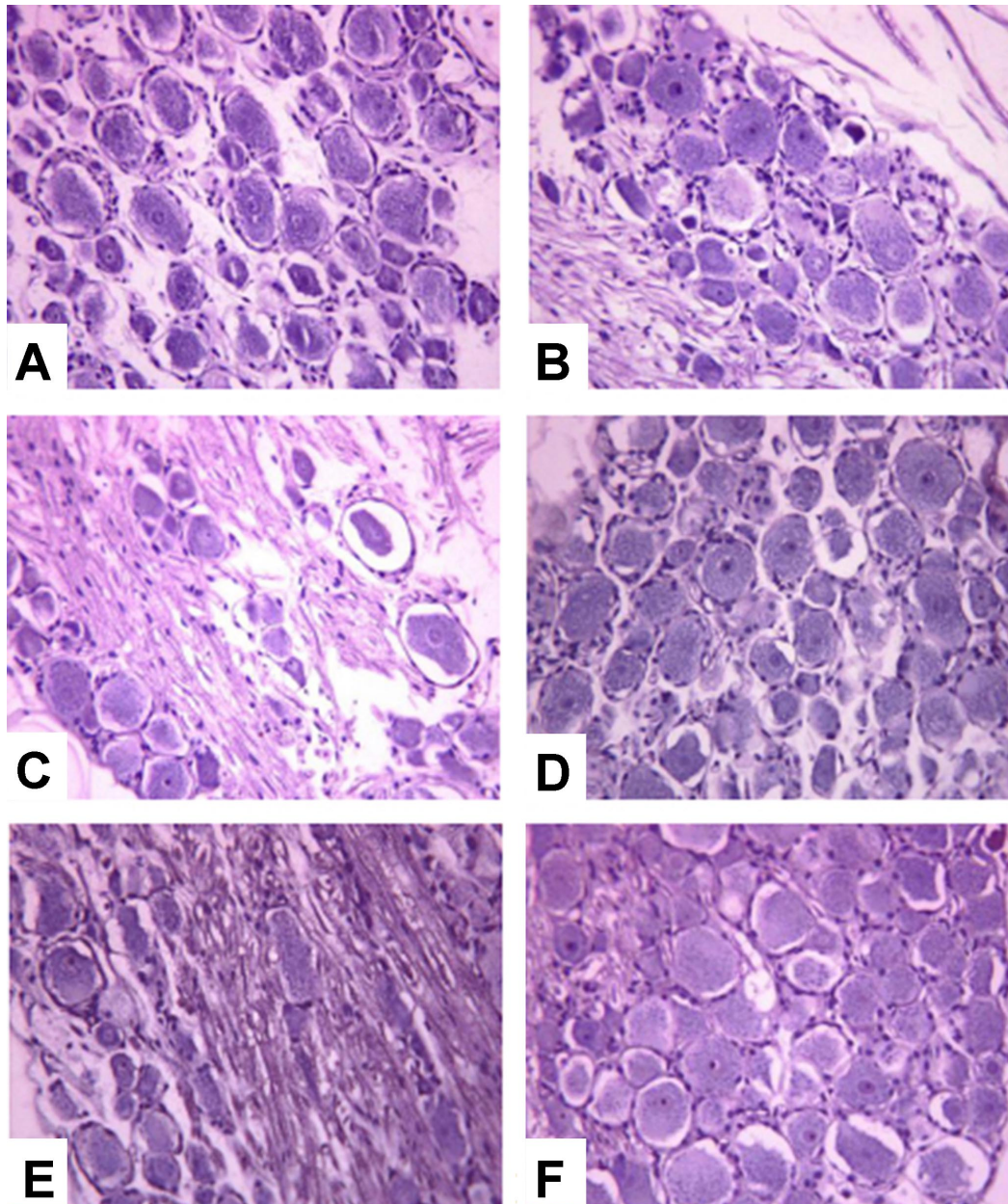


Fig. 2. Results of HE staining in dorsal root ganglion of rats ( $\times 400$ ). A: Normal group; B: Model group; C: Vitamin C group; D: Low dose group; E: Medium dose group; F: High dose group.

The results of morphological changes of Nissl bodies in the dorsal root ganglion of rats. After Nissl staining, the tissue morphology of the rats in each group was observed under a light microscope. It was found that soma of different sizes and polyhedral shapes was gathered in the ganglia, and the Nissl bodies in the cytoplasm and the nucleolus in the nucleus were purple-blue.

In the normal group, the Nissl staining showed that the soma contained a large number of thick and dense Nissl bodies, dark in color, showing large granular or a sheet-like

shape. The neuronal nuclei were large and round, and the nucleolus was centered and clearly visible. Under the high-power field, it could be seen that the number of Nissl particles in the neurons was large and the color was darker. The results of Nissl staining in the model group showed that the Nissl bodies decreased obviously in the soma, the staining became shallower, the grains became smaller, the loss of vacuole-like changes of Nissl bodies in the cytoplasm of part of the soma. In some neurons, the Nissl bodies disappeared, the nucleus shifted, and the nucleolus blurred or disappeared. The results of Nissl staining in the vitamin C group showed

that most of Nissl bodies decreased significantly in the cytoplasm. The area of the non-Nissl body around the nucleus of the neurons was enlarged. The Nissl particles became smaller than those in the normal group, and the loss of vacuole-like changes of Nissl bodies was seen in the cytoplasm of some neurons. The results of Nissl staining in the low dose group showed that Nissl bodies were significantly decreased in the cytoplasm of many neurons. The non-Nissl region was expanded in the nucleus of neurons and the Nissl particles became smaller than those in the normal group. The loss of vacuole-like changes of Nissl bodies

was seen in the cytoplasm of some neurons. However, the number of Nissl in the model group was slightly more than that in the model group. The results of Nissl staining in the medium dose group showed that the morphological changes were also mild. The Nissl decreased slightly in a few ganglion neurons, and the blue-purple Nissl granules were sparse. The results of Nissl staining in the high dose group showed that the morphology was slightly changed, with no obvious loss of Nissl bodies and nuclear changes. Some of them were lighter and smaller, which were similar to those of the normal group (Figs. 3 and 4).

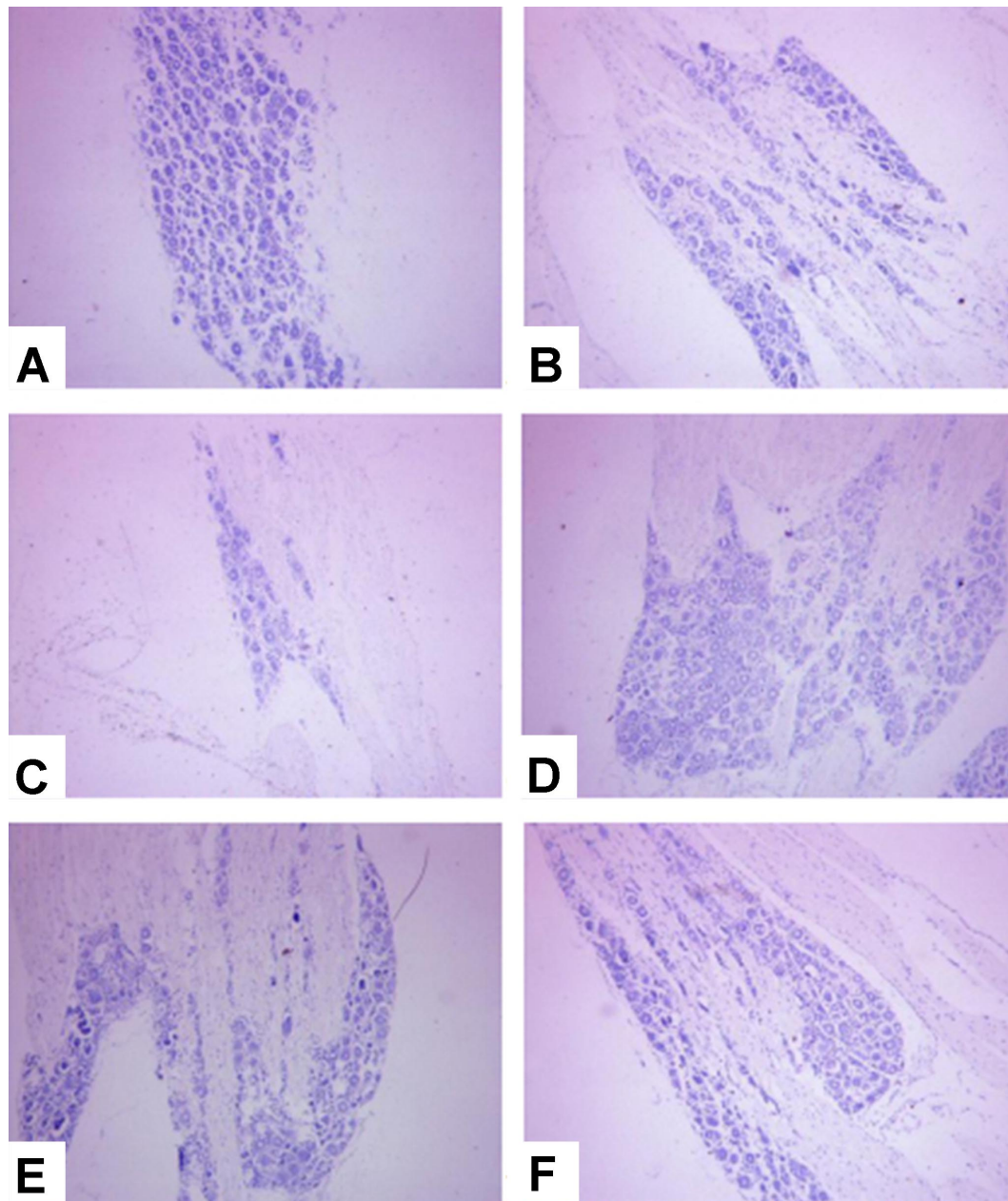


Fig. 3. The morphological changes of Nissl bodies in dorsal root ganglia of rats were found by Nissl staining ( $\times 100$ ).



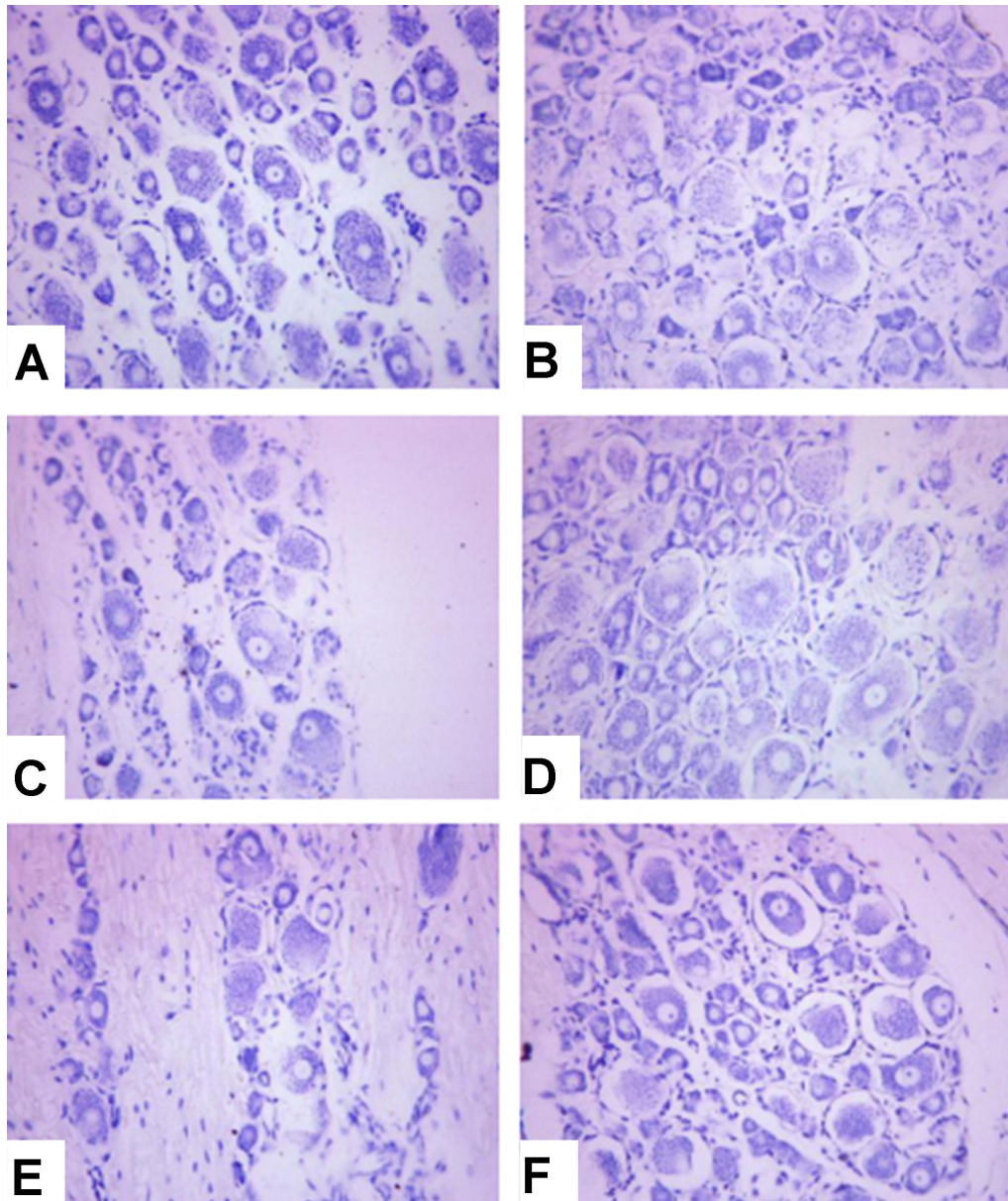


Fig. 4. The morphological changes of Nissl bodies in dorsal root ganglia of rats were found by Nissl staining ( $\times 400$ ). A: Normal group; B: Model group; C: Vitamin C group; D: Low dose group; E: Medium dose group; F: High dose group.

## DISCUSSION

This study's results showed that vitamin C had no significant effect on the quantity, size and nucleolus. Tangzhouling can improve the morphology, quantity and nucleolus of Nissl bodies to a certain extent, and the high dose is better than a lower dose.

Pathological changes are the basis of disease lesions, which can explain the causes, principle and structure of

diseases, as well as metabolic changes. It can intuitively observe the morphological changes, therefore, it has a great value for the diagnosis of disease. In this study, HE and Nissl staining were used to observe the rat dorsal root ganglion cells. HE staining displays the characteristics of various cell components and the general morphological structure of the lesion based on the different affinity of the different components of the cells on the hematoxylin-eosin, and the

different color. Nissl staining is a suggested staining method for the discovery of neuronal cell bodies with basic dye (Kádár *et al.*, 2009; Magnain *et al.*, 2014). Basophilic particles in the cytoplasm could also be observed by hematoxylin-eosin staining. However, the structure and Nissl axons are not as clear as Nissl staining. Therefore, it is necessary to compare and confirm the two kinds of staining methods to reduce errors.

A large number of Nissl bodies existed in the cytoplasm of nerve cells and distributed in where more developed rough endoplasmic reticulum, free ribosome, microfilament, neurofilament and microtubule and Golgi complex, etc. exist. It is the structural proteins needed to synthesize and renew the organelles, the neuromodulator of enzymes and peptides needed for the synthesis of neurotransmitters. The shape, number and distribution vary from neurons to neurons (Scharrer *et al.*, 1945; Da Silva *et al.*, 2017; Shintaku *et al.*, 2018). Nissl bodies are particularly rich in highly metabolically functional neurons. When neurons are damaged or overtired, the Nissl bodies can be reduced, disintegrated or can even disappear (Ajibade *et al.*, 2009; Dziewulska *et al.*, 2013). During the course of an injury or fatigue recovery, the Nissl bodies reappear, increase, and can reach a normal level. Proteins are continuously consumed in the process of the excitatory conduction of neurons, and Nissl bodies can synthesize new proteins to supplement protein consumption. Therefore, Nissl bodies can be used as a marker of the functional state of neurons. After Nissl staining, the ganglion tissues of the rats in each group were observed under a light microscope. It could be seen that there was polygonal soma in different sizes in the ganglia. Nissl bodies in different numbers and sizes were seen in the cytoplasm and stained blue-purple. In the normal control group, DRG soma contained a large number of thick and dense Nissl bodies, dark in color, showing as a large granular or a sheet-like shape. The neuronal nuclei were large and round, and the nucleolus was centered and clearly visible. In the diabetic model group, the Nissl bodies decreased obviously, the staining became shallower, the particles became smaller, some of them showed vacuole-like changes, some of them disappeared, the nucleus shifted, and the nucleolus blurred or disappeared. The morphological change of Tangzhouling in the large dose group and medium dose group were mild, with no obvious loss of Nissl bodies and nuclear changes, which was close to that of the normal control group and slightly lighter in staining. In the low dose Tangzhouling and vitamin C group, the Nissl bodies around the nucleus were significantly lower, and the particles were smaller than those in the normal group.

The purpose of the present study is to observe the morphology and changes of dorsal root ganglion cells in

rats. They are dilated nodules of the spinal dorsal root near the medial side of intervertebral foramen because of their representativeness. The dorsal root ganglion is composed of concentric sensory fiber cells, which are responsible for receiving all nerve impulses from the body's receptors, including general somatosensory and visceral sensations, and transmitting them to the spinal cord through concentric sensory fibers (Yu *et al.*, 2017; Falowski & Dianna, 2018; Kramer *et al.*, 2018). The diabetic peripheral neuropathy mainly concerns the nerves, and the dorsal root ganglion belongs to a category of the nerve. Therefore, it is of great significance to observe the dorsal root ganglion. The dorsal root ganglion of rats in each group is obtained by observing the dorsal root ganglion cells of each group. After HE staining, the size, position, membrane integrity and plasma staining of the neuronal nucleolus are observed under a light microscope. Compared with the normal group, the cytoplasm is stained red and a lack of granules in the Tangzhouling model group. The neuronal nucleus and nucleolus were the same as the normal group. In addition, a small number of neurons were wrinkled. The neurons were separated from the surrounding satellite cells, but the cell membrane was still intact, and there was no abnormality in the nucleus and nucleolus. Compared with the vitamin C group, the effects of the low dose Tangzhouling group and the vitamin C group was similar. The effects of the high dose and the medium dose was significantly better than that of the vitamin C group. No neuronal shrinkage and granule reduction were found; Comparing the drug group with the model group, the low dose group showed that the cytoplasm was stained red. The granules were minimal or none. A small number of neurons were wrinkled. The neurons were separated from the surrounding satellite cells. However, the difference was significant between the medium dose group and the high dose group. The particles did not decrease, and no neuron wrinkle was found. These results suggest that the low dose group has no obvious effect on the improvement of nerve cells. Hyperglycemia can lead to the shrinkage of neurons and the neurons were separated from the surrounding satellite cells, thereby affecting the nerve function (Hölscher, 2012; Yu *et al.*; Falowski & Dianna). Tangzhouling drugs can repair nerve cells by acting on the antioxidant stress reaction of nerve cells and plays a role by blocking the mechanism of apoptosis. It can repair nerve cells, improve nerve function, and provide a basis for understanding and treatment from the point of view of cells and molecules.

Tangzhouling capsules are a kind of hospital preparation developed by the Endocrinology Department of Kunming Hospital of Traditional Chinese Medicine, which have the effect of "tonifying kidney and activating

blood circulation, warming meridians and dredging collaterals". The prescription contains Pseudo-ginseng, Chinese Angelica root-tip, Scorpion, Astragalus, Caulis Spatholobi, Ligusticum Wallichii, Leech, Achyranthes Bidentata, Pueraria Thomsonii, Rhizoma Corydalis, Notopterygium root and Asarum. Most traditional Chinese medicine has the effect of dilating blood vessels, improving microcirculation, inhibiting platelet aggregation, anti-oxidation, anti-thrombosis, reducing blood viscosity and anti-arteriosclerosis. Its main function is invigorating Qi and nourishing blood, activating blood circulation and dredging collaterals and alleviating pain by expelling wind. After the early acute toxicity test and the study of pharmacokinetics, it is considered that: the drug can obviously improve the motor-sensory nerve conduction velocity in patients with diabetes mellitus; it can improve the conductivity of sciatica in rats with peripheral neuropathy, reduce blood glucose and restore the sensitivity to thermal radiation. It can reduce the damage of sciatica in rats with diabetic peripheral neuropathy. At the same time, it can significantly inhibit thrombus formation and has an analgesic effect in normal rats. In order to investigate the effect of Tangzhouling on the morphological changes of ganglia in the dorsal root ganglia of DM rats, vitamin C has no obvious improvement effect on the number and size of Nissl bodies and nucleolus; Tangzhouling has some effect on improving the shape, size, quantity and nuclei of Nissl bodies. Moreover, the high dose is better than the low dose, which indicates that Tangzhouling capsules play a role in improving Nissl bodies. A series of oxidative stress reactions caused by diabetes mellitus can lead to a decrease of Nissl bodies and the changes of nuclei and nucleolus in neurons. In the present experiment, the changes of Nissl bodies in the control group and the model group are clearly seen under the Nissl staining; Vitamin C had no significant effect on the quantity, size and nucleolus. Tangzhouling can improve the morphology, quantity and nucleolus of Nissl bodies to a certain extent, and the high dose is better than a lower dose. Therefore, it is suggested that Tangzhouling has the effect of improving Nissl bodies, while Nissl bodies are also the synthesis site of functional proteins in nerve cells. This is a marked substance that represents the neuronal function in the soma, which further confirms the effect of Tangzhouling on improving nerve function.

## CONCLUSION

Tangzhouling capsules can improve the nerve function of DM rats by improving the neuronal function of marker-Nissl bodies.

**LI, J.; HOU, J. T.; ZHU, Y.; LI, S. M.; ZHENG, Y. R.; QIAN, Z. Y. & XUE, Y. M.** Un estudio experimental de Tangzhouling sobre los cambios morfológicos de los cuerpos de nissl en el ganglio de la raíz dorsal de ratas DM. *Int. J. Morphol.*, 40(1):233-241, 2022.

**RESUMEN:** Este estudio tuvo como objetivo investigar el efecto de Tangzhouling en los cambios morfológicos de los cuerpos de Nissl en el ganglio de la raíz dorsal de las ratas DM. En este estudio, 69 ratas se dividieron aleatoriamente en un grupo control (n = 10) y un grupo modelo (n = 59). Las ratas del grupo modelo se dividieron aleatoriamente en un grupo diabéticos (n = 11), un grupo vitamina C (n = 12), un grupo de dosis baja de Tangzhouling (n = 12), un grupo de dosis media de Tangzhouling (n = 12) y un grupo de dosis alta de Tangzhouling (n = 12). La dosis de Tangzhouling en el grupo de dosis baja fue 5 veces mayor que la dosis del adulto, siendo 0,44 g/kg/d. La dosis de Tangzhouling en el grupo de dosis media fue 10 veces mayor que la dosis del adulto, siendo 0,88 g/kg/d. La dosis de Tangzhouling en el grupo de dosis alta fue 20 veces mayor que la dosis del adulto, siendo 1,75 g/kg/d. Todas las dosis anteriores son dosis de fármaco crudo. Se les administró 10 veces la dosis de un adulto a las ratas del grupo vitamina C, siendo 0,05 g/kg/d. El grupo de diabéticos y el grupo de control recibieron la misma cantidad de agua destilada. El tiempo de entrega del fármaco fue de 16 semanas. El ganglio de la raíz dorsal se colocó en un tubo de congelación al final del experimento. Los cambios morfológicos de los cuerpos de Nissl en el ganglio de la raíz dorsal se detectaron mediante tinción de HE y Nissl. Los resultados del estudio mostraron que la vitamina C no tuvo un efecto significativo sobre la cantidad, el tamaño y el nucléolo. Tangzhouling puede mejorar la morfología, la cantidad y el nucléolo de los cuerpos de Nissl hasta cierto punto, y es mejor la dosis alta que la dosis baja. Las cápsulas de Tangzhouling pueden mejorar la función nerviosa de las ratas DM a través de los cuerpos de Nissl.

**PALABRAS CLAVE:** Tangzhouling; Tinción HE; Ganglio de la raíz dorsal; Neuropatía diabética periférica.

## REFERENCES

- Ajibade, A. J.; Adeeyo, O. A.; Ofusori, D. A.; Adenowo, T. K.; Ishola, O. O.; Ashamu, E. A. & Nwangwu, S. C. Microstructural observations on Nissl substances in the cerebellar cortex of adult Wistar rats following quinine administration. *Trop. J. Pharm. Res.*, 8:105-9, 2009.
- Da Silva, J. T.; Evangelista, B. G.; Venega, R. A. G.; Oliveira, M. E. & Chacur, M. Early and late behavioral changes in sciatic nerve injury may be modulated by nerve growth factor and substance P in rats: a chronic constriction injury long-term evaluation. *J. Biol. Regul. Homeost. Agents*, 31(2):309-19, 2017.
- Dziewulska, D.; Gogol, A.; Gogol, P. & Rafalowska, J. Enlargement of the Nissl substance as a manifestation of early damage to spinal cord motoneurons in amyotrophic lateral sclerosis. *Clin. Neuropathol.*, 32(6):480-5, 2013.
- Eldabe, S.; Espinet, A.; Wahlstedt, A.; Kang, P.; Liem, L.; Patel, N. K.; Vesper, J.; Kimber, A.; Cusack, W. & Kramer, J. Retrospective case series on the treatment of painful diabetic peripheral neuropathy with dorsal root ganglion stimulation. *Neuromodulation*, 21(8):787-92, 2018.



- Falowski, S. M. & Dianna, A. A prospective analysis of neuromonitoring for confirmation of lead placement in dorsal root ganglion stimulation. *Oper. Neurosurg. (Hagerstown)*, 14(6):654-60, 2018.
- Goddard, K.; Vas, P.; Purves, A.; McMillan, V.; Langford, T.; Reid, F. & Edmonds, M. Comparing the diagnostic accuracy of simple tests to screen for diabetic peripheral neuropathy: protocol for a cross-sectional study. *JMIR Res. Protoc.*, 7(4):e72, 2018.
- Hölscher, C. Potential role of glucagon-like peptide-1 (GLP-1) in neuroprotection. *CNS Drugs*, 26(10):871-82, 2012.
- Iqbal, Z.; Azmi, S.; Yadav, R.; Ferdousi, M.; Kumar, M.; Cuthbertson, D. J.; Lim, J.; Malik, R. A. & Alam, U. Diabetic peripheral neuropathy: epidemiology, diagnosis, and pharmacotherapy. *Clin. Ther.*, 40(6):828-49, 2018.
- Kádár, A.; Wittmann, G.; Liposits, Z. & Fekete, C. Improved method for combination of immunocytochemistry and Nissl staining. *J. Neurosci. Methods*, 184(1):115-8, 2009.
- Kramer, J.; Foster, A.; Kent, A. R. & Cusack, W. *Chapter 16 - Fundamentals and Mechanisms of Dorsal Root Ganglion Stimulation*. In: Kramer, E. S.; Peckham, P. H. & Rezai, A. R. (Eds.). *Neuromodulation. Comprehensive Textbook of Principles, Technologies, and Therapies*. 2nd ed. Amsterdam, Elsevier, 2018. pp.179-91.
- Magnain, C.; Augustinack, J. C.; Reuter, M.; Wachinger, C.; Frosch, M. P.; Ragan, T.; Akkin, T.; Wedeen, V. J.; Boas, D. A. & Fischl, B. Blockface histology with optical coherence tomography: a comparison with Nissl staining. *Neuroimage*, 84:524-33, 2014.
- Rinkel, W. D. & Coert, J. H. Two-point discrimination predicts pain relief after lower limb nerve decompression for painful diabetic peripheral neuropathy. *Plast. Reconstr. Surg.*, 143(2):446e-447e, 2019.
- Scharrer, E.; Palay, S. L. & Nilges, R. G. Neurosecretion. VIII. The nissl substance in secreting nerve cells. *Anat. Rec. (Hoboken)*, 92:23-31, 1945.
- Shintaku, M.; Kaneda, D. & Oyanagi, K. Atypical lower motor neuron disease with enlargement of Nissl substance: Report of an autopsy case. *Clin. Neuropathol.*, 37(2):74-81, 2018.
- Singh, K.; Gupta, K. & Kaur, S. High resolution ultrasonography of the tibial nerve in diabetic peripheral neuropathy. *J. Ultrason.*, 17(71):246-52, 2017.
- Yu, J. W.; Huang, J. H.; Lü, K. L.; Zhou, M. K.; Feng, X.; Tian, K.; Zhuang, J. T.; Zhou, W. L.; Deng, C. H. & Tu, X. A. Expressions of TRPV1 and TRPA1 in the dorsal root ganglion in the rat model of orchialgia. *Zhonghua Nan Ke Xue*, 23(4):296-301, 2017.

Corresponding author:

Yao-Ming Xue  
Department of Endocrinology and Metabolism  
Nanfang Hospital of Southern Medical University  
No. 1838, Guangzhou Avenue North  
Guangzhou 510515  
Guangdong  
CHINA

E-mail: xueyao ming1240@163.com