

Efficiency and Safety of Umbilical Cord Mesenchymal Stromal/ Stem Cells in Multiple Sclerosis Combined Treatment

Eficacia y Seguridad de las Células Madre / Estromales Mesenquimales del Cordón Umbilical en el Tratamiento Combinado de la Esclerosis Múltiple

Taras Petriv^{1,2,3}; Michael Tatarchuk¹; Oksana Rybachuk^{2,4}; Yulia Tsymbaliuk¹; Yaroslav Tsymbaliyk¹ & Vitaliy Tsymbaliuk⁵

PETRIV, T.; TATARCHUK, M.; RYBACHUK, O.; TSYMBALIUK, Y.; TSYMBALIYK, Y. & TSYMBALIUK, V. Efficiency and safety of umbilical cord mesenchymal stromal/stem cells in multiple sclerosis combined treatment. *Int. J. Morphol.*, 40(1):143-147, 2022.

SUMMARY: Multiple sclerosis is a demyelinating disease of the nervous system that affects young people of working age and quickly leads to disability. Treatment of this pathology with umbilical cord mesenchymal stem cells is promising, given their immunomodulatory and neurotrophic properties. The study involved 27 patients diagnosed with multiple sclerosis, 12 of whom underwent combined treatment (intravenous and intrathecal administration) of umbilical cord multipotent mesenchymal stromal/stem cells. The effectiveness of treatment was determined by the degree of neurological deficit and spasticity. Combined treatment with umbilical cord mesenchymal stem cells significantly improves the condition of patients with multiple sclerosis and promotes the regression of neurological deficits and spasticity. This treatment is safe, but for a deeper study, it is necessary to continue research in this area.

KEY WORDS. Multipotent mesenchymal stem/stromal cells; Multiple sclerosis; Safety.

INTRODUCTION

Multiple sclerosis is a demyelinating disease of the central nervous system, which has a multifactorial etiology and pathogenesis and is accompanied by rapid disability of patients, mostly young working age (Abi Chahine & Lu, 2020; Baecher-Allan *et al.*, 2018). The etiology of MS is considered as the influence of adverse environmental factors in the genetic predisposition of the organism (defects of the leukocyte antigen system, HLA) (Beeravolu *et al.*, 2017). Such adverse factors may be: viral or bacterial infection, insufficient insolation and vitamin D deficiency (Canto & Oksenberg, 2018, Cheng *et al.*, 2019, Feige *et al.*, 2020). In the pathogenesis of MS the leading place belongs to immunopathological reactions in the form of imbalance between subpopulations of T lymphocytes and disorders in the complement system, accumulation of proinflammatory mediators, followed by the process of axonal degeneration,

apoptosis of glia cells. The result is a persistent neurological deficit (Fernández *et al.*, 2018). Remyelination processes occur when the patient has a clinically remitting type of disease, and in comparison, with demyelination processes are much weaker (Gugliandolo *et al.*, 2020). Due to the complexity of the pathogenesis and multifactorial etiology, there is also no single effective approach in the treatment of MS. One of the promising approaches in the treatment of MS is the use of mesenchymal/stromal stem cells (MSCs) of various origins (Mansoor *et al.*, 2019; Lubetzki *et al.*, 2020). The expediency of this approach is substantiated by a number of experimental works (Ranjbaran *et al.*, 2018; Marrodan *et al.*, 2019), as well as clinical studies that indicate the safety of MS treatment with MSCs (Riordan *et al.*, 2018; Solomon, 2019; Tarlinton *et al.*, 2020). The issues of clinical effect and dynamics of neurological deficit in the combined

¹ The State Institution Romodanov Neurosurgery Institute National Academy of Medical Sciences of Ukraine, Restorative Neurosurgery Department, Kyiv, Ukraine.

² LLC "Medical Biotechnology Company" Hemafund", Kyiv Ukraine.

³ QR Health Solutions, Kyiv, Ukraine.

⁴ Bogomoletz Institute of Physiology of National Academy of Sciences of Ukraine, Kyiv, Ukraine.

⁵ National Academy of Medical Sciences of Ukraine, Kyiv, Ukraine.

use of stem cells in patients with MS remain unresolved. The most optimal source of MSC is the umbilical cord, as these cells are «younger», and they do not have the same number of mutations as in the MSC of the adult body (Uccelli *et al.*, 2019; Zeydan & Kantarci, 2020). The use of autologous MSCs in patients with autoimmune diseases is a debatable issue, as they are also defective, do not exhibit immunomodulatory properties relative to the recipient, and the effectiveness of such MSCs is questionable (Toluvani, 2019).

The aim of the study was to investigate efficiency and safety of combined umbilical cord multipotent mesenchymal stromal/stem cells treatment of multiple sclerosis.

MATERIAL AND METHOD

The study was performed on the basis of the Reconstructive neurosurgery department with X-ray surgery, State Institution "Romodanov Neurosurgery Institute of NAMS of Ukraine" in the frame of scientific research work "To investigate the effectiveness of regenerative cell technologies in the neurosurgical treatment of patients with demyelinating diseases of the CNS and cerebral palsy. ? 0119U000112" The study was approved at a meeting of the Committee on Bioethics of the State Institution "Romodanov neurosurgery institute of NAMS of Ukraine" ?1 from 17.01.20. Informed consent to participate in the study was signed with all patients. Criteria for inclusion of patients in the study: 1) age of patients 18-55 years; 2) verified diagnosis of MS according to McDonald's criteria (2010); 3) the number of points on the EDSS scale from 1 to 7.5, the deterioration of neurological status > 1 point on the EDSS scale during the last year, indicating the progression of the disease; 4) lack of effect from treatment with disease-modifying drugs; 5) no fact of treatment with monoclonal antibodies; 6) signed Informed consent to participate in the study. Criteria for non-inclusion of patients in the study: 1) pregnancy; 2) contractures in the limbs; 3) severe concomitant somatic pathology (heart failure according to NYHA III-IV centuries, myocardial infarction, renal failure (glomerular filtration rate ≤ 59 ml/min), cachexia); 4) acute infectious process (body T ≥ 37.2 °C), positive PCR test for COVID-19; 4) mental disorders; 5) malignant neoplasms.

UC-MSCs isolation, cultivation and phenotyping protocol. UC-MSCs for this study were prepared by LLC "Medical Biotechnology Company" Hemafund" within the framework of the agreement on scientific and practical

cooperation dated 05.11.19. Umbilical cords were obtained from healthy full-term infants after signing informed consent with parents.

Umbilical cords (n=3) were stored under aseptic conditions (no more than 2 days) at 4° C in sterile physiological saline (PS; 0.9 % w/v sodium chloride) until processing. To isolate UC-MSCs, the umbilical cord was placed in sterile Petri dishes and washed with PS supplemented with a 5 % antibiotic-antimycotic solution (Sigma, USA).

The umbilical cord tissue was cleaned of blood clots and cut into pieces or explants, approximately 1–1,5 cm. Then, the explants were placed on the 75 cm² culture flasks (1-2 explants per flask), and the culture medium was added to each flask. The cultural medium was consisting: Dulbecco's Modified Eagle's Medium/Nutrient Mixture F-12 Ham (DMEM-F12; Gibco) containing 5 % fetal bovine serum (Capricorn; Germany), 2 mm L-glutamine (Capricorn; Germany) and 1 µg/ml amphotericin (Capricorn; Germany). Explants/cells were cultured for 2-3 weeks with a culture medium, which change every 2-3 days and in a humid CO₂-incubator with 5 % CO₂ in the air at +37 °C.

After 8 days, the tissue was inspected under phase contrast light microscope to monitor cell migration. Cells were first passaged at the 80 % confluency of the monolayer; to achieve this, cells have been detached from the surface of the flask with 0.05 % Trypsin-EDTA (Sigma; USA) and transferred to the 175 cm² culture flasks for seeding at 4-5x10³cells/cm² density and cultivated for another 2-3 passage.

The MSCs derived from umbilical cord displayed typical fibroblastic morphology (Fig.1, A, B). For administration, 2nd (Fig.1, B) or 3rd passage UC-MSC were used. Percentage of viable UC-MSCs in the cell suspension estimated by flowmetry was 93.93 % \pm 0.79 % (n=3). UC-MSCs, isolated from human umbilical cord, were analysed for surface marker expression profile at passage 2nd of CD34, CD45, CD19, HLA-DR, CD73, CD90 and CD105. Cultured MSCs are known to be strongly positive for the expression of CD73 (99.53 % \pm 0.13 %), CD90 (99.80 % \pm 0.06 %) and CD105 (99.53 % \pm 0.23 %) and negative for the expression of CD34 (0 %), CD45 (0.0 %), CD19 (0 %) and HLA-DR (0.01 % \pm 0.01 %). Due to the minimal criteria established by the Mesenchymal and Tissue Stem Cell Committee of International Society for Cellular Therapy.

UCMSC were also tested for differentiation into adipocytes, chondroblasts, and osteoblasts in vitro using stained with oil red, alcian blue and alizarin red, respectively.

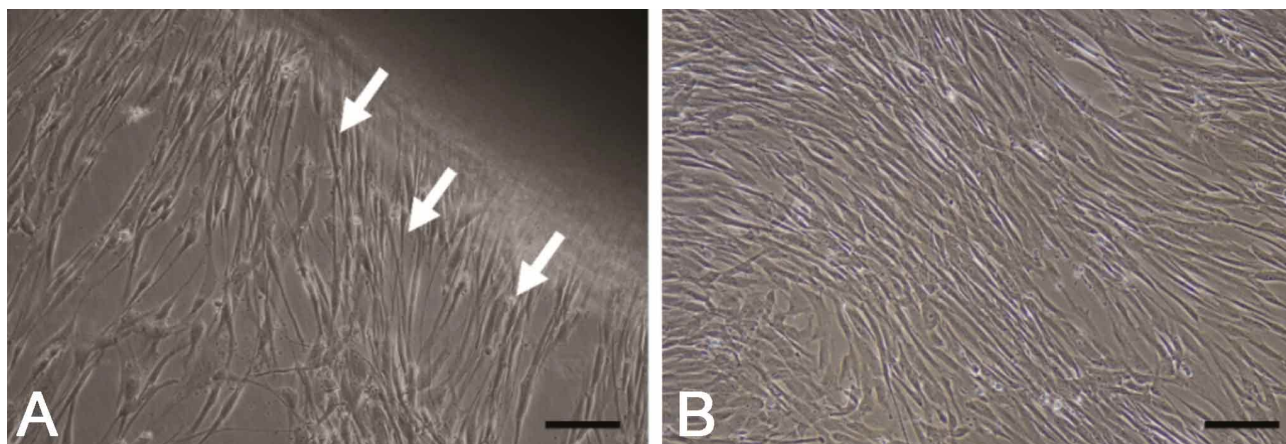


Fig. 1. Phase contrast image of MSCs emerging from an umbilical cord tissue piece explant. (A) The morphology of UC-MSCs from passage 0; eviction of cells from the explant - white arrows. Scale bar 100µm. (B) The morphology of UC-MSCs from passage 2nd. Scale bar 100 µm.

Treatment protocol. All patients (n = 27) underwent a general examination, as well as a set of laboratory and instrumental examinations, which included: general blood test, general urine test, biochemical blood test (glucose, bilirubin, urea, creatinine, ALT, AST, cholesterol), immunogram with determination of the level of neuroautoantibodies, MRI of the brain and cervical spine with contrast enhancement, electroencephalography (EEG), electroneuromyography (ENMG) with transcranial magnetic stimulation (TMS), visual evoked potentials, special consultations. Patients were divided into two groups. According to the type of clinical course in group 1, 9 patients were diagnosed with a progressive-relapsing (75 %) type of disease, and 3 with a primary progressive (25 %). The mean age of patients in group 1 was 35.25 ± 13.72 years. Patients in group 1 (n = 12) were treated with cultured umbilical cord mesenchymal stem cells (UC-MSCs), with the quality characteristics below. Patients in group 1 received a total dose of UC-MSCs at the rate of 1×10^6 / kg body weight once, of which 20×10^6 was administered intrathecally, and the rest of the material intravenously. Intrathecal administration was performed according to the typical method of performing lumbar puncture in compliance with the rules of asepsis and antiseptics in the manipulation room using local anesthesia. Previously, the comparison group was group 2 (n = 15), whose patients were treated according to the Multiple Sclerosis Treatment Protocol. The mean age of patients in group 2 was 39.8 ± 10.23 years. According to the type of clinical course, 12 patients had a progressive-relapsing type of course (80 %), 2 - primary-progressive (13.4 %), 1 - secondary-progressive (6.6 %). Criteria for inclusion and non-inclusion in the study are given above. The key observation points were: 1 month, 6 months, 1 year. The starting point of the observation period was considered to be the day of UC-MSCs administration. Re-introduction of

UC-MSCs was performed 6 months after the first procedure, after a follow-up examination.

Objective assessment of the clinical condition of patients was performed on the extended scale of assessment of the degree of disability according to Kurtzke - Expanded Disability Status Scale (EDSS)). Spasticity was assessed on the Ashworth scale.

Statistical data processing. STATISTICA 10.0 software package with licensed software was used for statistical data processing. The reliability of the difference between the indicators was determined using Student's t test. The value of $p < 0.05$ was considered statistically significant.

RESULTS AND DISCUSSION

The mean age of patients in group 1 was 35.25 ± 13.72 . In group 2 - 39.8 ± 10.23 . The average duration of the disease at the time of hospitalization in the department in patients of both groups (n = 27) was 6.8 years. The predominant number of patients were women. In group 1, the ratio of women: men were 8: 4, in group 2 - 9: 6. The mean EDSS in group 1 was 5.583 ± 1.346 when hospitalized. 1 month after UC-MSCs treatment, no statistically significant dynamics of EDSS was observed, which was 5.375 ± 1.245 ($p = 0.169$). Significant positive dynamics on the EDSS scale was observed 6 months after treatment - 4.583 ± 0.973 , compared with the value before treatment ($p = 0.024$) and 1 month after treatment ($p = 0.031$). There was also a significant difference in the value of EDSS 1 year after the first treatment of UC-MSCs 4.208 ± 0.891 , compared with pre-treatment ($p = 0.003$), as well as with

indicators after 1 month ($p = 0.003$) and 6 months ($p = 0.0007$). In group 2, the mean EDSS score before treatment was 5.8 ± 1.293 . After 1 month, the indicator was 5.433 ± 1.163 ($p = 0.011$), after 6 months - 5.567 ± 0.799 ($p = 0.278$), after 1 year - 5.6 ± 0.91 ($p = 0.239$). There was no statistically significant difference in the dynamics under the influence of the treatment. When comparing groups 1 and 2, no statistically significant difference was found between the EDSS index at hospitalization ($p = 0.337$) and 1 month after treatment with UC-MSCs ($p = 0.485$). The difference between the groups was observed at 6 weeks after treatment ($p = 0.003$) and after 1 year ($p = 0.0002$).

When assessing spasticity in patients in group 1, the mean value on the Ashworth scale before treatment was 1.75. In the dynamics, 1 month after the administration of UC-MSCs, the average value on the scale was 1.41 and was statistically insignificant ($p = 0.317$). Positive dynamics was detected after 6 months, similar to the dynamics of the neurological deficit on the EDSS scale. Compared with the first month of follow-up, the mean spasticity score was 1, and the difference was statistically significant compared to pre-treatment ($p = 0.008$). 1 year after the first injection of UC-MSCs and 6 months after the second, there was a further

decrease in spasticity, the average value was 0.83 ($p = 0.001$). When assessing spasticity in patients in group 2, the mean value on the Ashworth scale before treatment was 1.8. 1 month after treatment (muscle relaxants), the mean value on a scale was 1.54 and was statistically significant ($p = 0.02$). After 6 months, compared with the first month of follow-up, the mean score of spasticity in group 2 was 1, and the difference was statistically insignificant compared to pre-treatment ($p = 0.066$). 1 year after treatment, there was no decrease in spasticity, the average value was 1 ($p = 0.063$) (Fig. 2).

In comparison with the rate of spasticity in the two groups of patients at different time intervals, no difference before treatment was found ($p = 0.468$) (Fig. 3). After the first month of treatment in the 2 groups, the difference was not statistically significant ($p = 0.426$). After 6 months, no statistically significant difference between the groups was found ($p = 0.5$). The reduction in spasticity, which was statistically significant, was observed after 1 year in favor of group 1, after the first application of UC-MSCs ($p = 0.04$). The results indicate no improvement in neurological status in the first month after treatment of patients with UC-MSCs. The positive effect was observed for 6 months after treatment and continued to increase in dynamics up to 1 year. This suggests

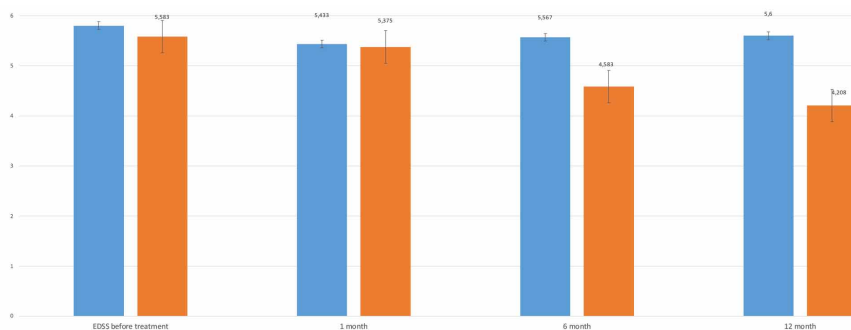


Fig. 2. Dynamics of EDSS in patients with MS.

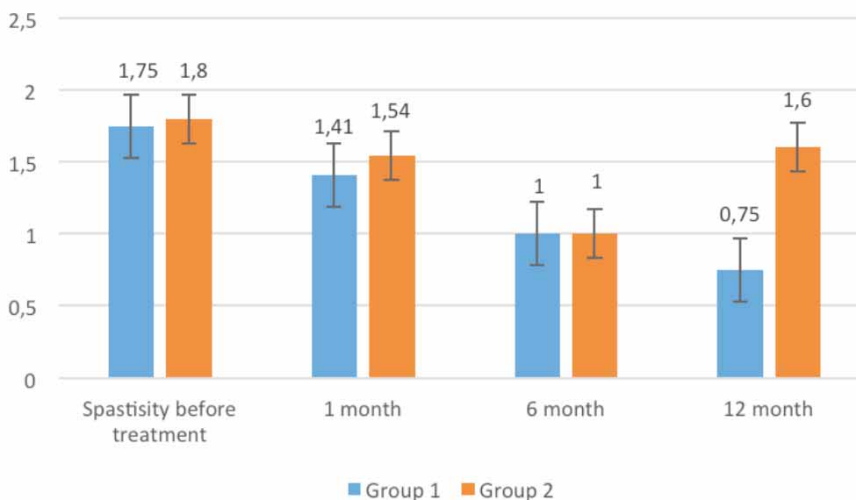


Fig. 3. Dynamics of spasticity on the Ashworth scale in patients with MS.

the need to extend the observation period, and determine the effectiveness of UC-MSCs in the remote period. The regression of spasticity occurs a little later, after 6 months the difference in group 1 (according to the Ashworth scale) in the dynamics is not statistically significant. A significant reduction in spasticity was observed at the time point corresponding to 1 year after the first application and 6 months after the second application. The obtained data are consistent with the data of other authors (Toluvani; Tarlinton *et al.*), regarding the peculiarities of the effect of UC-MSCs on the course of the autoimmune process, which is probably due to the immunomodulatory effect. In group 1, 4 of 12 (34 %) patients had a headache after the procedure, which was alleviated by taking nonsteroidal anti-inflammatory drugs and passed completely after 8-12 hours. In 3 (25 %) patients a rise in body temperature to 38.6°C was recorded, which was also acquired by symptomatic therapy. Among other reactions after MSC administration, general

weakness was observed in the first week after treatment in 8 of 12 (67 %) patients who underwent no specific treatment. The data obtained allow us to speak about the safety of the procedure and the need for research on large groups of patients. The main disadvantages of this study are the small sample of patients and the relatively short observation time. However, monitoring of patients continues to determine the long-term effects and sustainability of the positive effect.

CONCLUSIONS

Combined treatment with umbilical cord mesenchymal stem cells significantly improves the condition of patients with multiple sclerosis and contributes to the regression of neurological deficits. 2. Umbilical cord mesenchymal stem cells significantly reduce spasticity and improve motor function in multiple sclerosis. 3. Treatment with UC-MSc is safe, and reactions after their use are short-lived and do not require specific therapy.

PETRIV, T.; TATARCHUK, M.; RYBACHUK, O.; TSYMBALIUK, Y.; TSYMBALIYK, Y.; TSYMBALIUK, V. Eficacia y seguridad de las células madre / estromales mesenquimales del cordón umbilical en el tratamiento combinado de la esclerosis múltiple. *Int. J. Morphol.*, 40 (1):143-147, 2022.

RESUMEN: La esclerosis múltiple es una enfermedad desmielinizante del sistema nervioso que afecta a los jóvenes en edad laboral y conduce rápidamente a la discapacidad. El tratamiento de esta patología con células madre mesenquimales de cordón umbilical es prometedor, debido a sus propiedades inmunomoduladoras y neurotróficas. En el estudio participaron 27 pacientes diagnosticados de esclerosis múltiple, 12 de los cuales fueron sometidos a un tratamiento combinado (administración intravenosa e intratecal) de células madre / estromales mesenquimales multipotentes del cordón umbilical. La efectividad del tratamiento estuvo determinada por el grado de déficit neurológico y espasticidad. El tratamiento combinado con células madre mesenquimales del cordón umbilical mejora significativamente la condición de los pacientes con esclerosis múltiple y promueve la regresión de los déficits neurológicos y la espasticidad. Este tratamiento es seguro, sin embargo, es necesario continuar investigando en esta área.

PALABRAS CLAVE: Células madre / estromales mesenquimales multipotentes; Esclerosis múltiple; Seguridad.

REFERENCES

Abi Chahine, N. & Lu, P. Stem cells therapy for multiple sclerosis. *Adv. Exp. Med. Biol.*, 1266:99-115, 2020.
Baecher-Allan, C.; Kaskow, B. J. & Weiner, H. L. Multiple sclerosis: mechanisms and immunotherapy. *Neuron*, 97(4):742-68, 2018

Beeravolu, N.; McKee, C.; Alamri, A.; Mikhael, S.; Brown, C.; Perez-Cruet, M. & Chaudhry, G. R. Isolation and characterization of mesenchymal stromal cells from human umbilical cord and fetal placenta. *J. Vis. Exp.*, (122):55224, 2017.
Canto, E. & Oksenberg, J. R. Multiple sclerosis genetics. *Mult. Scler. J.*, 24(1):75-9, 2018.
Cheng, R. J.; Xiong, A. J.; Li, Y. H.; Pan, S. Y.; Zhang, Q. P.; Zhao, Y.; Liu, Y. & Marion, T. N. Mesenchymal Stem Cells: Allogeneic MSC may be immunosuppressive but autologous MSC are dysfunctional in lupus patients. *Front. Cell Dev. Biol.*, 7:285, 2019.
Feige, J.; Moser, T.; Bieler, L.; Schwenker, K.; Hauer, L. & Sellner, J. Vitamin D Supplementation in multiple sclerosis: a critical analysis of potentials and threats. *Nutrients*, 12(3):783, 2020.
Fernández, O.; Izquierdo, G.; Fernández, V.; Leyva, L.; Reyes, V.; Guerrero, M.; León, A.; Arnaiz, C.; Navarro, G.; Páramo, M. D.; *et al.* Adipose-derived mesenchymal stem cells (AdMSC) for the treatment of secondary-progressive multiple sclerosis: A triple blinded, placebo controlled, randomized phase I/II safety and feasibility study. *PLoS One*, 13(5):e0195891, 2018.
Gugliandolo, A.; Bramanti, P. & Mazzon, E. Mesenchymal Stem Cells in multiple sclerosis: recent evidence from pre-clinical to clinical studies. *Int. J. Mol. Sci.*, 21(22):8662, 2020.
Lubetzki, C.; Zalc, B.; Williams, A.; Stadelmann, C. & Stankoff, B. Remyelination in multiple sclerosis: from basic science to clinical translation. *Lancet Neurol.*, 19(8):678-88, 2020.
Mansoor, S. R.; Zabihi, E. & Ghasemi-Kasman, M. The potential use of mesenchymal stem cells for the treatment of multiple sclerosis. *Life Sci.*, 235:116830, 2019.
Marrodan, M.; Alessandro, L.; Farez, M. F. & Correale, J. The role of infections in multiple sclerosis. *Mult Scler.*, 25(7):891-901, 2019.
Ranjbaran, H.; Abediankenari, S.; Mohammadi, M.; Jafari, N.; Khalilian, A.; Rahmani, Z.; Momeninezhad Amiri, M. & Ebrahimi, P. Wharton's Jelly Derived-Mesenchymal Stem Cells: isolation and characterization. *Acta Med. Iran.*, 56(1):28-33, 2018.
Riordan, N. H.; Morales, I.; Fernández, G.; Allen, N.; Fearnot, N. E.; Leckrone, M. E.; Markovich, D. J.; Mansfield, D.; Avila, D.; Patel, A. N.; *et al.* Clinical feasibility of umbilical cord tissue-derived mesenchymal stem cells in the treatment of multiple sclerosis. *J. Transl. Med.*, 16(1):57, 2018.
Solomon, A. J. Diagnosis, differential diagnosis, and misdiagnosis of multiple sclerosis. *Continuum (Minneap. Minn.)*, 25(3):611-35, 2019.
Tarlinton, R. E.; Martynova, E.; Rizvanov, A. A.; Khaiboullina, S. & Verma, S. Role of viruses in the pathogenesis of multiple sclerosis. *Viruses*, 12(6):643, 2020
Toluvani, A. S. Surgical Correction of Demyelinating Injuries of the Central Nervous System with the Use of Mesenchymal Stem Cells. Kyiv, AP Romodanov Institute of Neurosurgery, National Academy of Medical Sciences of Ukraine, 2019.
Uccelli, A.; Laroni, A.; Brundin, L.; Clanet, M.; Fernandez, O.; Massood Nabavi, S.; Muraro, P. A.; Oliveri, R. S.; Radue, E. W.; Sellner, J.; *et al.* MEsenchymal StEm cells for Multiple Sclerosis (MESEMS): a randomized, double blind, cross-over phase I/II clinical trial with autologous mesenchymal stem cells for the therapy of multiple sclerosis. *Trials*, 20(1):263, 2019.
Zeydan, B. & Kantarci, O. H. Impact of age on multiple sclerosis disease activity and progression. *Curr. Neurol. Neurosci. Rep.*, 20(7):24, 2020.

Corresponding author:
Taras Petriv, MD, PhD
32 Platona Mayborody St, Kyiv 04050
UKRAINE

orcid.org/0000-0001-9160-8908

E-mail: petrivtaras@gmail.com