

Anatomical Variations of the Dorsalis Pedis Artery in a Thai Population

Variaciones Anatómicas de la Arteria Dorsal del Pie en una Población Tailandesa

Siriwat Thunyacharoen¹; Chollada Mahakkanukrauh¹; Napat Pattayakornkul¹;
Kantapit Meetham¹; Thanapat Charumporn¹ & Pasuk Mahakkanukrauh^{2,3,4}

THUNYACHAROEN, S.; MAHAKKANUKRAUH, C.; PATTAYAKORNKUL, N.; MEETHAM, K.; CHARUMPORN, T. & MAHAKKANUKRAUH, P. Anatomical variations of the dorsalis pedis artery in a Thai population. *Int. J. Morphol.*, 40(1):137-142, 2021.

SUMMARY: The dorsalis pedis artery (DPA) is a vital artery that supplies the foot and ankle area which is clinically important for palpating when taking the pulse. This research was performed on fresh cadaveric dissection of 40 legs by injecting paint into popliteal artery for tracking the dorsalis pedis artery and its branches. The present research revealed that the Thai population has an anatomical variation and different location of the DPA and exact location of DPA for estimating the location of the DPA and may have clinical implications. The statistically descriptive analysis elucidated the distances of the DPA to the lateral malleolus and medial malleolus which were 51.48 ± 7.27 mm and 42.62 ± 11.40 mm, respectively. The distance of the extensor hallucis longus (EHL) to the DPA was 14.29 ± 4.11 mm. The length of the dorsalis pedis artery which measured from artery on intermalleolar line to its dipping in 1st intermetatarsal space to be 122.03 ± 21.07 mm. The arcuate loop which is anastomosis U-loop of lateral tarsal arteries of the DPA was found 55 % in Thais population. There were no statistically significant differences of all parameters between the side and sex in DPA consideration. An understanding of the variations of the anatomical vasculature of DPA is essential for precise clinical assessment because exact anatomical knowledge and location can contribute to the pulse taking and be applied in surgical procedure.

KEY WORDS: Anatomical variation; Dorsalis pedis artery.

INTRODUCTION

Anatomically, the dorsalis pedis artery (DPA) is derived from the anterior tibial artery branching from the popliteal artery behind the knee joint (popliteal area). The dorsalis pedis artery is located on the talus, navicular bone, and its branches into the medial tarsal artery, lateral tarsal artery, arcuate artery inferiorly, and also the first dorsal metatarsal artery to the cuneiform bone. It submerges at the proximal part of the first metatarsal space. The arcuate artery branches to the second, third, and fourth dorsal metatarsal and digital artery for the nourishment of the dorsal foot. Nevertheless, variations of the dorsalis pedis artery can emerge (Prathapamchandra *et al.*, 2017; Ntuli *et al.*, 2018).

The dorsalis pedis artery is a substantial artery of the anterior ankle that carries nutrient and oxygenated blood to the forefoot with clinical importance for taking the pulse.

Pulse measurement of lower limb can be estimated by this artery for investigation of normal vascularization of foot and ankle. General physical examination is an important section for determining the location of DPA but having exact anatomical knowledge and location can contribute the pulse taking. Ultrasound technique can assist the location of DPA after the pulse was taken by physical examination is suspected. Moreover, this artery must be of concern during the dissection of the midfoot (Rimchala & Chuckpaiwong, 2015) because the injury and disturbance of this vessel lead to micro trauma and ischemic phenomenon. Procedure of ankle arthroscopy has been reported (Parikh *et al.*, 2017) and links to pseudoaneurysm formation and injury due to variations of the dorsalis pedis artery (Wiske *et al.*, 2016). Anatomical variations of the dorsalis pedis artery require careful and critical assessment.

¹ Faculty of Medicine, Chiang Mai University, Chiang Mai, 50200, Thailand.

² Department of Anatomy, Faculty of Medicine, Chiang Mai University, Chiang Mai, 50200, Thailand.

³ Forensic Osteology Research Center, Faculty of Medicine, Chiang Mai University, Chiang Mai, 50200, Thailand.

⁴ Excellence in Osteology Research and Training Center (ORTC), Chiang Mai University, Chiang Mai, 50200, Thailand.

The lineament anatomy of the dorsalis pedis artery, it is obviously remarked when applying a dorsiflexion position. This artery passes through inferior extensor retinaculum and resides under the subcutaneous tissue. Likewise, the dorsalis pedis artery is also located between the extensor hallucis longus tendon and extensor digitorum longus tendon. DPA penetrates the proximal part of the great toe (Sirasanagandla *et al.*, 2013). Nevertheless, various conditions do not direct the position and distribution of this artery precise, for example, hypoplastic of the anterior tibial artery and thromboangiitis obliterans of the chronic cigarette smoker.

The knowledge of several variations of the dorsalis pedis artery pattern is clinically important because the dorsalis pedis artery provides the major blood supply to the dorsum of the foot. Practically, DPA is measured to assess arterial disease like Buerger's disease (Thromboangiitis obliterans). Some factors disrupt the DPA pulse measurement like arterial size, obstruction, atherosclerosis, and the thickness of subcutaneous fat. Some studies indicate that the absence of a DPA pulse is associated with pseudoaneurysm of the dorsalis pedis artery, diabetic neuropathy (Unnikrishnan, 2008).

Clinical issues of the dorsalis pedis artery are, its precise location and the percentage of each variation of DPA. Knowing the variation and some parameters would estimate the position of DPA under the foot's skin. The study of the Thai pattern of the dorsalis pedis artery feature and distribution has not been reported. Apart from that, research regarding this crucial artery of the foot is needed.

MATERIAL AND METHOD

Samples: A cross-sectional descriptive study was conducted to investigate the distribution of the dorsalis pedis artery pattern at the ankle joint anteriorly in the population sample of Thai cadaveric feet from the Cadaveric Surgical Training Center, Faculty of Medicine, Chiang Mai University. The 40 sample feet were 12 female and 28 male feet. The collected adult feet samples (between 20 years old to 80 years old) had an intact dorsalis pedis artery without necrosis and frostbite phenomenon.

Measurement: Vascular injection by painting was used to compress into the popliteal artery for distribution into an anterior tibial artery (original route of the dorsalis pedis artery), posterior tibial artery, and peroneal artery. Tract of vascularization will appear after painting is injected.

To determine all parameters about DPA, diverse parameters were measured by digital vernier calipers of 0.02 mm accuracy on both sides of the leg and arcuated loop can be shown in the Figure 1.

Further study, observation of the presence of DPA under the extensor hallucis longus (EHL) utilizing regular visual observation in Figure 2.

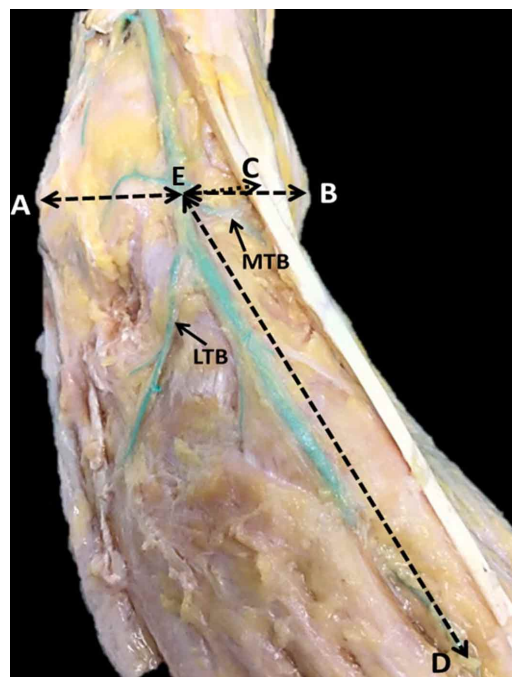


Fig. 1. All DPA parameters; AE = Distance from the tip of lateral malleolus to DPA; BE = Distance from the tip of medial malleolus to DPA; CE = Distance from the midpoint of EHL (in situ) to DPA; DE = DPA length; LTB = lateral tarsal branch; MTB = medial tarsal branch.

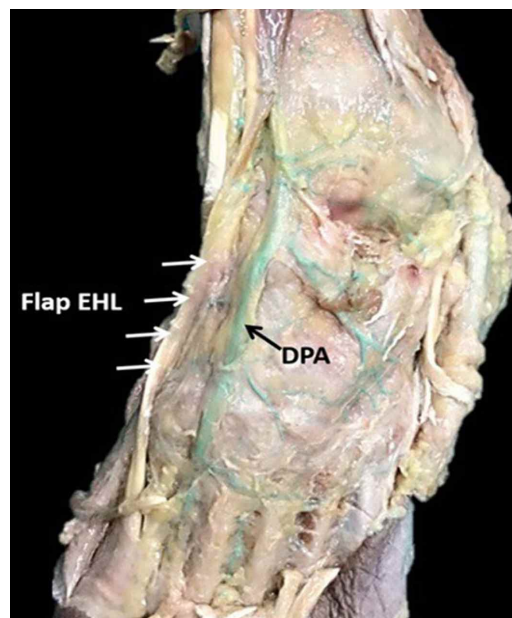


Fig. 2. Presence of DPA under flap EHL utilizing regular visual observation.

Statistics Analysis: The results of the operation were collected and compared. Measurements of the pattern of the dorsalis pedis artery were collected individually and determined by mean \pm standard deviation (mean \pm SD).

All the prior parameters were analyzed statistically by the SPSS version 26 (SPSS Inc., Chicago, IL, USA) and Microsoft Excel 2016 (Microsoft Corp., Redmond, WA, USA). The descriptive analysis was retained for describing the central tendency and dispersion of data and an independent sample t-test was used as a test of significance under p-value < 0.05 was considered as statistical significance.

RESULTS

Prevalence of Patterns of DPA and Their Comparison.

According to the study of the 40 legs sample, the standard pattern of the DPA presenting the medial and lateral tarsal artery, arcuate loop and first dorsal metatarsal artery was 37.5 %. The DPA without the medial tarsal artery was 17.5 % and the DPA without an arcuate loop was 45 % (Table I).

Table I Prevalence of pattern of DPA in sample of 40 legs.

Pattern of DPA	Percent (%)
Standard pattern of DPA	37.5
DPA without medial tarsal artery	17.5
DPA without lateral tarsal artery	0
DPA without arcuate loop	45
Total	100

Also, this study investigated the number of branches of the medial and lateral tarsal artery. We found that the number of medial tarsal artery branches two branches in the male left sides, one branch of the male right side, two or three branches of the female left side, and two branches in female right sides. Likewise, the number of lateral tarsal artery branches had primarily two branches in male left sides, two branches of male right sides, two or three branches of female left sides, and two branches in the female right side.

Descriptive Parameters of DPA from various DPA Landmarks.

From Table II, the right leg, the distances of the DPA of the right leg to the lateral malleolus and medial malleolus were 51.57 ± 6.30 mm and 40.95 ± 7.38 mm, respectively. The lateral distance

of EHL to DPA was 14.04 ± 5.29 mm and DPA length is 119.62 ± 24.12 mm. Likewise, the distances of the DPA of the left leg to the lateral malleolus and medial malleolus were 51.39 ± 8.08 mm and 41.79 ± 8.18 mm, respectively. The lateral distance of EHL to DPA was 14.53 ± 2.49 mm and DPA length is 124.44 ± 17.36 mm.

According to the study of 40 legs in the sample, the parameters of right leg had no statistically significant difference and the parameters of left leg have no statistically significant difference. In total population, the distances of the DPA to the lateral

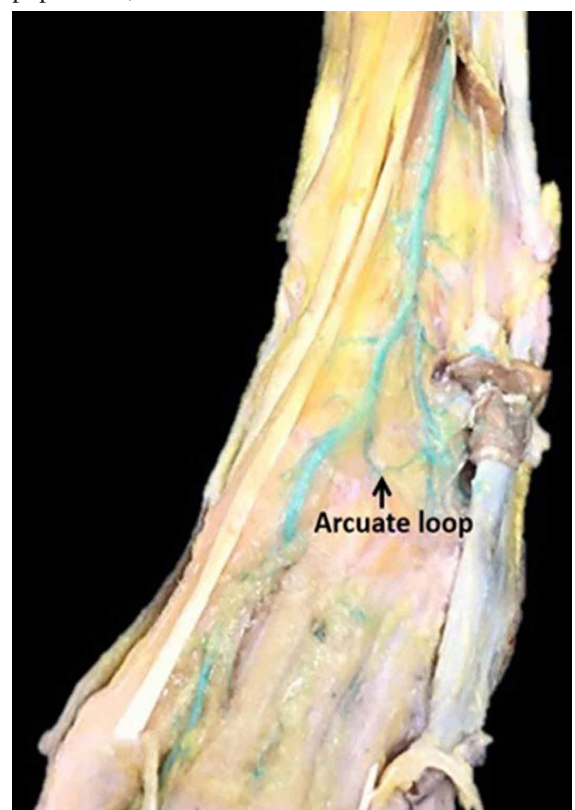


Fig. 3. Arcuate loop : Anastomosis of 2 lateral tarsal arteries above naviculocuneiform joint.

Table II Parameters of dorsalis pedis artery (DPA) from various DPA landmarks on the right and left sides among all samples and different sexes (p < 0.05).

Measurement	Total population			Sex difference					
	Right side (mm)	Left side (mm)	p-value	Right side (mm)		p-value	Left side (mm)		p-value
				Male	Female		Male	Female	
LM-DPA	51.57±6.30	51.39±8.08	0.9400	52.21±4.47	50.09±8.7	0.5048	52.97±4.4	47.72±12.38	0.2024
MM-DPA	40.95±7.38	41.79±8.18	0.7381	41.46±5.52	39.73±9.96	0.6434	42.39±6.14	40.39±11.51	0.6386
EHL-DPA	14.04±5.29	14.53±2.49	0.7094	13.43±5.24	15.46±4.65	0.4485	14.58±2.17	14.43±3.11	0.9114
DPA length	119.62±24.12	124.44±17.36	0.476	114±24.07	132.73±15.68	0.1136	122.66±19.07	128.6±11.47	0.5092

Note: LM-DPA = Distance from the tip of lateral malleolus (LM) to DPA; MM-DPA = Distance from the tip of medial malleolus (MM) to DPA; EHL = Distance from the midpoint of extensor hallucis longus (EHL) to DPA

malleolus and medial malleolus were 51.48 ± 7.27 mm and 41.37 ± 7.81 mm, respectively. Moreover, the distance of EHL to DPA was 14.29 ± 4.11 mm. Laterally and the length of DPA was 122.03 ± 21.07 mm by measuring from the malleolar line to the first intermetatarsal space. Arcuate loop of DPA (Fig. 3) was found 55 % in this study.

Statistically, there was no significant difference between the sides of the leg. There were also no significant differences between sex parameters (Table II).

DISCUSSION

For the prevalence of DPA variation pattern in present study, the standard pattern of DPA, measured from an intermalleolar line to the dorsal metatarsal artery, including the medial tarsal artery and its branches, lateral tarsal artery and its branches, first dorsal metatarsal artery, arcuate artery and deep plantar artery inferiorly was found 37.5 % in Thai population. Some variations like DPA without medial tarsal artery and DPA without arcuate loop were found 17.5 % and 45 %, respectively. Besides, the number of tarsal branches is diverse. Arcuated loop is the structure of the vessel which is the anastomosis between dorsalis pedis artery and lateral tarsal artery. Appearance of DPA can compensate blood supply if there is obstruction in DPA or lateral tarsal artery. In addition, the branches of DPA and lateral tarsal artery can supply oxygenated blood to the dorsum of the foot.

Other studies are shown in Table III. Studying in South Africa (Ntuli *et al.*) reported the standard pattern to

be 36.36 % with an absence of the DPA character of 6.06 % and DPA without the arcuate artery 27.27 %. On the other hand, studies in India had several reports. Vijayalakshmi *et al.* (2011), showed 56 % of the standard pattern, 2 % of no DPA, and 6 % of DPA without an Arcuate artery. Rajeshwari *et al.* (2013) showed 54.76 % of the standard pattern, 9.52 % of no DPA, and 19.05 % of DPA without the Arcuate artery. In contrast, Kulkarni & Ramesh (2012) showed 15.2 % of a standard pattern and 42.4 % of no DPA characteristics.

During the third to fourth week of embryogenesis, precursors called hemangioblasts differentiate into the blood cell precursor and vascular precursor or angioblast cells. Vascular tissue is derived from the blood islands and forms a remodeled vasculature. Recent vessels of the adjacent fields form a linked network, some vessels fall back and others diverge in the mode of origin depending on their function. The first step in developing blood vessels is related to endothelial cells (Sadler, 2012; Udan *et al.*, 2013). The dorsalis pedis artery (DPA) is the main arterial vessel that supplies the dorsum of the foot. Anatomical variation and its branching patterns are clinically significant during ankle and dorsum of foot surgery.

In the present study, the exact location of DPA can be estimated by using some parameters. The distances of the DPA to the lateral malleolus and medial malleolus were 51.48 ± 7.27 mm and 41.37 ± 7.81 mm, respectively. The length of DPA was 122.03 ± 21.07 mm by measuring from the malleolar line to the first intermetatarsal space. The pearls of this study are the location of the DPA can be estimated 2/5 medially from the tip of the intermalleolar line (shift 1 finger's breadth medially from the midline of

Table III Different patterns of the dorsalis pedis artery between the previous studies and this study.

Author	Population (leg cases)	Standard pattern (%)	DPA without medial tarsal artery (%)	DPA without lateral tarsal artery (%)	No DPA (%)	DPA without Arcuate artery (%)
Vijayalakshmi <i>et al.</i> (2011) *	India (50)	56	N/A	N/A	2	6
Kulkarni <i>et al.</i> (2012) **	India (33)	15.2	N/A	N/A	42.4	N/A
Rajeshwari <i>et al.</i> (2013) ***	India (42)	54.76	N/A	N/A	9.52	19.05
Ntuli <i>et al.</i> (2018) ****	South African (66)	36.36	N/A	N/A	6.06	27.27
Present study (2020)	Thai (40)	37.5	17.5	0	0	45

Note: * Vijayalakshmi *et al.* (2011) claimed the other pattern like the variant origin of dorsalis pedis artery = 8 %, variation in the course of dorsalis pedis artery = 2 % and variation in the branching pattern of dorsalis pedis artery = 16 %.

** Kulkarni *et al.* (2012) declared the other patterns like larger lateral tarsal artery and a smaller dorsalis pedis artery = 9.1%, reduction of the anterior tibial artery and its branches = 6.1 % and increasing participation of anterior peroneal branch from posterior tibial artery = 12.1 %

*** Rajeshwari *et al.* (2013) reported the other patterns like dorsalis pedis present with variation in branching pattern = 14.29 %, variation of origin of dorsalis pedis and lateral tarsal arteries = 2.38% and arcuate artery forms a U-shaped loop = 2.38 %

**** Ntuli *et al.* (2018) revealed the other patterns like variation in the origin of second dorsal metatarsal artery = 12.12 %, dorsalis pedis present with variation in branching pattern and variation of origin of dorsalis pedis and lateral tarsal arteries = 6.06 % and poorly formed dorsalis pedis artery and lateral tarsal artery and arcuate artery forms a U-shaped loop = 3.0 %

the intermalleolar line) and variation of the Thai population is different. The physician can determine its location by finding the middle between the two malleolar lines and shift one finger's breadth medially. Experimentally in 20 blind cases, the DPA was located under this position in 16 cases (80 % accuracy of this formula) while general textbooks acknowledge that position of DPA was found in the medial one-third between the two malleoli.

Another study in Malaysia, Gupta *et al.* (2018), reported the average length of dorsalis pedis artery was 7.8 cm, averages length from medial malleolus and lateral malleolus were 3.9 cm and 4.5 cm, respectively.

Nevertheless, the present study found the DPA located under the EHL one case from forty samples. This situation, the DPA cannot take pulse by physical examination, the ultrasound investigation can apply in this case for estimating the DPA location. Knowledge of dorsalis pedis artery variations may help surgeons when performing the surgical operation and ankle arthroscopy procedures. Also, the dorsalis pedis artery is mainly used to palpate the foot pulse in cases of some peripheral vascular diseases like atherosclerosis. Some suggestions elucidate that it can be palpated lateral to the extensor hallucis longus tendon. The location of the DPA can be estimated 2/5 medially from the tip of the intermalleolar line (shift 1 finger's breadth medially from the midline of the intermalleolar line) in this study. DPA bypass is also an important procedure in cases of obstructed or ischemic vascular limb, because of this preferentially used vessel.

The clinical application of this study is the physical examination of DPA taking pulse by shift 1 finger's breadth medially from the midline of the intermalleolar line and depressing the finger for taking the pulse. Likewise, knowing the variation pattern and some exception such as DPA under the EHL structure, may also be useful to determine the location of DPA. Intervention such as Ultrasound procedure, CT scan can apply to confirm the position of DPA but they are expensive in some situation.

CONCLUSION

In conclusion, there was no statistically significant difference between sex or side of the leg for measuring the position of the DPA. The position of DPA can be measured from the mid intermalleolar line and shift medially or estimate about 14 mm medially from the midpoint of extensor hallucis longus tendon. Anatomical variation of DPA is essential for precise clinical implications.

ACKNOWLEDGMENTS. This study was supported by Cadaveric Surgical Training Center and Department of Anatomy, Faculty of Medicine, Chiang Mai University, Thailand. This research work was partially supported by Chiang Mai University.

ETHICS. We obtained ethics approval from the Research Ethics Committee of Chiang Mai University (CODE: ANA 2562 06619). The cadavers of this study were provided by the Department of Anatomy at Chiang Mai University. The consent to use the cadavers was obtained from the patient before death.

THUNYACHAROEN, S.; MAHAKKANUKRAUH, C.; PATTAYAKORNKUL, N.; MEETHAM, K.; CHARUMPORN, T. & MAHAKKANUKRAUH, P. Variaciones anatómicas de la arteria dorsal del pie en una población tailandesa. *Int. J. Morphol.*, 40(1):137-142, 2021.

RESUMEN: La arteria dorsal del pie (ADP) es una arteria vital que irriga el dorso del pie y el tobillo, y es clínicamente importante para la toma del pulso. Esta investigación se realizó en disección cadavérica de 40 piernas inyectando látex coloreado en la arteria poplítea para rastrear la ADP y sus ramas. La presente investigación reveló que en la población tailandesa la ADP tiene una variación anatómica y una ubicación diferente. Por tanto, determinar la ubicación exacta del ADP será útil para las implicaciones clínicas. El análisis estadísticamente descriptivo determinó que las distancias del ADP al maléolo lateral y al maléolo medial eran $51,48 \pm 7,27$ mm y $42,62 \pm 11,40$ mm, respectivamente. La distancia del tendón del músculo extensor largo del halux (ELH) al ADP era de $14,29 \pm 4,11$ mm. La longitud de la ADP, desde la línea intermaleolar hasta su entrada al primer espacio intermetatarsiano, era de $122,03 \pm 21,07$ mm. El asa arqueada, que es una anastomosis U-loop de las arterias tarsales laterales de la ADP, se encontró en un 55 % de la población tailandesa. No hubo diferencias estadísticamente significativas en todos los parámetros de la ADP entre el lado y el sexo. La comprensión de las variaciones de las variaciones anatómicas de la ADP es esencial para una evaluación clínica precisa. El conocimiento anatómico exacto y la ubicación pueden contribuir a la toma del pulso y ser útil en el procedimiento quirúrgico.

PALABRAS CLAVE: Variación anatómica; Arteria dorsal del pie.

REFERENCES

- Gupta, C.; Kumar, R.; Palimar, V. & Kalthur, S. G. Morphometric study of dorsalis pedis artery and variation in its branching pattern: A cadaveric study. *Int. Med. J. Malays.*, 17(1):19-22, 2018.
- Kulkarni, V. & Ramesh, B. R. A morphological study of dorsalis pedis artery and its clinical correlation. *J. Pharm. Biol. Sci.*, 2:2278-3008, 2012.
- Ntuli, S.; Nalla, S. & Kiter, A. Anatomical variation of the Dorsalis pedis artery in a South African population - A Cadaveric Study. *Foot (Edinb.)*, 35:16-27, 2018.

- Parikh, S.; Dawe, E.; Lee, C.; Whitehead-Clarke, T.; Smith, C. & Bendall, S. A cadaveric study showing the anatomical variations in the branches of the dorsalis pedis artery at the level of the ankle joint and its clinical implication in ankle arthroscopy. *Ann. R. Coll. Surg. Engl.*, 99(4):286-8, 2017.
- Prathapamchandra, V.; Ravichandran, P.; Shanmugasundaram, J.; Jayaraman, A. & Salem, R. S. Vascular foramina of navicular bone: a morphometric study. *Anat. Cell Biol.*, 50(2):93-8, 2017.
- Rajeshwari, M. S.; Roshankumar, B. N. & Vijayakumar. An anatomical study on dorsalis pedis artery. *Int. J. Anat. Res.*, 1(2):88-92, 2013.
- Rimchala, C. & Chuckpaiwong, B. Relationship of the dorsalis pedis artery to the tarsal navicular. *J. Foot Ankle Surg.*, 54(1):66-8, 2015.
- Sadler, T. W. *Langman's Medical Embryology*. 12nd ed. Philadelphia, Wolters Kluwer Health/Lippincott Williams & Wilkins, 2012.
- Sirasaganandla, S. R.; Swamy, R. S.; Nayak, S. B.; Somayaji, N. S.; Rao, M. K. G. & Bhat, K. M. R. Analysis of the morphometry and variations in the extensor digitorum brevis muscle: an anatomic guide for muscle flap and tendon transfer surgical dissection. *Anat. Cell Biol.*, 46(3):198-202, 2013.
- Udan, R. S.; Culver, J. C. & Dickinson, M.E. Understanding vascular development. *Wiley Interdiscip. Rev. Dev. Biol.*, 2(3):327-46, 2013.
- Unnikrishnan, A. G. Approach to a patient with a diabetic foot. *Natl. Med. J. India*, 21(3):134-7, 2008.
- Vijayalakshmi, S.; Raghunath, G. & Shenoy, V. Anatomical study of dorsalis pedis artery and its clinical correlations. *J. Clin. Diagn. Res.*, 5(2):287-90, 2011.
- Wiske, C. P.; Itoga, N. K.; Ullery, B. W.; Hunt, K. J. & Chandra, V. Ruptured pseudoaneurysm of the dorsalis pedis artery following ankle arthroscopy: A case report. *JBJS Case Connect.*, 6(4):e102, 2016.

and Training Center (ORTC)
Chiang Mai University
50200
THAILAND

E-mail: pasuk034@gmail.com

Corresponding author:
Prof. Pasuk Mahakkanukrauh, M.D.
Department of Anatomy & Excellence in Osteology Research