

Supernumerary Muscles in the Posterior Leg Compartment: a Case Report

Músculos Supernumerarios en el Compartimento Posterior de la Pierna: Reporte de un Caso

Paulo Rogério Moritz Postigo; Raquel Sangy da Costa Guimarães; Lucas Alves Sarmento Pires; Rodrigo Mota Pacheco Fernandes; Marcio Antonio Babinski & Jorge Henrique Martins Manaia

POSTIGO, P. R. M.; DA COSTA, R. S.; PIRES, L. A. S.; FERNANDES, R. M. P.; BABINSKI, M. A. & MANAIA, J. H. M. Supernumerary muscles in the posterior leg compartment: a case report. *Int. J. Morphol.*, 40(1):75-78, 2022.

SUMMARY: The leg muscles are organized in anterior, lateral and posterior compartments. The posterior compartment is usually divided in two layers: superficial and deep. The deep muscles of the posterior compartment of the leg are known to mainly plantar flexion and toes flexion. In comparison to the other leg compartments, variations of the posterior one are rare. These variants often involve the presence or absence of one or more muscles, and they have differences among origin and insertion, which leads to confusion between anatomists. We aim to describe a case of a male cadaver that possessed three supernumerary muscles in the lateral and posterior compartments of both legs: the peroneus quartus muscle and two accessory bellies of the flexor digitorum longus. This presentation seems to be very rare and scarcely reported in the literature. These variants have the potential of causing nervous or vascular compression, thus leading to tarsal tunnel syndrome or a symptomatic peroneus quartus. The clinical and surgical implications of this abnormal presentation is discussed.

KEY WORDS: Peroneus quartus; Anatomic variation; Flexor digitorum longus muscle; Nerve compression syndrome; Tarsal tunnel syndrome.

INTRODUCTION

The posterior muscles of the leg are organized in two layers (superficial and deep), the superficial group consists of the sural triceps (gastrocnemius, soleus and plantar muscles), while the deep group is formed by the tibialis posterior, flexor digitorum longus, flexor hallucis longus and popliteus muscles (Testut & Latarjet, 1958; Latarjet & Ruiz-Liard, 2011).

The latter muscles mainly originate from the posterior aspect of the tibia and fibula, and – with the exception of the popliteus muscle – reaches the foot through the tarsal tunnel. The tibialis posterior muscle tendon extends to the navicular and cuneiform bones; the flexor digitorum longus muscle is inserted at the distal phalanges of the four lesser toes and acts as a digit flexor; lastly, the flexor hallucis longus reaches the distal phalanx of the hallux (Testut & Latarjet; Latarjet & Ruiz-Liard).

On the other hand, the lateral compartment of the leg is comprised by the peroneus longus and brevis muscles. These muscles acts during eversion and plantar flexion of the foot and originates mainly from the lateral surface of the fibula

and reaches the medial cuneiform and fifth metatarsal, respectively (Testut & Latarjet; Latarjet & Ruiz-Liard).

Variations of the lateral compartment are more commonly found than muscle variants of the deep posterior compartment (Tubbs *et al.*, 2016). However, these anatomical variations are usually divided in (1) absence of one or more muscle or (2) the presence of supernumerary bundles or supernumerary distinct muscles (Le Double, 1897).

Furthermore, it is known that supernumerary muscle masses or tendons can lead to neurovascular compression, especially near the ankle. While masses at the medial aspect of the ankle can cause tarsal tunnel syndrome (Neary *et al.*, 2019), abnormal muscles can lead to chronic pain over the lateral surface of the foot (Wenning *et al.*, 2019), which gives these variants both clinical and surgical relevance.

The peroneus quartus muscle (PQM) is an accessory muscle of the lateral compartment of the leg with a prevalence ranging from 1 to 20% of cases, while accessory

bundles of the flexor digitorum longus muscle are rarer, and these variations are often limited to the disposition of its tendons. The flexor digitorum accessories longus muscle, however, is present in over 6% of cases (Hur *et al.*, 2014; Tubbs *et al.*). The literature is scarce regarding anatomical specimens with more than one variation.

Thus, we aim to report the bilateral presence of three supernumerary muscles found in the posterior and lateral compartments of the leg and discuss its clinical aspects with regards to neurovascular compression.

CASE REPORT

A male cadaver fixated in a 10% buffered formalin solution was dissected during regular anatomy lessons. It

was observed an uncommon anatomical variation of its muscles when the posterior compartment of the right leg was performed. Three supernumerary muscle bands were found and identified as the peroneus quartus muscle and two accessory bellies of the flexor digitorum longus (Fig. 1). Afterwards, the left leg of the cadaver was dissected as well, which also showed the same variations of the right (Fig. 2).

At the left leg, the peroneus quartus muscle originated from the belly of the peroneus brevis, whereas at the right leg it originated from the intermuscular septum and reached the retrotrochlear eminence of the calcaneus. It possessed a long and thin tendon. This muscle was supplied by a branch of the superficial peroneal nerve.

The two accessory bellies of the flexor digitorum longus originated near the intermuscular crural septum and the belly of the flexor hallucis longus muscle. They emitted a tendon that passed the tarsal tunnel and joined the main flexor digitorum longus before originating the tendon for each finger. Both bellies were supplied by branches of the tibial nerve.

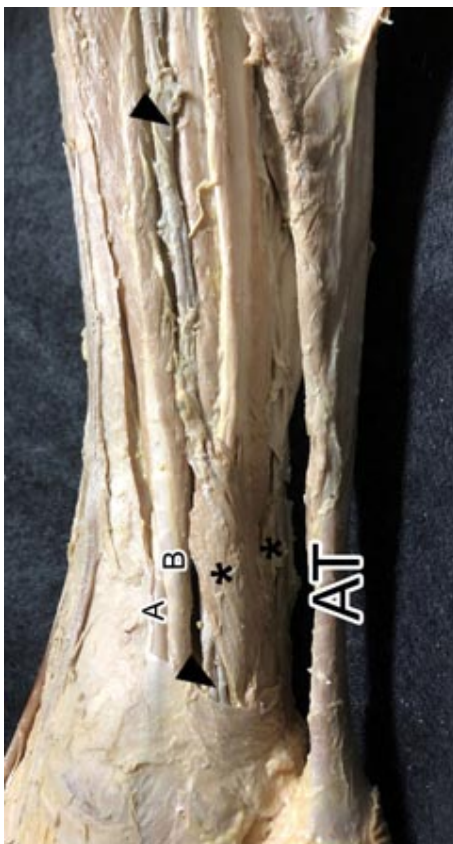

Fig. 1. Three supernumerary muscle bands and vascular nervous bundle (arrowhead) in the right leg (medial view). The peroneus quartus muscle is situated laterally and beneath both accessory bellies (asterisk) of the flexor digitorum longus. Posterior Tibial (A) and (B) Flexor Digitorum Longus Muscles.

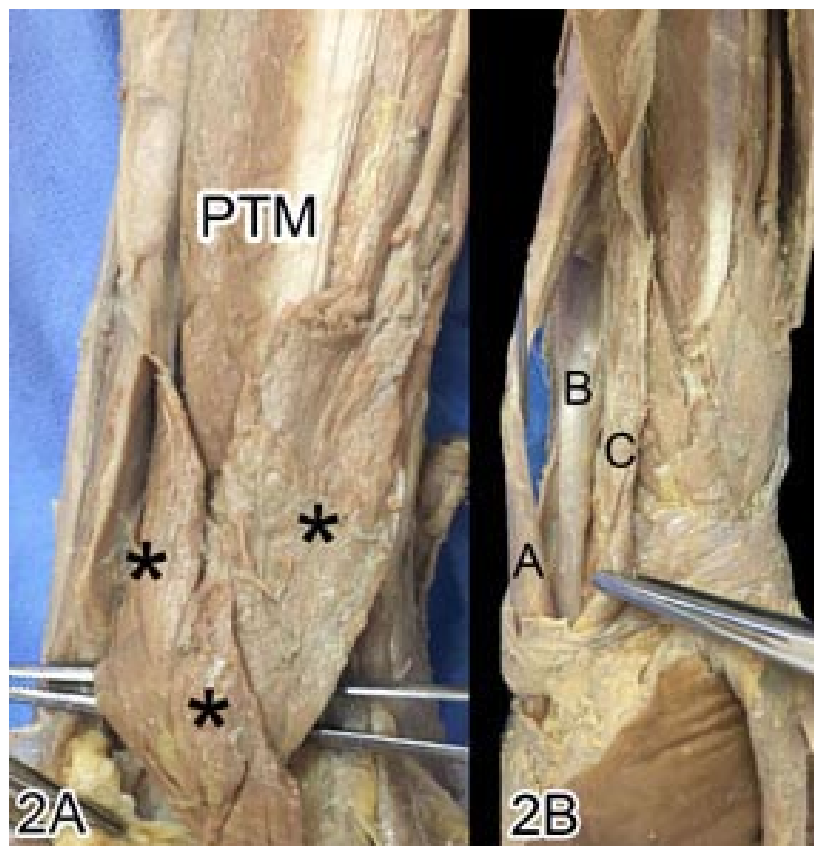


Fig. 2. (2A) Posterior view showing the posterior tibial muscle (PTM), the relationship of the accessory bellies (asterisk) and their fusion above. (2B) Lateral compartment showing the peroneus quartus muscle (C) above and its relationship with peroneus longus (A) and brevis (B) muscles.

DISCUSSION

According to our bibliographic search, this is the first description of these multiple variations presented bilaterally in a single cadaver. As such, we will discuss the individual aspects of these muscles and other significant reports.

The peroneus quartus is an accessory muscle of the lateral compartment of the leg seemingly unique to humans. Hecker (1923) reported an incidence of roughly 13% in the general population, which was in a similar fashion reported by Tubbs *et al.* that found a pooled prevalence of 11.5% after analyzing several works.

The insertion site of the peroneus quartus is variable and this caused confusion among anatomists, as each variation of its insertion created a different name – despite being essentially the same muscle. For instance, the peroneus quartus was labeled as “fibularis accessories muscle” muscle by Henle; “fibulo-calcaneus externum muscle” by Wood, Theile, and Macalister; “fibulofibularis accessorius sixth” by Macalister; “peroneus calcaneus externum” by Hecker; and “peroneus accessorius” by White (Le Double and Yammine, 2015).

Zammit & Singh (2003) observed that the majority of peroneus quartus variants differs in the origin and insertion of its fibers and tendons, which can divide in more than one or have multiples points of origin. Sobel *et al.* (1991) reported the insertion of the peroneus quartus into the distal fibular groove as an uncommon variant.

Other insertions reported in the literature are the retrotrochlear eminence of the calcaneum, the base of the fifth metatarsal, the cuboid, the peroneus brevis or longus tendon and the peroneal tubercle, while its origins are usually the lower third of the lateral surface of the fibula and the posterior intermuscular septum (Zammit & Singh; Lui & Li, 2020) The variant presented herein is in accordance with previous reports, as it originated from belly of the peroneus brevis at one side and the intermuscular septum at the other, while it reached the retrotrochlear eminence of the calcaneus.

Regarding the flexor digitorum longus muscle, there is a significant variation labeled as flexor digitorum accessorius longus (FDAL) which is reported as one of the most commons muscle variants of posterior compartment with a prevalence between 4% to 13% of the cases (Hur *et al.*).

There are some variations regarding the origin and insertion of this accessory muscle as well. According to Cheung (2017), it can arise from the fascia of the deep poste-

rior compartment, flexor hallucis longus, and margins of the fibular, while it can insert into the quadratus plantae or the flexor digitorum longus muscle before its division. The latter type of insertion was found in our report.

Bowers *et al.* (2009) showed that the FDAL originated from the posterior crural fascia and the proximal portion of the flexor digitorum longus in the deep posterior compartment of the leg. Although the occurrence of a two-headed FDAL is considered exceedingly rare, it has already been reported by Hwang & Hill (2009), also found bilaterally. This is probably the most similar report in comparison to ours, although it lacks the presence of the peroneus quartus.

Owing to the course through the tarsal tunnel, the presence of the FDAL is often associated to the confusion of radiographic interpretations and compartment syndromes – mostly the tarsal tunnel syndrome.

The tarsal tunnel is an important pathway which connects the leg and foot. It gives passage to the tendon of three muscles of the posterior leg compartment (tibialis posterior, flexor digitorum longus, flexor hallucis longus muscles), the tibial nerve and the posterior tibial vessels. Topographically, it is bounded by the flexor retinaculum above, the talus and calcaneus medially, and the abductor hallucis inferiorly (Testut & Latarjet; Latarjet & Ruiz-Liard).

The tarsal tunnel syndrome is a neuropathic or vascular compression characterized by the pressure over the tibial nerve or its branches on the way through tarsal tunnel. It is a condition that, despite of the underdiagnosis and lack of incidence, still prevails in females than males, mainly in adult population. (Mcsweeney & Cichero, 2015).

The usual symptoms begin with ankle pain, swelling, painful walking and plantar foot pain while standing, as well as a burning sensation and numbness. Tarsal tunnel syndrome can be caused by benign tumors – like schwannomas - (Jha *et al.*, 2019), perineural fibrosis, varicosities, osteophytes, traumas and postoperative scarring (Neary *et al.*), while the presence of supernumerary structures at the tarsal tunnel can also lead to this syndrome as well.

The peroneus quartus is also clinically relevant in cases of lateral foot pain which can be found during exploratory surgery - as it is usually neglected in magnetic resonance imaging diagnostics (Wenning *et al.*). It can be found in association with tendinous calcification and can be mistaken by split or tears in the peroneal brevis or subluxation (Lui & Li). If symptomatic, the peroneus quartus can lead to include chronic lateral ankle pain, clicking or snapping and ankle instability (Bilgili *et al.*, 2014).

The treatment of both clinical entities (e. g. tarsal tunnel syndrome and symptomatic peroneus quartus muscle) includes operative and nonoperative categories, which should be chosen according to the clinical condition. The nonoperative modalities involves primarily symptoms relief including the use of anti-inflammatories, analgesics, activity modifications, exercises and physical therapy (Neary *et al.*;; Lui & Li).

Usually, the surgical management is chosen when the conservative management isn't enough to relieve symptoms or fails to do so any longer. Surgery also depends on the etiology of the compression neuropathy and patient's characteristic such as comorbidities and age. In cases of supernumerary muscle masses, the usual course is removal of the abnormal muscle by open or endoscopic surgery (Lui & Li). The surgical success rates vary according to previous pathology, history of symptoms and early diagnosis. (Neary *et al.*).

Although the triad presented herein is rare, these muscles can individually appear in a more prevalent fashion. As such, knowledge of the variations that can occur in the posterior leg compartment are useful to differential diagnosis in cases of foot and ankle pain/swelling.

POSTIGO, P. R. M.; DA COSTA, R. S.; PIRES, L. A. S.; FERNANDES, R. M. P.; BABINSKI, M. A. & MANAIA, J. H. M. Músculos supernumerarios en el compartimiento posterior de la pierna. Reporte de un caso. *Int. J. Morphol.*, 40(1):75-78, 2022.

RESUMEN: Los músculos de la pierna están organizados en compartimentos anterior, lateral y posterior. El compartimiento posterior por lo general es dividido en dos capas: superficial y profunda. Se sabe que los músculos profundos del compartimiento posterior de la pierna se caracterizan principalmente por participar de la flexión plantar y la flexión de los dedos de los pies. En comparación con los otros compartimentos de la pierna, las variaciones musculares en el compartimiento posterior son raras. Estas variantes suelen implicar la presencia o ausencia de uno o más músculos y presentan diferencias en el origen y en la inserción, lo que conduce a confusión entre los anatomistas. Nuestro objetivo fue describir el caso de un cadáver masculino que poseía tres músculos supernumerarios en los compartimentos lateral y posterior de ambas piernas: el músculo fibular cuarto y dos vientres accesorios del músculo flexor largo de los dedos. Esta presentación parece ser muy rara y escasamente reportada en la literatura. Estas variantes musculares tienen el potencial de causar compresión nerviosa o vascular, lo que conduce al síndrome del túnel del tarso o un cuarto músculo fibular sintomático. Se discuten las implicaciones clínicas y quirúrgicas de esta presentación anormal.

PALABRAS CLAVE: Cuarto músculo fibular; Variación anatómica; Músculo flexor largo de los dedos; Compresión nerviosa; Síndrome del túnel tarsiano.

REFERENCES

- Bilgili, M. G.; Kaynak, G.; Botanlioglu, H.; Basaran, S. H.; Ercin, E.; Baca, E. & Uzun, I. Peroneus quartus: prevalence and clinical importance. *Arch. Orthop. Trauma Surg.*, 134(4):481-7, 2014.
- Bowrs, C. A.; Mendicino, R. W.; Catanzariti, A. R. & Kernick, E. T. The flexor digitorum accessorius longus-a cadaveric study. *J. Foot Ankle Surg.*, 48(2):111-5, 2009.
- Cheung, Y. Normal Variants: Accessory Muscles About the Ankle. *Magn. Reson. Imaging Clin. N. Am.*, 25(1):11-26, 2017.
- Hecker, P. Study on the peroneus of the tarsus. *Anat. Rec.*, 26:79-82, 1923.
- Hur, M. S.; Won, H-S.; Oh, C-S.; Chung, I-H Lee, W. C. & Yoon, Y. C. Classification system for flexor digitorum accessorius longus muscle variants within the leg: clinical correlations. *Clin. Anat.*, 27(7):1111-6, 2014.
- Hwang, S. H. & Hill, R. V. An unusual variation of the flexor digitorum accessorius longus muscle--its anatomy and clinical significance. *Anat. Sci. Int.*, 84(3):257-63, 2009.
- Jha, A. J.; Basetty, C. R.; Viner, G. C.; Tedder, C. & Shah, A. Posterior Tibial Nerve Schwannoma Presenting as Tarsal Tunnel Syndrome. *Cureus*, 11(8):e5303, 2019.
- Latarjet, M. & Liard, A. R. *Anatomía Humana*. 4a. ed. Madrid, Medica Panamericana, 2011.
- Le Double, A.F. *Traité des variations du système musculaire de l'homme et de leur signification au point de vue de l'anthropologie zoologique*. Paris, Schleischer Frères, 1897.
- Lui, T. H. & Li, H. M. Endoscopic Resection of Peroneus Quartus. *Arthrosc. Tech.*, 9(1):e35-e38, 2020.
- McSweeney, S. C.; Cichero, M. Tarsal tunnel syndrome-A narrative literature review. *Foot (Edinb)*, 25(4):244-50, 2015.
- Neary, K. C.; Chang, E.; Kreulen, C. & Giza, E. Tarsal Tunnel Syndrome Secondary to Accessory Musculature: A Case Report. *Foot Ankle Spec.*, 12(6):549-54, 2019.
- Sobel, M.; Levy, M. E.; Bohme, W. H. Congenital variations of the peroneus quartus muscle: an anatomic study. *Foot Ankle Spec.*, 11(2):81-9, 1990.
- Testut, L. & Latarjet, A. *Tratado de Anatomía Humana*. 9. Barcelona, Salvat, 1958.
- Tubbs, R. S.; Shoja, M. M. & Loukas, M. Eds. *Bergman's Comprehensive Encyclopedia of Human Anatomic Variation*. New Jersey, Wiley Blackwell, 2016.
- Wenning, M.; Heitner, A. H.; Ulrich, M.; Paul, J. Rist, H-J. M. Peroneus Quartus Causing Chronic Peroneal Compartment Syndrome in a Runner Treated by Endoscopic Fasciotomy: A Case Report. *J. Foot Ankle Surg.*, 58(4):653-6, 2019.
- Yamine, K. The accessory peroneal (fibular) muscles: peroneus quartus and peroneus digiti quinti. A systematic review and meta-analysis. *Surg. Radiol. Anat.*, 37(6):617-27, 2015.
- Zammit, J. & Singh, D. The peroneus quartus muscle. Anatomy and clinical relevance. *J. Bone Joint Surg. Br.*, 85(8):1134-7, 2003.

Corresponding author:
Marcio Antonio Babinski
Fluminense Federal University
Morphology Department -Biomedical Institute
Rua Professor Ernani Mello, 101
São Domingos - Niterói - ZIP CODE 24210-150
Rio de Janeiro
BRAZIL

E-mail: mababinski@gmail.com