

Anastomosis Between the Posterior Superior Alveolar Artery and the Infra-Orbital Artery: A Review of Current Terminology

Anastomosis entre la Arteria Alveolar Superior Posterior y la Arteria Infra-Orbital: Una Revisión de la Terminología Actual

Nilton Alves^{1,2}; Francisco Ceballos³ & Naira Figueiredo Deana^{4,5}

ALVES, N.; CEBALLOS, F. & DEANA, N. F. Anastomosis between the posterior superior alveolar artery and the infra-orbital artery: A review of current terminology. *Int. J. Morphol.*, 40(1):18-23, 2022.

SUMMARY: The posterior superior alveolar artery (PSAA) and the infra-orbital artery (IOA) present intraosseous and extraosseous rami which form an anastomosis in the lateral wall of the maxillary sinus. This anastomosis is always present, however it has not yet been included in anatomical terminology (AT), and different terms are used in scientific communication to refer to it. The aim of this study was to carry out a review of the different terms used to name this vascular structure. A literature review was carried out on the terms used to name the anastomosis between the PSAA and IOA in imaging studies and human cadavers that assessed the presence/frequency of this anatomical structure. The search was carried out in the Medline, EMBASE and LILACS databases, in Portuguese, Spanish and English, with no date restrictions. Qualitative analysis was applied to the studies selected, analysing the terminology used to refer to the anastomosis between the PSAA and IOA. Of the 2108 original articles found, 60 were selected as potentially relevant and 54 studies were finally included for qualitative analysis. Sixteen terms were found to refer to the anastomosis between the PSAA and IOA, the most frequent being Posterior Superior Alveolar Artery (PSAA), followed by Alveolar Antral Artery (AAA). Many terms are used in the medical literature to designate the anastomosis between the PSAA and IOA, the most frequent being PSAA and AAA. There is a need to unify the terms used to designate this vascular structure, and to incorporate the selected term into anatomical terminology, in order to avoid confusion in scientific communication.

KEY WORDS: Posterior superior alveolar artery; Infra-orbital artery; Alveolar antral artery; Anatomical terminology.

INTRODUCTION

At the end of the 19th century, the need was recognized to establish an order in the names used to designate anatomical structures, since around 50,000 terms existed to name just over 5,000 anatomical structures (Losardo *et al.*, 2015). In many cases, numerous different terms were used to name the same structure (Cruz & Cruz, 2009). The purpose of anatomical terminology (Terminologia Anatómica– TA) is to ensure clear, precise communication in the medical field, facilitating teaching and learning as well as scientific communication (Duque-Parra *et al.*, 2016). Nonetheless, there are many anatomical structures that have not yet been included in TA, one of which is a vascular structure resulting from anastomosis between the posterior

superior alveolar artery (PSAA) and the infra-orbital artery (IOA). The PSAA and the IOA are rami of the maxillary artery and are responsible for irrigating the pulp and the inserting periodontium of the upper teeth; the mucus and the anterior, lateral and posterior walls of the maxillary sinus; the lower eyelid, the nasal ala and the mucous of the upper lip. These arteries have intraosseous and extraosseous rami which form an anastomosis in the lateral wall of the maxillary sinus (Alves & Cândido, 2016).

The anastomosis between the PSAA and IOA was first described in 1934 by Strong, who related that this artery was responsible for irrigating the mucous membrane of the

¹ Center of Excellence in Surgical and Morphological Research (CEMyQ), Faculty of Medicine, Universidad de La Frontera, Temuco, Chile.

² Applied Morphology Research Center (CIMA), Faculty of Dentistry, Universidad de La Frontera, Temuco, Chile.

³ Faculty of Dentistry, Universidad de La Frontera, Temuco, Chile.

⁴ Center for Research in Epidemiology, Economics and Oral Public Health (CIEESPO), Faculty of Dentistry, Universidad de La Frontera, Temuco, Chile.

⁵ Doctoral Program in Morphological Sciences, Universidad de La Frontera, Temuco, Chile.

maxillary sinus and adjacent teeth (Taschieri & Rosano, 2010). The clinical importance of this artery is related with the risk of severe intraoperative haemorrhage due to lesions caused during surgical procedures in the region, affecting the surgeon's field of view and thus increasing the risk of perforation of the maxillary sinus (Rahpeyma & Khajehahmadi, 2014). Studies in cadavers indicate that the anastomosis between the PSAA and IOA is always present (Ella *et al.*, 2008), however this vascular structure has not yet been included in TA.

In scientific literature, authors use different anatomical terms to refer to this structure, such as PSAA (Jung *et al.*, 2011; Cruz Ibañez *et al.*, 2016), Intraosseous Ramus of the PSAA (de Oliveira *et al.*, 2017), Intraosseous Rami (Duruel *et al.*, 2019), Intramural Artery (Godil *et al.*, 2021), Alveolar Antral Artery (AAA) (Alves & Cândido; Alves, 2017; Alves *et al.*, 2020), etc. Considering the variety of terms used to name this vascular structure, the object of this study was to carry out a systematic review of the terms used.

MATERIAL AND METHOD

Protocol and registration. The protocol was published in INPLASY, number 202120071.

Eligibility criteria. A systematic review was carried out of the terms used to designate the anastomosis between the PSAA and IOA in imaging studies and studies in human cadavers that assessed the presence/frequency of this anatomical structure. The search was carried out in the Medline, EMBASE and LILACS databases, including original studies in Portuguese, Spanish and English. In vitro studies, case reports, theses, letters to the editor and systematic reviews were excluded.

Sources of information. The search was carried out in the Medline, EMBASE and LILACS databases, without date restrictions. In addition, we examined the reference lists of the studies included. The search strategy used in Medline was: (((((((("Cone-Beam Computed Tomography"[Mesh] OR "Spiral Cone-Beam Computed Tomography"[Mesh])) OR CBCT [tiab]) OR Computed Tomography*) OR dissection [tiab]) OR "Dissection"[Mesh]) OR "Cadaver"[Mesh])) AND (((((((((alveolar antral artery) OR intraosseous arterial anastomosis) OR extraosseous arterial anastomosis) OR maxillary sinus vascularization [tiab]) OR maxillary sinus vascular anatomy) AND (((course [tiab]) OR diameter [tiab]) OR anatomy*) OR "Anatomy"[Mesh]) OR Prevalence)

Selection of studies. All references identified were extracted to an EndNote X9 database to facilitate management and delete duplicate articles. Titles and abstracts of studies retrieved using the search strategy were screened independently by two authors to identify studies that potentially met the inclusion criteria. Titles and abstracts were selected using the Rayyan software (<http://rayyan.qcri.org>). We obtained the full texts of all relevant and potentially relevant studies meeting the inclusion criteria, and those for which there were insufficient data in the title and abstract to make a clear decision. Any disagreement between the two authors was resolved through discussion with a third reviewer.

Data charting process. One reviewer (F.C. or N.F.D) extracted relevant data from eligible studies describing their main characteristics. A second reviewer checked all the extracted information for accuracy (non-independent verification of data extraction). The authors extracted the following information from each article using a standardized, predefined data collection form: Author, year, title, type of study (study in cadaver or imaging study), term used to name the anastomosis between the PSAA and IOA.

Synthesis of the results. Qualitative analysis of the data was carried out, as well as percentage analysis of the terms used. Studies which used more than one term were grouped in the category with the highest percentage. The results were presented in a table.

RESULTS

The search strategy identified 2108 original articles; 123 duplicates were excluded. After review of the titles and abstracts, 60 were selected as potentially relevant and 54 studies were finally included for qualitative analysis (Fig. 1). Forty-seven computed tomography or cone-beam computed tomography studies were included (87.0 %), five studies in cadavers (9.3 %) and two imaging studies and cadavers (3.7 %). Sixteen different terms were used to refer to the same structure in the studies analysed (Table I); the term used most frequently was PSAA (38.9 %), followed by Alveolar Antral Artery (27.8 %) and Intraosseous Anastomosis (9.43 %).

DISCUSSION

The maxillary sinus is a cavity located in the interior of the body of the maxilla; it is directly related with the na-

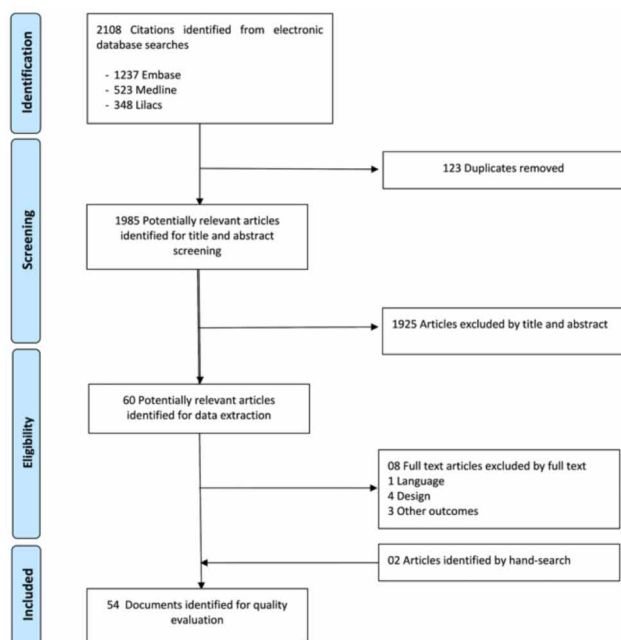


Fig. 1. Flowchart of the studies included.

sal cavity by its nasal or medial wall, and with the dental alveoli of the posterior superior teeth, especially the molars, by its inferior wall or sinus floor (Alves & Cândido). The discovery of the maxillary sinus is attributed to doctor Nathaniel Highmore, who first described it in his book *Corporis Humani Disquisitio Anatomica* (Mavrodi & Paraskevas, 2013); for this reason the structure was included in the *Nomina Anatomica* (NA) as Highmore's Antrum (Wells, 1948). In 1901, years after the inclusion of this term in the NA, sketches by Leonardo da Vinci were discovered, drawn in 1489, which illustrated the maxillary sinus and adjacent structures; however although da Vinci's drawings are the oldest on record, the term Highmore's Antrum had already been included in the NA and was used for many years. Today, since the use of eponyms has been abolished in TA, the term Highmore's Antrum has been reviewed and replaced by the term Maxillary Sinus (Duque-Parra *et al.*, 2016, 2018).

The maxillary sinus is irrigated by the anastomosis between the PSAA, which courses half of the lateral wall of the maxillary sinus intraosseously, and the IOA which courses through the anterior wall of the maxillary sinus

Table I. Percentage and description of the anatomical terms used.

Anatomical terms	Authors	N/total
Alveolar Antral Artery	Albuquerque <i>et al.</i> , 2021 ; Alves <i>et al.</i> , 2020; Al-Ghurabi <i>et al.</i> , 2018; Amine <i>et al.</i> , 2020; Cruz Ibañez <i>et al.</i> , 2016; Dias <i>et al.</i> , 2020; Kalabalik & Akçay, 2020; Kolte <i>et al.</i> , 2021; Laovoravit <i>et al.</i> , 2021; Rosano <i>et al.</i> , 2009; Rosano <i>et al.</i> , 2011; Rahpeyma <i>et al.</i> , 2014; San Aung <i>et al.</i> , 2017; Varela-Centelles <i>et al.</i> , 2016; Yang & Kye, 2014	15/54
Antral Artery	Ella <i>et al.</i> , 2008	1/54
Anastomosis Canal	Sun <i>et al.</i> , 2018	1/54
Canal of the Arterial Anastomosis	Rysz <i>et al.</i> , 2014	1/54
Endosseous vascular canal of the Posterior Superior Alveolar Artery	Jung <i>et al.</i> , 2011	1/54
Intramural Artery	Godil <i>et al.</i> , 2021	1/54
Intraosseous Anastomosis	Bernardi <i>et al.</i> , 2016; Kçikü <i>et al.</i> , 2013; Yusof <i>et al.</i> , 2020; Rodella <i>et al.</i> , 2010; Solar <i>et al.</i> , 1999	5/54
Intraosseous Artery	Tran <i>et al.</i> , 2021	1/54
Intraosseous branches	Duruel <i>et al.</i> , 2019	1/54
Intraosseous branch of the Posterior Superior Alveolar Artery	de Oliveira <i>et al.</i> , 2017	1/54
Intraosseous Loop	Lee <i>et al.</i> , 2016	1/54
Intraosseous Vascular Canal	Mardinger <i>et al.</i> , 2007	1/54
Lateral Antral Intraosseous Vascular Canal	Shetty <i>et al.</i> , 2021	1/54
Posterior Superior Alveolar Artery	Anamali <i>et al.</i> , 2015; Chitsazi <i>et al.</i> , 2017; Danesh-Sani <i>et al.</i> , 2017; Güncü <i>et al.</i> , 2011; Hayek <i>et al.</i> , 2015; Hur <i>et al.</i> , 2009; Ibrahim <i>et al.</i> , 2016; Ilgüy <i>et al.</i> , 2013; Kim <i>et al.</i> , 2011; Khojastehpour <i>et al.</i> , 2016; Lozano-Carrascal <i>et al.</i> , 2017; Pandharbale <i>et al.</i> , 2016; Panjnoush <i>et al.</i> , 2017; Park <i>et al.</i> , 2012; Rostetter <i>et al.</i> , 2018; Shahidi <i>et al.</i> , 2016; Simsek Kaya <i>et al.</i> , 2018; Tehranchi <i>et al.</i> , 2017; Watanabe <i>et al.</i> , 2014; Yalcin & Akyol, 2019; Fayek <i>et al.</i> , 2021	21/54
Posterior Superior Alveolar Artery Anastomosis	Padovani <i>et al.</i> , 2020	1/54
Superior Alveolar Canal	Apostolakis <i>et al.</i> , 2014	1/54

(Rosano *et al.*, 2011). This anastomotic circuit is responsible for the vascularization of the sinus membrane, the periostic tissues, and especially the anterolateral wall of the sinus. According to Rosano *et al.* (2011) the two anastomoses (intraosseous and extraosseous) form a double arterial arch, supplying the lateral wall of the antrum and parts of the alveolar process.

In the present review it was found that the anastomosis between the PSAA and IOA was called PSAA in the majority of the studies analysed, however this term may not be the most appropriate because the artery in question is an anastomosis between the PSAA and IOA, and not the PSAA itself. Almost one third of the authors used the term AAA, showing that this term is widely accepted among researchers and anatomists. Because the anastomosis between the PSAA and IOA irrigates the maxillary sinus, it is possible that the term “antral” is an allusion to Antrum Highmorianum, the original name for the maxillary sinus.

Our findings show that there is great confusion among clinicians and anatomists about how to refer to this vascular structure, since it has 16 names. In view of the fact that this structure is always present, and the diversity of terms used to refer to it, unification of the anatomical term is imperative. We agree with Alves that this structure should be included in TA, facilitating a single term for use among clinicians, anatomists and researchers. The use of a standard anatomical terminology is fundamental for promoting clear, unequivocal communication (Neumann, 2018). This is done by the choice of an appropriate official Latin term, and recognising as synonyms other Latin terms that have been used consistently for the same anatomical structure (Neumann).

Many Symposia of Morphological Terminology (SMT) are held to unify the names applied to structures of the human body, ensure the use of common scientific language, and facilitate learning and communication between professionals (Band, 2006; Losardo *et al.*). An interesting aspect addressed in these meetings is the discussion of new terms which arise in dissection laboratories or operating theatres, and which are not yet included in TA (Cruz & Cruz). In this context, we believe that it is very important that some future SMT should discuss the inclusion in TA of the most appropriate term to designate the anastomosis between the PSAA and IOA, in order to facilitate teaching and learning and to avoid confusion in scientific communication.

Study limitations. Despite the exhaustive review carried out, there may be studies published in languages other than

Portuguese, Spanish or English, which have therefore not been included in our review. Moreover, we did not evaluate the anatomical terminology used in anatomical textbooks or books published for the use of clinicians. A strength of our study is that it shows the numerous forms used to name the anastomosis between the PSAA and IOA, corroborating the need to include this structure in TA.

CONCLUSION

Many terms are used in the medical literature to designate the anastomosis between the PSAA and IOA, the most frequent being Posterior Superior Alveolar Artery and Alveolar Antral Artery. There is a need to unify the terms used to designate this vascular structure, and to incorporate the selected term into anatomical terminology in order to avoid confusion in scientific communication.

ALVES, N.; CEBALLOS, F. & DEANA, N. F. Anastomosis entre la arteria alveolar superior posterior y la arteria infra-orbital: una revisión de la terminología actual. *Int. J. Morphol.*, 40(1):18-23, 2022.

RESUMEN: La arteria alveolar superior posterior (AASP) y la arteria infra-orbital (AIO) tienen ramas intra y extra óseas que forman una anastomosis en la pared lateral del seno maxilar. Esta anastomosis está siempre presente, sin embargo, aún no ha sido incluida en la terminología anatómica (TA), por lo que en la comunicación científica se utilizan diferentes términos para referirse a ella. El objetivo de este estudio fue realizar una revisión sobre los diferentes términos utilizados para nombrar esta estructura vascular. Se realizó una revisión de la literatura sobre los términos utilizados para nombrar la anastomosis entre AASP y AIO en estudios imagenológicos y en cadáveres humanos que evaluaron la presencia/frecuencia de esta estructura anatómica. La búsqueda fue realizada en las bases de datos Medline, EMBASE y LILACS, en los idiomas portugués, español e inglés, sin restricción de fecha. Los estudios seleccionados fueron evaluados de forma cualitativa, analizando la terminología empleada para referirse a la anastomosis entre AASP y AIO. Fueron encontrados 2108 artículos originales, siendo seleccionados 60 artículos potencialmente relevantes y finalmente fueron incluidos 54 estudios para análisis cualitativo. Fueron encontrados 16 términos para referirse a la anastomosis entre AASP y AIO, siendo AASP el más frecuente seguido de arteria alveolo-antral (AAA). Son muchos los términos utilizados en la literatura médica para designar la anastomosis entre AASP y AIO, siendo AASP y AAA los más usados. La unificación de los términos utilizados para designar esta estructura vascular y su incorporación en la Terminología Anatómica contribuiría a evitar equívocos en la comunicación científica.

PALABRAS CLAVE: Arteria alveolar superior posterior; Arteria infra-orbital; Arteria alveolo-antral; Terminología anatómica.

REFERENCES

- Al-Ghurabi, Z. H. & Abdulrazaq, S. S. Vascular precautions before sinus lift procedure. *J. Craniofac. Surg.*, 29(2):e116-e18, 2018.
- Albuquerque, D.; Manhães Junior, L.; Silva, M.; Francischone, C.E.; Franco, A. & Junqueira, J.L.C. Alveolar antral artery in edentulous patients and their visualization through cone beam computed tomography. *Morphologie*, 105(348):64-8, 2021.
- Alves, N. & Cândido, P. *Anatomia para o Curso de Odontologia Geral y Específica*. 4th ed. São Paulo, Gen-Santos, 2016.
- Alves, N. Alveolar antral artery. *Int. J. Morphol.*, 35(3):797-9, 2017.
- Alves, N.; Torres, C.; Deana, N. F. & Garay, I. Analysis of the presence, location and morphometry of the alveolar antral artery by cone-beam computed tomography in Chilean adults. *Int. J. Morphol.*, 38(6):1760-6, 2020.
- Amine, K.; Slaoui, S.; Kanice, F. Z. & Kissa, J. Evaluation of maxillary sinus anatomical variations and lesions: A retrospective analysis using cone beam computed tomography. *J. Stomatol. Oral Maxillofac. Surg.*, 121(5):484-9, 2020.
- Anamali, S.; Avila-Ortiz, G.; Elangovan, S.; Qian, F.; Ruprecht, A.; Finkelstein, M. & Allareddy, V. Prevalence of the posterior superior alveolar canal in cone beam computed tomography scans. *Clin. Oral Implants Res.*, 26(1):e8-12, 2015.
- Apostolakis, D. & Bisson, A. K. Radiographic evaluation of the superior alveolar canal: measurements of its diameter and of its position in relation to the maxillary sinus floor: a cone beam computerized tomography study. *Clin. Oral Implants Res.*, 25(5):553-9, 2014.
- Band, K. The names of the parts: the quest for a unified anatomical terminology. *Équivalences*, 33(1-2):15-32, 2006.
- Bernardi, S.; Mummolo, S.; Ciavarelli, L. M.; Li Vigni, M.; Continenza, M. A. & Marzo, G. Cone beam computed tomography investigation of the antral artery anastomosis in a population of Central Italy. *Folia Morphol. (Warsz.)*, 75(2):149-53, 2016.
- Chitsazi, M. T.; Shirmohammadi, A.; Faramarzi, M.; Esmaili, F. & Chitsazi, S. Evaluation of the position of the posterior superior alveolar artery in relation to the maxillary sinus using the Cone-Beam computed tomography scans. *J. Clin. Exp. Dent.*, 9(3):e394-9, 2017.
- Cruz Ibañez, L. A.; Palacios Vivar, D. E.; Miranda Villasana, J. E.; Cazar Almache, M. & Martínez Ojeda, P. A. CBCT evaluation of the alveolar antral artery in a Mexican cohort and its relationship to maxillary sinus floor lifting. *Rev. Asoc. Dental Mex.*, 73(6):286-90, 2016.
- Cruz, G. & Cruz, C. Sugerencias para establecer un diccionario de epónimos anatómicos, embriológicos e histológicos. *Arch. Anat. Costa Rica*, 4:28, 2009.
- Danesh-Sani, S. A.; Movahed, A.; ElChaar, E. S.; Chong Chan, K. & Amintavakoli, N. Radiographic evaluation of maxillary sinus lateral wall and posterior superior alveolar artery anatomy: a cone-beam computed tomographic study. *Clin. Implant. Dent. Relat. Res.*, 19(1):151-60, 2017.
- de Oliveira, G. J. P. L.; Abdala, M. A.; Nary-Filho, H.; Sakakura, C. E.; Garcia, V. G. & Leite, F. C. Tomographic evaluation of prevalence, position, and diameter of the intraosseous branch of the posterior superior alveolar artery in fully edentulous individuals. *J. Craniofac. Surg.*, 28(3):e279-e83, 2017.
- Dias, E. C. L. C. M.; Santos, J. B. A.; Cotrim, K. C. & de Brito, F. C. Tomographic evaluation of the prevalence of the intraosseous branch of the posterior superior alveolar artery. *J. Oral Maxillofac. Radiol.*, 7(3):60-5, 2020.
- Duque-Parra, J. E.; Barco-Ríos, J. & Aldana-Rueda, J. E. La Terminología Anatómica en Colombia y el uso de epónimos en la enseñanza en medicina. *Biosalud*, 15(1):82-6, 2016.
- Duque-Parra, J. E.; Barco-Ríos, J. & Duque-Quintero, M. La eponimia es difícil obstáculo que aún no supera la terminología anatómica internacional. *Int. J. Morphol.*, 36(4):1206-9, 2018.
- Duruel, O.; Ataman-Duruel, E. T.; Tozum, M. D.; Karabulut, E. & Tozum, T. F. The radiological evaluation of posterior superior alveolar artery topography by using computed tomography. *Clin. Implant. Dent. Relat. Res.*, 21(4):644-8, 2019.
- Ella, B.; Sédarat, C.; Noble, R. C.; Normand, E.; Lauerjat, Y.; Siberchicot, F.; Caix, P. & Zwetyenga, N. Vascular connections of the lateral wall of the sinus: surgical effect in sinus augmentation. *Int. J. Oral Maxillofac. Implants*, 23(6):1047-52, 2008.
- Fayek, M. M.; Amer, M. E. & Bakry, A. M. Evaluation of the posterior superior alveolar artery canal by cone-beam computed tomography in a sample of the Egyptian population. *Imaging Sci. Dent.*, 51(1):35-40, 2021.
- Godil, A. Z.; Devadiga, T. J.; Supnekar, S. C.; Kazi, A. I.; Wadwan, S. A. & Dugal, R. Position of posterior superior alveolar artery in relation to the maxillary sinus using cone beam computed tomography in Indian sub-population. *J. Oral Med. Oral Surg.*, 27(3):34, 2021.
- Güncü, G. N.; Yildirim, Y. D.; Wang, H. L. & Tözüm, T. F. Location of posterior superior alveolar artery and evaluation of maxillary sinus anatomy with computerized tomography: a clinical study. *Clin. Oral Implants Res.*, 22(10):1164-7, 2011.
- Hayek, E.; Nasseh, I.; Hadchiti, W.; Bouchard, P.; Moarbes, M.; Khawam, G.; Bechara, B. & Noujeim, M. Location of posterosuperior alveolar artery and correlation with maxillary sinus anatomy. *Int. J. Periodontics Restorative Dent.*, 35(4):e60-5, 2015.
- Hur, M. S.; Kim, J. K.; Hu, K. S.; Bae, H. E. K.; Park, H. S. & Kim, H. J. Clinical implications of the topography and distribution of the posterior superior alveolar artery. *J. Craniofac. Surg.*, 20(2):551-4, 2009.
- Ibrahim, A. A. & Al-Nakib, L. H. Location and diameter of the posterior superior alveolar artery among Iraqi subjects using computed tomography. *J. Dent. Med. Sci.*, 15(9):80-4, 2016.
- Ilgüy, D.; Ilgüy, M.; Dolekoglu, S. & Fisekcioglu, E. Evaluation of the posterior superior alveolar artery and the maxillary sinus with CBCT. *Braz. Oral Res.*, 27:431-7, 2013.
- Jung, J. H.; Yim, J.; Know, Y.; Al-Nawas, B.; Kim, G.; Choi, B. & Lee, D. A radiographic study of the position and prevalence of the maxillary arterial endosseous anastomosis using cone-beam computed tomography. *Int. J. Oral Maxillofac. Implants*, 26(6):1273-8, 2011.
- Kalabak, F. & Akçay, H. Evaluation of the alveolar antral artery position in the lateral sinus wall using cone-beam computed tomography. *Ann. Clin. Anal. Med.*, 11(4), 2020. DOI: <https://www.doi.org/10.4328/acam.20084>
- Khojastehpour, L.; Dehbozorgi, M.; Tabrizi, R. & Esfandnia, S. Evaluating the anatomical location of the posterior superior alveolar artery in cone beam computed tomography images. *Int. J. Oral Maxillofac. Surg.*, 45(3):354-8, 2016.
- Kim, J. H.; Ryu, J. S.; Kim, K. D.; Hwang, S. H. & Moon, H. S. A radiographic study of the posterior superior alveolar artery. *Implant. Dent.*, 20(4):306-10, 2011.
- Kolte, R. A.; Kolte, A. P.; Rahate, P. S. & Bawankar, P. V. Association of location and diameter of alveolar antral artery to crest of alveolar bone in dentate and partially edentulous patients—A cone-beam computed tomography study. *J. Indian Soc. Periodontol.*, 25(1):55-60, 2021.
- Kçiku, L.; Biblekaj, R.; Weiglein, A. H.; Kçiku, X. & Stadler, P. Arterial blood architecture of the maxillary sinus in dentate specimens. *Croat. Med. J.*, 54(2):180-4, 2013.
- Laovoravit, V.; Kretapirom, K. & Pornprasertsuk-Damrongsri, S. Prevalence and morphometric analysis of the alveolar antral artery in a group of Thai population by cone beam computed tomography. *Oral Radiol.*, 37(3):452-62, 2021.
- Lee, J.; Kang, N.; Moon, Y. M. & Pang, E. K. Radiographic study of the distribution of maxillary intraosseous vascular canal in Koreans. *Maxillofac. Plastic. Rec. Surg.*, 38(1):1-4, 2016.
- Losardo, R. J.; Prates, N. E. V. B.; Arteaga-Martínez, M.; Cabral, R. H. & García-Peláez, M. I. International Morphological Terminology: more than anatomy, histology and embryology. *Int. J. Morphol.*, 33(1):400-7, 2015.

- Lozano-Carrascal, N.; Salomo-Coll, O.; Gehrke, S. A.; Calvo-Guirado, J. L.; Hernandez-Alfaro, F. & Gargallo-Albiol, J. Radiological evaluation of maxillary sinus anatomy: A cross-sectional study of 300 patients. *Ann. Anat.*, 214:1-8, 2017.
- Mardinger, O.; Abba, M.; Hirshberg, A. & Schwartz-Arad, D. Prevalence, diameter and course of the maxillary intraosseous vascular canal with relation to sinus augmentation procedure: a radiographic study. *Int. J. Oral Maxillofac. Surg.*, 36(8):735-8, 2007.
- Mavrodi, A. & Paraskevas, G. Evolution of the paranasal sinuses' anatomy through the ages. *Anat. Cell Biol.*, 46(4):235-8, 2013.
- Neumann, P. E. Write right, quite right: orthography in latin anatomical terms. *Clin. Anat.*, 31(1):77-80, 2018.
- Padovani, L. S.; Oliveira, A. M. S. D.; Dutra, B. C.; Costa, F. O. & Oliveira, P. A. D. Important anatomical variations of the superior posterior alveolar artery: Studied by cone beam computed tomography. *Anat. Hist. Embryol.*, 49(6):798-804, 2020.
- Pandharbale, A. A.; Gadgil, R. M.; Bhoosreddy, A. R.; Kunte, V. R.; Ahire, B. S.; Shinde, M. R. & Joshi, S. S. Evaluation of the posterior superior alveolar artery using cone beam computed tomography. *Pol. J. Radiol.*, 81:606-10, 2016.
- Panjnoush, M.; Ghoncheh, Z.; Kaviani, H.; Moradzadeh Khiavi, M.; Shabbazi, N. & Kharrazifard, M. J. Evaluation of the position and course of the posterior superior alveolar artery by cone-beam computed tomography in an iranian population. *J. Islam. Dent. Assoc. Iran*, 29(3):86-92, 2017.
- Park, W. H.; Choi, S. Y. & Kim, C. S. Study on the position of the posterior superior alveolar artery in relation to the performance of the maxillary sinus bone graft procedure in a Korean population. *J. Korean Assoc. Oral Maxillofac Surg.*, 38(2):71-7, 2012.
- Rahpeyma, A. & Khajehahmadi, S. Alveolar antral artery: review of surgical techniques involving this anatomic structure. *Iran J. Otorhinolaryngol.*, 26(75):73-8, 2014.
- Rahpeyma, A.; Khajehahmadi, S. & Amini, P. Alveolar antral artery: does its diameter correlate with maxillary lateral wall thickness in dentate patients? *Iran J. Otorhinolaryngol.*, 26(76):163-7, 2014.
- Rodella, L.F.; Labanca, M.; Boninsegna, R.; Favero, G.; Tschabitscher, M. & Rezzani, R. Intraosseous anastomosis in the maxillary sinus. *Minerva Stomatol.*, 59(6):349-54, 2010.
- Rosano, G.; Taschieri, S.; Gaudy, J. F. & Del Fabbro, M. Maxillary sinus vascularization: a cadaveric study. *J. Craniofac. Surg.*, 20(3):940-3, 2009.
- Rosano, G.; Taschieri, S.; Gaudy, J. F.; Weinstein, T. & Del Fabbro, M. Maxillary sinus vascular anatomy and its relation to sinus lift surgery. *Clin. Oral Implant. Res.*, 22(7):711-5, 2011.
- Rostetter, C.; Hungerbühler, A.; Blumer, M.; Rücker, M.; Wagner, M.; Stadlinger, B. & Lübbers, H.-T. Cone-beam computed tomography evaluation of the artery in the lateral wall of the maxillary sinus: retrospective analysis of 602 sinuses. *Implant. Dent.*, 27(4):434-8, 2018.
- Rysz, M.; Cizek, B.; Rogowska, M. & Krajewski, R. Arteries of the anterior wall of the maxilla in sinus lift surgery. *Int. J. Oral Maxillofac. Surg.*, 43(9):1127-30, 2014.
- San Aung, C. M.; Panmekiat, S. & Pimkhaokham, A. The study of the alveolar antral artery canal in using cone-beam computed tomography. *M. Dent J.*, 37(1):63-9, 2017.
- Shahidi, S.; Zamiri, B.; Danaei, S.; Salehi, S. & Hamedani, S. Evaluation of anatomic variations in maxillary sinus with the aid of cone beam computed tomography (CBCT) in a population in South of Iran. *J. Dent. (Shiraz)*, 17(1):7-15, 2016.
- Shetty, S. R.; Al Bayatti, S. W.; Marei, H.; Shetty, R.; Abdelmagdy, H. A. & Luke, A. M. Cone-beam computed tomography characterization of the intraosseous vascular canal in the lateral wall of the maxillary antrum. *J. Korean Assoc. Oral Maxillofac. Surg.*, 47(1):34-9, 2021.
- Simsek Kaya, G.; Daltaban, Ö.; Kaya, M.; Kocabalkan, B.; Sindel, A. & Akdag, M. The potential clinical relevance of anatomical structures and variations of the maxillary sinus for planned sinus floor elevation procedures: a retrospective cone beam computed tomography study. *Clin. Implant. Dent. Relat. Res.*, 21(1):114-21, 2019.
- Solar, P.; Geyerhofer, U.; Traxler, H.; Windisch, A.; Ulm, C. & Watzek, G. Blood supply to the maxillary sinus relevant to sinus floor elevation procedures. *Clin. Oral Implants Res.*, 10(1):34-44, 1999.
- Sun, W.; Liu, A.; Gong, Y.; Shu, R. & Xie, Y. Evaluation of the anastomosis canal in lateral maxillary sinus wall with cone beam computerized tomography: a clinical study. *J. Oral Implantol.*, 44(1):5-13, 2018.
- Taschieri, S. & Rosano, G. Management of the alveolar antral artery during sinus floor augmentation procedures. *J. Oral Maxillofac. Surg.*, 68(1):230, 2010.
- Tran, T. B.; Estrin, N. E.; Saleh, M. H. A.; Yoon, T. Y. H.; Tattan, M. & Wang, H. L. Evaluation of length and location of the maxillary sinus intraosseous artery using computerized tomography. *J. Periodontol.*, 92(6):854-62, 2021.
- Varela-Centelles, P.; Loira-Gago, M.; Gonzalez-Mosquera, A.; Seoane-Romero, J. M.; Garcia-Martin, J. M. & Seoane, J. Distance of the alveolar antral artery from the alveolar crest. Related factors and surgical considerations in sinus floor elevation. *Med. Oral Patol. Oral Cir. Bucal*, 21(6):e758-e765, 2016.
- Watanabe, T.; Shiota, M.; Gao, S.; Imakita, C.; Tachikawa, N. & Kasugai, S. Verification of posterior superior alveolar artery distribution in lateral wall of maxillary sinus by location and defect pattern. *Quintessence Int.*, 45(8):673-8, 2014.
- Wells, W. A. Nathaniel Highmore, seventeenth century pioneer in anatomy and embryology. *Laryngoscope*, 58(6):583-97, 1948.
- Yalcin, E. D. & Akyol, S. Relationship between the posterior superior alveolar artery and maxillary sinus pathology: a cone-beam computed tomography study. *J. Oral Maxillofac. Surg.*, 77(12):2494-502, 2019.
- Yang, S. & Kye, S. Location of maxillary intraosseous vascular anastomosis based on the tooth position and height of the residual alveolar bone: computed tomographic analysis. *J. Periodontol. Implant. Sci.*, 44(2):50-6, 2014.
- Yusof, M. Y. P. M.; Mah, M. C.; Reduwan, N. H.; Kretapirom, K. & Affendi, N. H. K. Quantitative and qualitative assessments of intraosseous neurovascular canals in dentate and posteriorly edentulous individuals in lateral maxillary sinus wall. *Saudi Dent. J.*, 32(8):396-402, 2020.

Corresponding author:
N. F. Deana
Universidad de La Frontera
Faculty of Dentistry
1145 Francisco Salazar Avenue
P.O. Box 54-D.
Postal Code: 4780000
Temuco
CHILE

E-mail: naira.figueiredo@ufrontera.cl