

An Accessory Muscle of the Posterior Compartment of Leg of Clinical Significance: A Cadaveric Case Report

Un Músculo Accesorio del Compartimento Posterior de la Pierna de Importancia Clínica: Reporte de un Caso Cadavérico

J. Maggard; T. Zarbock & M. Jorgensen

MAGGARD, J.; ZARBOCK, T. & JORGENSEN, M. An accessory muscle of the posterior compartment of leg of clinical significance: A cadaveric case report. *Int. J. Morphol.*, 39(4):1054-1057, 2021.

SUMMARY: Accessory and anomalous muscles are common in humans, although their unique morphologic characteristics can make accurate identification difficult. In this case report, we attempt to identify an anomalous accessory muscle of the posterior compartment of the leg [Compartimentum posterius cruris] detected during cadaveric dissection and discuss its clinical significance. The muscle was found on the right lower limb of an 81-year-old female cadaver and extended from the distal femur to attach to the gastrocnemius muscle at the point where the medial and lateral heads fuse. At its origin, the muscle was found lateral to the popliteal vessels and crossed posterior to these vessels and tibial nerve. It displayed characteristics similar to both an accessory plantaris muscle and gastrocnemius tertius, thus making its ultimate identification difficult. Though the muscle displayed a morphologically similar appearance to the plantaris, we suggest that its common insertion with the gastrocnemius best identifies it as a gastrocnemius tertius. In addition, due to its relationship with the popliteal neurovasculature, it is possible that this muscle could have resulted in neurovascular entrapment although it is unknown whether or not this cadaver exhibited symptoms.

KEY WORDS: Human gastrocnemius tertius; Accessory head of gastrocnemius; Plantaris; Accessory plantaris.

INTRODUCTION

Accessory and anatomically anomalous muscles are relatively common in humans, though due to their unique morphologic characteristics and inconsistent appearance, ultimate identification of these muscles can be difficult. Clinical significance is based on the location of these muscles and their relationship to surrounding structures. In this case report, we describe an accessory muscle with unique morphology found at the level of the knee in a female cadaver.

MATERIAL AND METHOD

During the routine dissection of the left lower limb of an 81-year-old female cadaver we observed a unilateral anomalous muscle belly originating from the distal femur and extending inferior to join the gastrocnemius muscle. The muscle was displayed through meticulous dissection and all surrounding structures were defined. The left lower limb was noted to display normal anatomy.

RESULTS

On the right-side lower limb, the additional muscle belly was discovered just medial to the plantaris muscle and was noted to be similar in morphology. The muscle belly originated from the lateral aspect of the intercondylar fossa of the femur, superior and medial to the origin of the plantaris muscle (Fig. 1). It then extended inferior to join the gastrocnemius muscle via a tendinous insertion at the point where the medial and lateral heads of the gastrocnemius fuse (Fig. 2). The muscle belly and its tendon measured 13.4 cm and 3.8 cm, respectively.

At its origin, it was noted to lie lateral to the popliteal vessels and travel inferomedial to cross the posterior aspect of the vessels and tibial nerve to its insertion. Small muscular branches of the tibial nerve were noted to enter the substance of the muscle belly. The superior lateral genicular artery and vein were also noted to pierce the substance of the muscle near its origin before continuing lateral along the lateral aspect of the femur in their usual course (Figs. 3 and 4).

Dissection of the right lower limb of this cadaver revealed no additional muscle belly or atypical morphology.

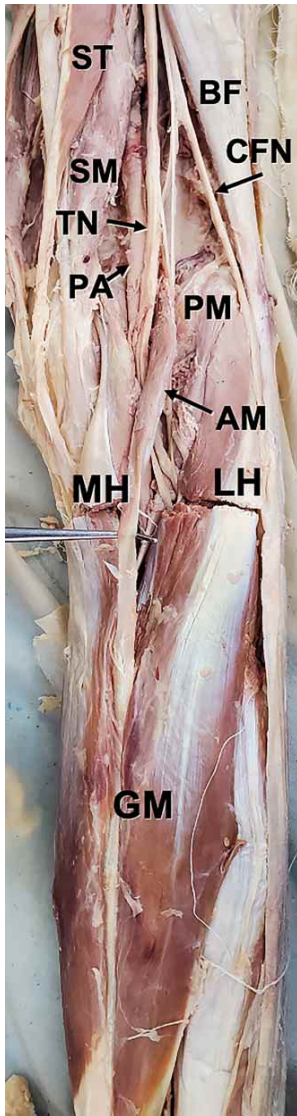


Fig. 1. Accessory muscle held by forceps demonstrating medial origin and course in relation to the plantaris muscle. AM: anomalous muscle, LH: lateral head of gastrocnemius, MH: medial head of gastrocnemius, PA: popliteal artery, PM: plantaris muscle, TN: tibial nerve.

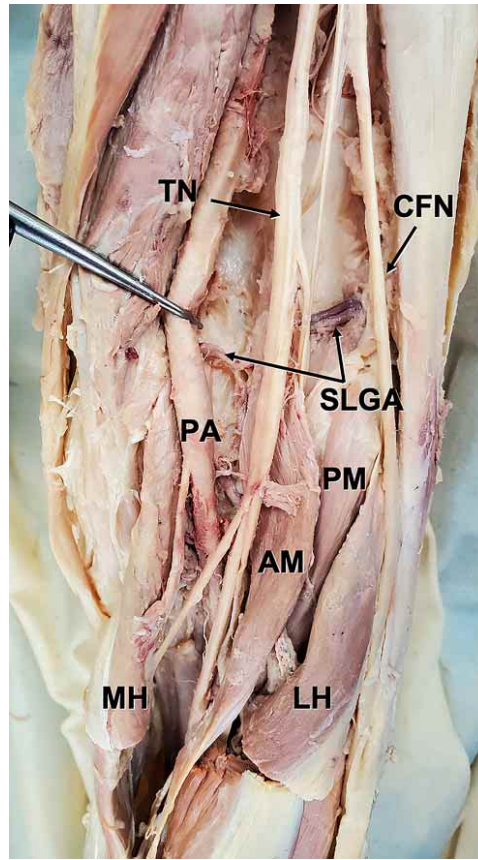


Fig. 2. Accessory muscle elevated by metal probe demonstrating inferomedial course and relationship to popliteal neurovascular structures. AM: anomalous muscle, BF: biceps femoris, CFN: common fibular nerve, GM: gastrocnemius muscle, LH: lateral head of gastrocnemius, MH: medial head of gastrocnemius, PA: popliteal artery, PM: plantaris muscle, SM: semimembranosus, ST: semitendinosus, TN: tibial nerve.

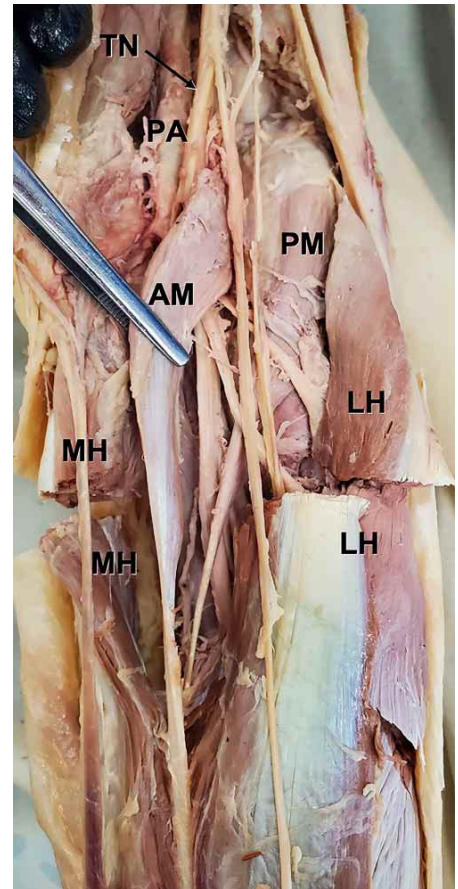


Fig. 3. Popliteal artery pulled medial by metal probe to allow visualization of superior lateral genicular artery. AM: anomalous muscle, CFN: common fibular nerve, LH: lateral head of gastrocnemius, MH: medial head of gastrocnemius, PA: popliteal artery, PM: plantaris muscle, SLGA: superior lateral genicular artery, TN: tibial nerve.

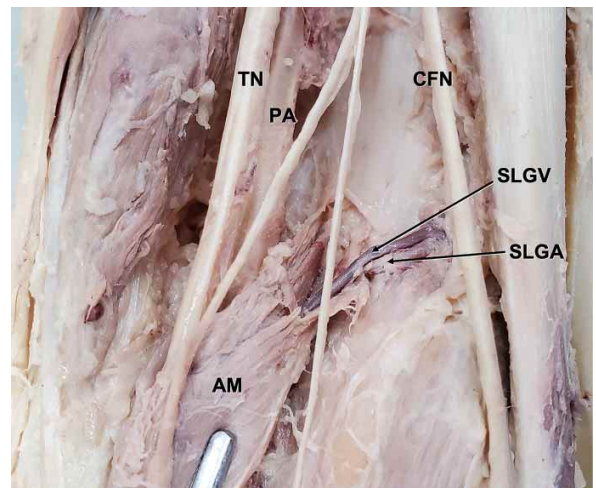


Fig. 4. Demonstration of superior lateral genicular artery and vein piercing the substance of the anomalous muscle belly near its origin. AM: anomalous muscle, CFN: common fibular nerve, PA: popliteal artery, SLGA: superior lateral genicular artery, SLGV: superior lateral genicular vein, TN: tibial nerve.

DISCUSSION

The plantaris muscle is considered to be a vestigial muscle of human development originally attaching to the plantar aponeurosis and assisting in flexion of the toes. Through human evolution and bipedal development, it is theorized that an eventual attachment to the calcaneus was developed (Daseler & Anson, 1943). The plantaris receives innervation via branches of the tibial nerve and blood supply from muscular branches of the popliteal artery.

In a retrospective study of 1,000 MRI exams of the knee conducted by Herzog (2011), the presence of an accessory plantaris muscle was found at a rate of 6.3 % with no statistically significant difference of muscle presence between males and females. The origin of the accessory plantaris muscle merged with the normal plantaris muscle in all cases but one, which merged with the origin of the lateral gastrocnemius. For insertion, 43 of the accessory muscles inserted onto the iliotibial band, 15 into the lateral patellar retinaculum, and 5 onto the iliotibial tract. Size was variable from a thin band-like muscle to a thick fusiform appearance.

The gastrocnemius is one of the primary plantar flexors of the posterior compartment of leg [Compartimentum posterius cruris]. It is traditionally divided into a medial and lateral head which originate from the posterior surfaces of the medial and lateral femoral condyles, respectively. The muscle then inserts on the calcaneus. Due to the fact that the muscle crosses the knee joint, in addition to plantar flexing the ankle joint, it is capable of flexing the knee joint. It receives innervation via the tibial nerve and blood supply from the sural branches of the popliteal artery.

An accessory head of gastrocnemius has been described in case reports as gastrocnemius tertius. This muscle arises from the popliteal surface of the femur and attaches distally at the junction of the two heads of the gastrocnemius. This muscle variant was first described by Kelch (1813) but expanded by Bergman *et al.* (1995). The overall frequency of occurrence was found to be between 1.7 % and 5.5 % (Bergman *et al.*).

The origin of the muscle in our specimen appears similar to that described by Herzog of the accessory plantaris, though the origin described by Bergman *et al.* for a gastrocnemius tertius at the posterior popliteal surface of the femur would also seem to describe the muscle. The muscle's insertion between the heads of gastrocnemius lends credence to the possibility of a gastrocnemius tertius as the identity, though morphology is much more similar to that of

an accessory plantaris. Because the plantaris and gastrocnemius are both innervated by the tibial nerve, the innervation via muscular branches of the tibial nerve is not overtly helpful in identification.

Adding to the potential confusion for identification of the muscle, studies by Upasna & Kumar (2011) have described fibers of the plantaris merging with the bellies of the gastrocnemius, lending credence to the hypothesis the plantaris itself may be an evolutionary third head of the gastrocnemius.

Much more literature is available on the clinical significance of the plantaris than the gastrocnemius and its accessory muscles. For surgeons operating in the area, a good anatomic understanding of the plantaris is necessary, as its long tendon can be easily mistaken as a nerve. In addition, the presence of a bicipital plantaris may confuse clinicians when operating in the area, making prior diagnosis essential (Rana *et al.*, 2006).

A study conducted by Ogawa *et al.* (2005), into the innervation of the gastrocnemius tertius described the morphology of the muscles they dissected. Of 158 dissected legs, the accessory muscle was found in 6. They describe a morphologic appearance similar to that of the muscle found in this cadaver, with the origin of the muscle from the popliteal surface and insertion into one of the heads of gastrocnemius or into both. Innervation to the muscle was identified via the tibial nerve.

Though likely an example of a gastrocnemius tertius, the plantaris-like morphology of the muscle necessitates consideration of both the roles of the plantaris and gastrocnemius when discussing clinical significance. Due to the relationship of the fibers of the plantaris tendon to those of the Achilles tendon, it is hypothesized that the muscle plays a role in symptomatic Achille's tendinopathy as described by van Sterkenburg *et al.* (2011). It is possible that the tendon of this accessory muscle could behave in much the same way, increasing the risk for tendinopathy. While rupture of the plantaris muscle is not itself an emergent condition, it can be associated with bleeding and swelling, resulting in compartment syndrome and requiring fasciotomy. Rupture of the plantaris muscle is also a common mimic of deep vein thrombosis, ruptured baker's cyst, and calf neoplasm. This differential dramatically increases the utility of doppler imaging in order to rule out the immediately life-threatening condition of DVT. Oftentimes, the presentation of plantaris is significantly more acute and is associated with a "popping" sensation preceding the pain. Conversely, DVT is often associated with a more insidious onset of pain. Physical exam of the ruptured plantaris may

reveal a retracted mass in the popliteal region while physical exam of DVT may result in color change, warmth, and increased leg circumference described in earlier reports by Rohilla *et al.* (2013). All of these clinical symptoms could in theory be replicated by the accessory muscle presented here. Finally, when the muscle crosses over neurovasculature, as it does in this case, entrapment syndromes can occur. Symptoms include leg swelling, aching pain, or tenderness of the popliteal fossa (Yildirim *et al.*, 2011). Evaluation may reveal decreased pulse of the distal arteries with dorsiflexion of the ankle. Doppler evaluation can be helpful to evaluate for neurovascular compression.

ACKNOWLEDGEMENTS

We thank Jen Fisher for her assistance acquiring copies of literature used in this study.

MAGGARD, J.; ZARBOCK, T. & JORGENSEN, M. Un músculo accesorio del compartimento posterior de la pierna de importancia clínica: reporte de un caso cadavérico. *Int. J. Morphol.*, 39(4):1054-1057, 2021.

RESUMEN: Los músculos accesorios y anómalos son comunes en los seres humanos, aunque sus características morfológicas pueden dificultar la identificación precisa. En este reporte de caso, intentamos identificar un músculo accesorio anómalo del compartimento posterior de la pierna [*Compartimentum posterius cruris*] detectado durante la disección cadavérica y discutir su importancia clínica. El músculo fue encontrado en el miembro inferior derecho de una mujer de 81 años de edad y se extendía desde la parte distal del fémur para unirse al músculo gastrocnemio en la fusión de sus cabezas medial y lateral. En su origen, el músculo se encontraba lateral a los vasos poplíteos y cruzaba posteriormente a estos vasos y al nervio tibial, presentando características similares tanto al músculo plantar accesorio como al gastrocnemio tercero, lo que dificultaba su identificación final. Similar al músculo plantar, sugerimos que debido a su inserción común con el gastrocnemio lo identifica mejor como un músculo gastrocnemio tercero. Además, debido a su relación con la neurovasculatura poplíteo, es posible que este músculo haya dado lugar a un síndrome de compresión neurovascular aunque se desconoce si este individuo presentó síntomas o no en vivo.

PALABRAS CLAVE: Tercio gastrocnemio humano; Cabeza accesoria de gastrocnemio; Plantaris; Plantaris accesorio.

REFERENCES

Bergman, R. A.; Walker, C. W. & el-Khour, G. Y. The third head of gastrocnemius in CT images. *Ann. Anat.*, 177(3):291-4, 1995.

Daseler, E. H. & Anson, B. J. The plantaris muscle. An anatomical study of 750 specimens. *J. Bone Joint Surg.*, 25(4):822-7, 1943.
Herzog, R. J. Accessory plantaris muscle: anatomy and prevalence. *HSS J.*, 7(1):52-6, 2011.
Ogawa, K.; Yatsunami, M.; Irie, Y.; Tai, T.; Tsujita, N.; Tachibana, K. & Miyauchi, R. A morphological study of the human gastrocnemius tertius muscle. *Med. Bull. Fukuoka Univ.*, 32(3):81-8, 2005.
Rana, K. K.; Das, S. & Verma, R. Double plantaris muscle: a cadaveric study with clinical importance. *Int J Morphol*, 24(3):495-8, 2006.
Rohilla, S.; Jain, N. & Yadav, R. Plantaris rupture: why is it important? *BMJ Case Rep.*, 2013:bcr2012007840, 2013.
Upasna & Kumar, A. Bicipital origin of plantaris muscle – a case report. *Int. J. Anat. Var.*, 4:177-9, 2011.
van Sterkenburg, M. N.; Kerkhoffs, G. M. M. J.; Kleipool, R. P. & Niek van Dijk, C. The plantaris tendon and a potential role in mid-portion Achilles tendinopathy: an observational anatomical study. *J. Anat.*, 218(3):336-41, 2011.
Yildirim, F. B.; Sarikcioglu, L. & Nakajima, K. The co-existence of the gastrocnemius tertius and accessory soleus muscles. *J. Korean Med. Sci.*, 26(10):1378-81, 2011.

Corresponding author:

Dr. Mike Jorgensen
Department of Clinical Anatomy
and Osteopathic Principles and Practice
Rocky Vista University
8401 S Chambers Rd.
Parker
Colorado 80134
USA

E-mail: mjorgensen@rvu.edu

Received: 26-02-2021

Accepted: 04-05-2021