

# Effects of Vitamin E on the Epithelial-Mesenchymal Transition in Testicular Development Exposed to Valproic Acid

## Efectos de la Vitamina E en la Interacción Epitelio-Mesenquimático en el Desarrollo Testicular Expuesto a Ácido Valproico

Daniel Conei<sup>1,2,3</sup>; Mariana Rojas<sup>2</sup>; Luis Santamaría<sup>4</sup> & Jennie Risopatrón<sup>5,6</sup>

**CONEI, D.; ROJAS, M.; SANTAMARÍA, L. & RISOPATRÓN, J.** Effects of vitamin E on the epithelial-mesenchymal transition in testicular development exposed to valproic acid. *Int. J. Morphol.*, 39(4):947-955, 2021.

**SUMMARY:** In testicular differentiation, somatic cells must adopt a specific destiny towards sustentacular, peritubular and interstitial cells, being fundamental for the morphogenesis of seminiferous tubules, mediated by morphogens such as Desert Hedgehog (DHH), insulin-like growth factor-1 (IGF-1) and fibroblastic growth factor 2 (FGF-2). Its alteration could be related to failures in the development mechanisms, such as those caused by valproic acid (VPA), which can be reversed with vitamin E (VE). The objective of the study was to evaluate the epithelial-mesenchymal transition (EMT) in the testicular development of mice exposed to VPA and VE. 12 groups of pregnant female mice were formed that were separated by days post-coital (dpc) at 12.5 dpc, 17.5 dpc and 6 weeks postnatal, each one subdivided into 4 groups of 5 pregnant women each. Subgroups received different treatments from the beginning to the end of gestation orally: 600 mg/kg of VPA, 600 mg/kg of VPA and 200 IU of VE, 200 IU of VE and the control group 0.3 mL of 0.9% physiological solution. Immunohistochemistry was performed for the detection of DHH, IGF-1 and FGF-2. Immunolocalization of DHH was observed in all stages, with more evident significant differences in integrated optical density (IOD) and percentage of immunoreaction area at 6 weeks postnatal, being lower in the VPA group. In IGF-1, lower intensity and distribution of immunostaining was observed in the fetal and pubertal stages in the VPA groups, a similar situation with FGF-2, but only evident at 17.5 dpc, with significant differences. These results demonstrate that VPA can alter EMT between somatic cells in testicular development, with VE being an agent capable of attenuating this process.

**KEY WORDS:** Epithelial-mesenchymal transition; Desert Hedgehog; Insulin-like Growth Factor-1; Fibroblastic Growth Factor 2; Valproic acid.

## INTRODUCTION

Sexual differentiation in XY mammals is the result of a sequential process based on the establishment of sex chromosomes, formation of the gonadal crest, migration of primordial germ cells (PGCs) and the morphological sexual differentiation of the gonad, mediated by genetic factors (O'Shaughnessy & Fowler, 2014). Among the first somatic cells to adopt a specific destination are the sustentacular cells (of Sertoli), being surrounded by peritubular cells (myoids) that make up the wall of the testicular cord, and subsequently triggering the differentiation of interstitial cells (of Leydig), fulfilling steroidogenic functions (Lucas-Herald &

Bashamboo, 2014). In this morphogenesis of seminiferous tubules, epithelial-mesenchymal transitions (EMTs) must occur between populations of developing testicular cells through morphogens. For example, the differentiation of the interstitial cells is regulated by Desert Hedgehog (DHH), secreted by sustentacular cells, producing a marriage of events that intervene with the expansion of the testicular cord (Pierucci-Alves *et al.*, 2001). Meanwhile, fibroblast growth factor 2 (FGF-2) regulates the EMT of sustentacular and peritubular cells during the formation of testicular cords, affecting the remodeling of the basement membrane (El

<sup>1</sup> Doctoral Program in Morphological Sciences, Faculty of Medicine, Universidad de La Frontera, Temuco, Chile.

<sup>2</sup> Comparative Embryology Laboratory, Anatomy and Developmental Biology Program, Institute of Biomedical Sciences, Faculty of Medicine, Universidad de Chile, Santiago, Chile.

<sup>3</sup> Department of Health Sciences, Universidad de Aysén, Coyhaique, Chile.

<sup>4</sup> Department of Anatomy, Histology and Neuroscience, Faculty of Medicine, Universidad Autónoma de Madrid, Madrid, Spain.

<sup>5</sup> Center of Biotechnology on Reproduction (CEBIOR-BIOREN), Faculty of Medicine, Universidad de La Frontera, Temuco, Chile.

<sup>6</sup> Department of Basic Sciences, Faculty of Medicine, Universidad de La Frontera, Temuco, Chile.

Ramy *et al.*, 2005). Furthermore, sustentacular cells have a paracrine effect on interstitial cells through insulin-like growth factor 1 (IGF-1), which generates an increase in the availability of cholesterol for steroidogenesis and the activity of steroidogenic enzymes (Griffeth *et al.*, 2014).

Alterations in these processes cause reduction of testicular somatic cell populations, decrease in androgen production, and defects in testicular descent, genital atrophy and development of ambiguous external genitalia (Bitgood *et al.*, 1996; Wang *et al.*, 2003), compromising the survival of gonocytes throughout testicular development (Jiang *et al.*, 2013). An agent that could alter these interactions is oxidative stress, leading to abnormalities that can have an impact on PGCs and can have long-term consequences in the mature organism, depending on the timing of these events (Dennerly, 2004). In addition, PGCs and somatic cells have little capacity to protect themselves against oxidative stress, making them particularly sensitive to these changes (Aitken & Baker, 2006). For its protection, the administration of non-enzymatic antioxidants, such as vitamin E (VE), is recommended, since it is capable of suppressing lipid peroxidation in testicular microsomes and mitochondria and reverses the damaging effects of oxidative stress on the testicular function (Senthil kumar *et al.*, 2004; Gavazza & Catalá, 2006).

Some teratogens, such as valproic acid (VPA), a broad spectrum antiepileptic drug, can cause alterations in oxidative stress such as a decrease in glutathione peroxidase in the germinal epithelium in rats treated with VPA and decrease VE levels (Al Deeb *et al.*, 2000; Khan *et al.*, 2011). Various studies have shown histopathological alterations in seminiferous tubules, a greater number of morphologically abnormal sperm, increased cell apoptosis, and less testicular volume (Nishimura *et al.*, 2000; Sveberg Røste *et al.*, 2001; Isojärvi *et al.*, 2004; Hamed *et al.*, 2015). Therefore, the objective of the study is to evaluate the EMT in testicular development in embryos, fetuses and mice 6 weeks postnatal exposed to VPA and VE.

## MATERIAL AND METHOD

This study was approved by the Scientific Ethics Committee of the Universidad de La Frontera, Temuco, Chile, act n°122\_18. 60 pregnant adult female mice strain BALB/c were used, from the Bioterium of Doctorate Program in Morphological Sciences of Universidad de La Frontera, which remained in environmental conditions of 22±2 °C, 50-70 % humidity and a light/dark cycle of 12 h, being fed with standard laboratory diet AIN-93M (Reeves *et al.*, 1993) and water on demand. Controlled crosses were

made with healthy breeding males. To verify pregnancy, the presence of the mucous plug in the vaginal introitus was observed, considering day 0.5 post-coital (dpc).

Twelve groups, 5 mice each were randomly formed. Of them, they were divided according to post-coital age at 12.5 dpc, 17.5 dpc and 6 weeks postnatal. At each stage, one group received the following oral treatment from the beginning to the end of gestation: 600 mg/kg of VPA (Atemperator®, Recalcine® Laboratory); 600 mg/kg of VPA and 200 IU of VE (Laboratorio Fasa®); 200 IU of VE and 0.3 mL of 0.9 % physiological solution. For the calculation of the doses, the bodyweight of the animals was measured daily with an IKA C-MAGHS7 scale. At 12.5 dpc and 17.5 dpc, xylazine was euthanized at a dose of 10 mg/kg and ketamine at a dose of 80 mg/kg intraperitoneally 3 times, and cervical dislocation was performed to confirm euthanasia (American Veterinary Medical Association, 2013). Uterine dissection was performed and embryos and fetuses were removed, respectively. At 6 weeks postnatal the same method was performed, extracting testicles, in which the length of the three axes of the testicular ellipsoid was estimated.

Subsequently, the samples were fixed in buffered formalin (1.27 mol / L formaldehyde in 0.1 M phosphate buffer saline pH 7.2) at 10 % for 48 hours, dehydrated and included in Paraplast Plus (Sigma-Aldrich Co., St Louis, MO, USA). Serial cross sections of 5 µm thickness were made on a microtome (Microm HM 325), mounting on xylanized positively charged slides (Citoglas®). Immunohistochemical technique was performed. To do this, the sections were deparaffinized and rehydrated for 30 minutes. Endogenous peroxidase blocking was performed with 0.3 % hydrogen peroxide in PBS pH 7.4. The primary antibodies anti-DHH (polyclonal antibody DHH, N17, sc-33940, Santa Cruz Biotechnology) anti-FGF-2 (monoclonal antibody FGF-2, C-2, sc-74412, Santa Cruz Biotechnology), anti-IGF-1 (monoclonal antibody IGF-1, PA5-27207, invitrogen), at 1:100 dilution in PBS pH 7.4, 1 % bovine serum albumin (BSA) and 0.1 % sodium azide, to evaluate the EMTs between sustentacular, peritubular and interstitial cells. Antigenic recovery was performed in citrate buffer pH 6.0 in microwaves. The primary antibody was incubated overnight at 4 °C. As secondary antibody, the polymer conjugated in HRP (Super Picture HRP Polymer Conjugate Broad Spectrum, Life Technologies, 878963) was used, incubating at room temperature for 30 minutes. As a substrate for HRP, diaminobenzidine (DAB, Vector Labs) was used for 1-2 minutes. The negative control was given by the development of the complete immunohistochemical technique, but without considering the primary antibodies. Serial cross sections were analyzed if they were positively marked and were described morphologically.

The slides were visualized with an Olympus microscope with motorized stage controlled by Cast-Grid stereological software (Stereology Software Package, Silkeborg, Denmark). Images in JPEG format were obtained with a 12.5 megapixel DP 70 digital camera (Olympus Corporation of the Americas, PA, USA). Using the ImageJ program (NIH, Bethesda, MD, USA), the images were processed serially in 8-bit and with the threshold tool it was adjusted to determine the areas of positive labeling for the respective antibodies. After grayscale calibration, the integrated optical density (IOD) was determined for each positively labeled antibody. Subsequently, the images were processed in the Adobe Photoshop 2020 program (Adobe Systems, Inc., Mountain View, CA, USA) to readjust the background and through the Amira 6.3.0 program (Visage Imaging GmbH, Berlin, Germany) for the 3D reconstruction according to previous models (Nakata *et al.*, 2017; Nakata *et al.*, 2020). Serial images were automatically aligned followed by manual adjustment, having as a reference point the testicular cords or seminiferous tubules, as appropriate, optimizing the visualization of the positive labeling of the respective antibody. Once reconstructed, the percent positive area (%) for immunostaining was determined with the ImageJ program (NIH, Bethesda, MD, USA).

For statistical analysis, variables are presented as mean  $\pm$  standard deviation. The Kolmogorov-Smirnov

normality test was used. Depending on the normality of the data, the differences between the groups were analyzed through one-way ANOVA, followed by Tukey's Post Hoc HSD test, or the Kruskal Wallis test, as appropriate. A p value  $<0.05$  was considered statistically significant (GraphPad Prism Software Inc., 9.0, USA).

## RESULTS

DHH immunolocalization was observed in all stages studied. At 12.5 dpc, there was diffuse cytoplasmic marking in all samples, both in germline and somatic cells in all groups. In 17.5 dpc fetuses with different treatments, this marking was concentrated in interstitial cells and was weak in pre-spermatogonia. In the pubertal stage at 6 weeks postnatal, a very weak marking is observed in the group treated with VPA in the interstitial space. In the groups treated with VE and control, there was a strong marking (Fig. 1). Regarding the intensity of immunostaining, statistically significant differences were observed in the embryos treated with VPA and only VE compared to those treated with VPA+VE, but not with the control. At the 17.5 dpc stage, the IOD was lower in the VPA group, with statistical significance compared to the rest of the groups. The same situation was observed in the pubertal groups (Fig. 2A). In

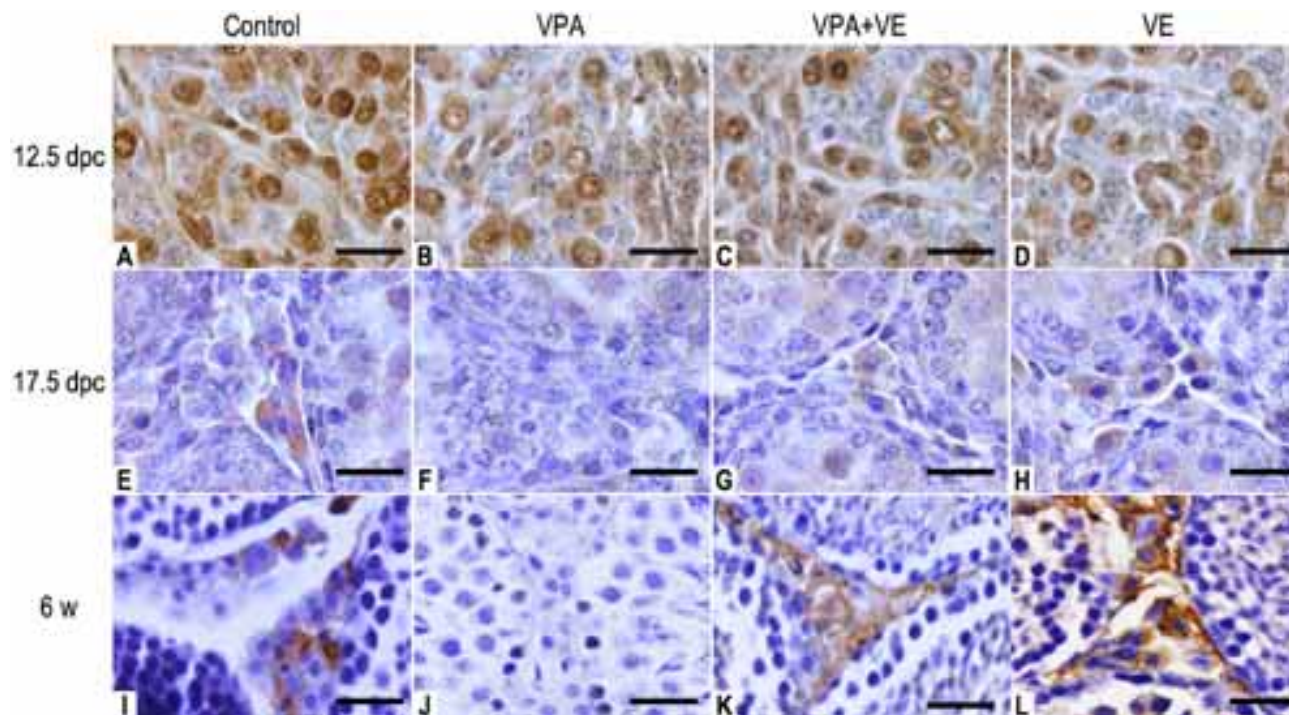
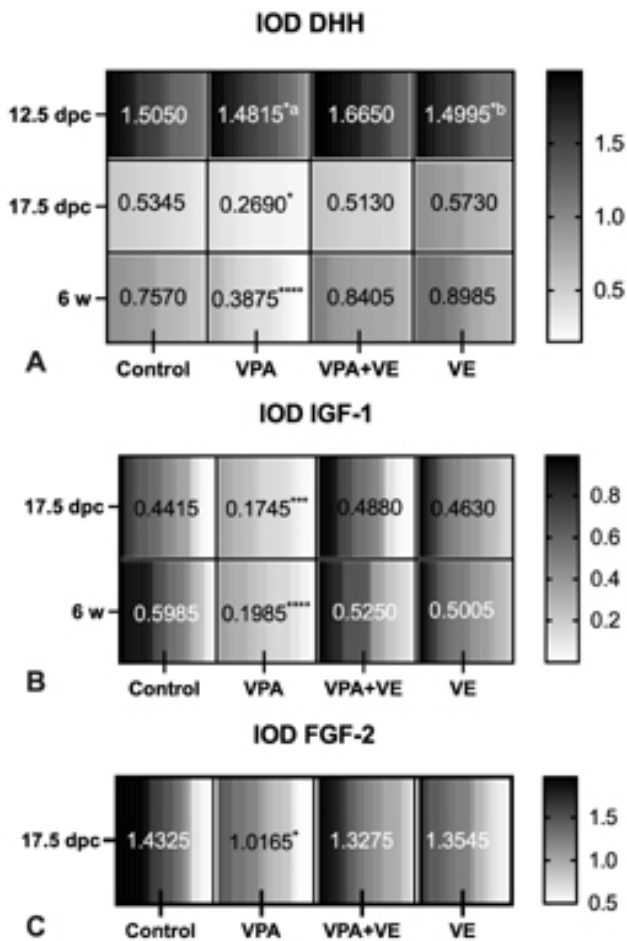


Fig. 1. Anti-DHH immunohistochemistry. Comparison between control groups, valproic acid (VPA), valproic acid and vitamin E (VPA+VE) and vitamin E (VE). In A to D groups of 12.5 days post-coital (dpc). In E to H groups of 17.5 dpc. In I to L groups of 6 weeks postnatal (w). Scale bar 20  $\mu$ m.



the 3D reconstruction, differences in the percentage of immunoreactivity to DHH were determined at 17.5 dpc only between VPA and VE groups, presenting a lower percentage. At 6 weeks postnatal the percentage of DHH distribution was lower in the VPA group compared to the rest of the treatment, with  $p < 0.05$  (Fig. 3).

Fig. 2. Determination of integrated optical density immunoreactivity (IOD) to DHH, IGF-1 and FGF-2. Comparison between control groups, valproic acid (VPA), valproic acid and vitamin E (VPA+VE) and vitamin E (VE) at 12.5 days post-coital (dpc), 17.5 dpc and 6 weeks post-natal (w). In A, IOD for DHH. In B, IOD for IGF-1. In C, IOD for FGF-2. (a) and (b) comparison with the VPA + VE group. Other statistical differences compared to the rest of the groups. (\*)  $p < 0.05$ ; (\*\*\*)  $p < 0.005$ ; (\*\*\*\*)  $p < 0.0001$ . One-way ANOVA and Tukey's test of multiple comparisons.

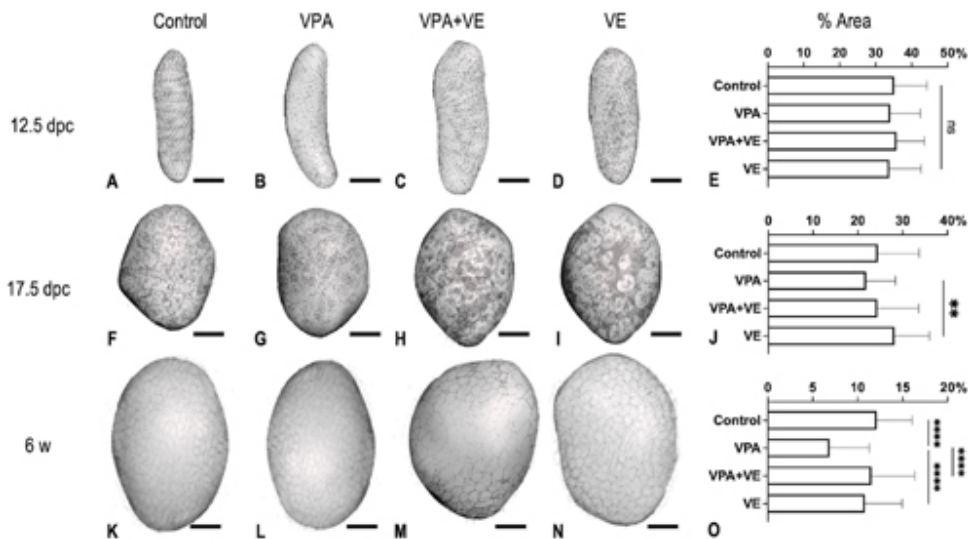


Fig. 3. 3D reconstruction of anti-DHH immunohistochemical labeling. Comparison between control groups, valproic acid (VPA), valproic acid and vitamin E (VPA+VE) and vitamin E (VE). In A to E groups of 12.5 days post-coital (dpc). Scale bar 1 mm. In F to J groups of 17.5 dpc. Scale bar 1 mm. In K to O groups of 6 weeks postnatal (w). Scale bar 5 mm. In E, J and O comparison of the percentage (%) of immunoreaction area. (ns) not significant; (\*\*)  $p < 0.01$ ; (\*\*\*\*)  $p < 0.0001$ . One-way ANOVA and Tukey's test of multiple comparisons.

For IGF-1, immunostaining was evident at 17.5 dpc and 6 weeks postnatal. This was located in the interstitial tissue, in the cytoplasm of the interstitial cells, being weaker in the group treated with VPA (Fig. 4). IOD demonstrated a lower intensity of the immunoreaction in the VPA groups in both stages, with statistically significant differences (Fig. 2B). The distribution of IGF-1 marking in all testicular tissue was also lower in the VPA group compared to the other groups, with  $p < 0.05$  (Fig. 5).

In the case of FGF-2, there was no marking in the 12.5 dpc and 6 weeks postnatal groups. At 17.5 dpc, there was a strong nuclear pattern in sustentacular cells, medium weak in peritubular cells and weaker in interstitial cells, in all groups (Fig. 6). This marking was less intense in the VPA group compared to the rest,  $p < 0.05$  (Fig. 2C) and widely distributed in the testicular tissue. However, presenting a lower percentage of area in the VPA group, with significant differences compared to the other groups (Fig. 7).

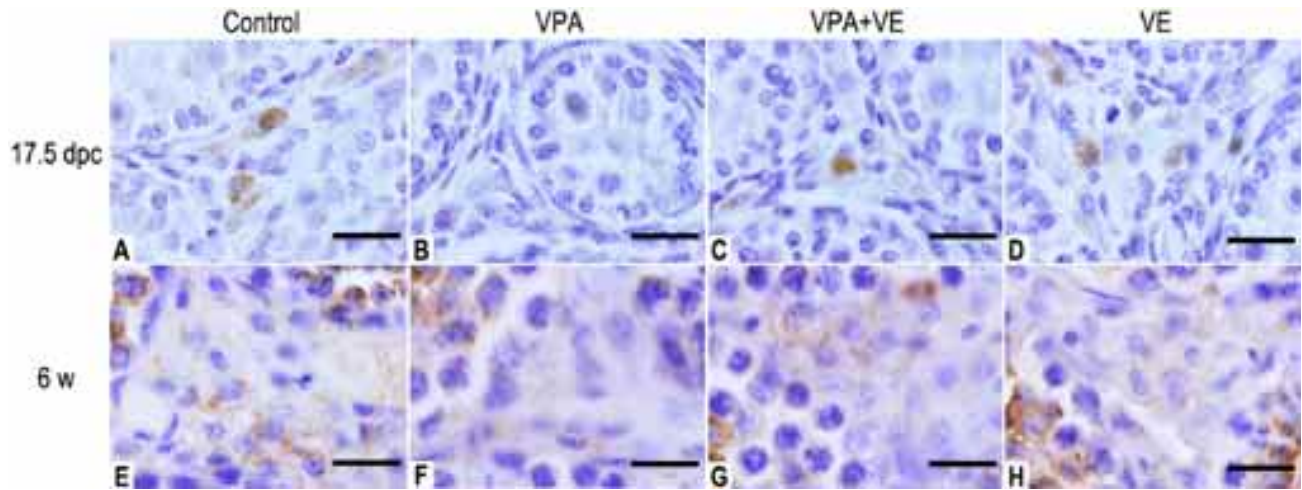


Fig. 4. Anti-IGF-1 immunohistochemistry. Comparison between control groups, valproic acid (VPA), valproic acid and vitamin E (VPA+VE) and vitamin E (VE). In A to D groups of 17.5 days post-coital (dpc). In E to H groups of 6 weeks postnatal (w). Scale bar 20  $\mu$ m.

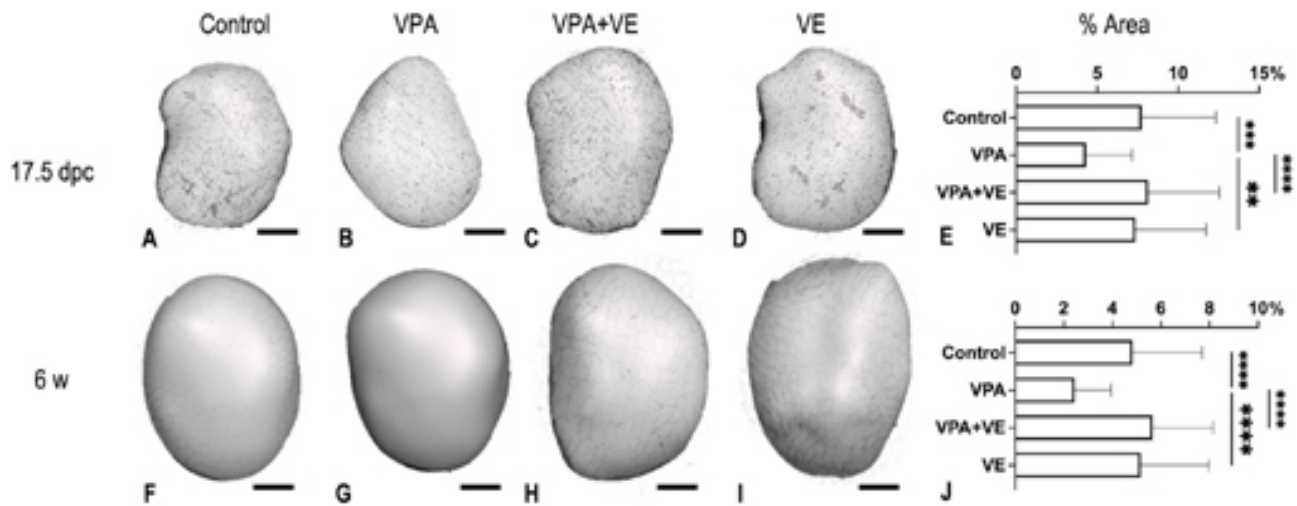


Fig. 5. 3D reconstruction of anti-IGF-1 immunohistochemical labeling. Comparison between control groups, valproic acid (VPA), valproic acid and vitamin E (VPA+VE) and vitamin E (VE). In A to E groups of 17.5 days post-coital (dpc). Scale bar 1 mm. In F to J groups of 6 weeks postnatal (w). Scale bar 5 mm. In E and J comparison of the percentage (%) of immunoreaction area. (ns) not significant; (\*)  $p < 0.05$ ; (\*\*)  $p < 0.01$ ; (\*\*\*)  $p < 0.005$ ; (\*\*\*\*)  $p < 0.0001$ . One-way ANOVA and Tukey's test of multiple comparisons.

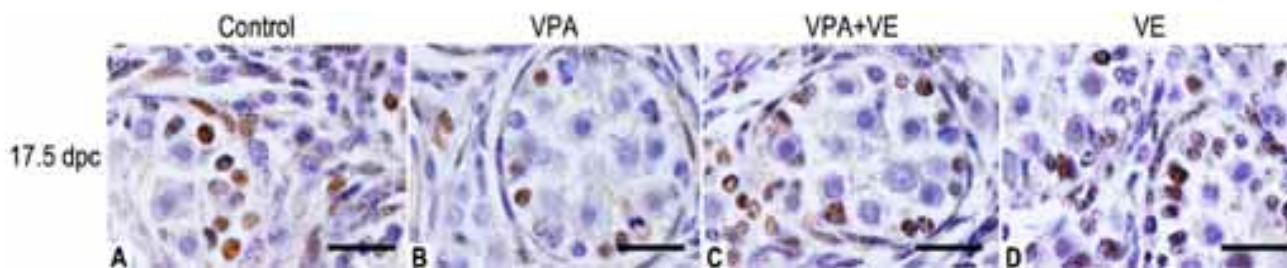


Fig. 6. Anti-FGF-2 immunohistochemistry. Comparison between control groups, valproic acid (VPA), valproic acid and vitamin E (VPA+VE) and vitamin E (VE). In A to D groups of 17.5 days post-coital (dpc). Scale bar 20  $\mu$ m.

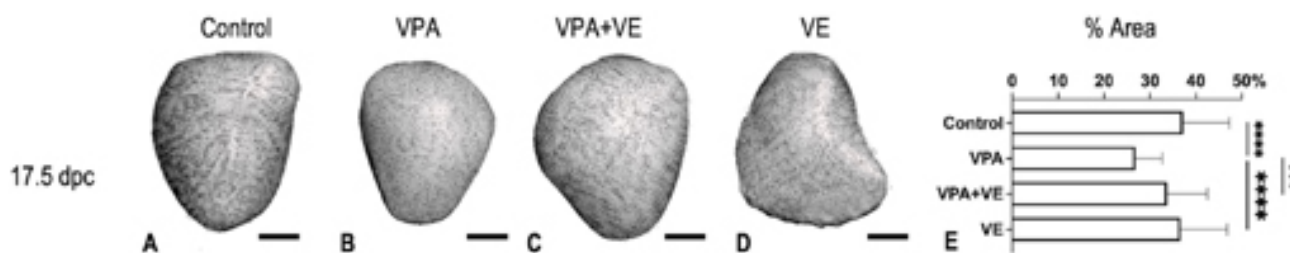


Fig. 7. 3D reconstruction of anti-FGF-2 immunohistochemical labeling. Comparison between control groups, valproic acid (VPA), valproic acid and vitamin E (VPA+VE) and vitamin E (VE). In A to E groups of 17.5 days post-coital (dpc). Scale bar 1 mm. In E comparison of the percentage (%) of immunoreaction area. (\*\*\*\*)  $p < 0.0001$ . One-way ANOVA and Tukey's test of multiple comparisons.

## DISCUSSION

In the present study, it was demonstrated that the prenatal administration of VPA can cause alterations in the epithelium-mesenchymal transition in mice, a key process for testicular morphological conformation, a situation evident in the fetal and pubertal stages. These ETMs are fundamental in the formation of tubular structures, such as the seminiferous tubules, where the mesenchyme and tubular epithelia act in harmony to promote their differentiation (Lubarsky & Krasnow, 2003). Initially, the gonadal ridges are composed primarily of somatic cellular components. However, from 12.5 dpc in mice, an initial tubular structure called the testicular cord is already beginning to be observed. These cords are initially formed as a series of adjacent transverse circular loops through the gonad and are separated from each other by interstitial cells, housing sustentacular cells inside and are delimited by peritubular cells in the process of differentiation (Skinner *et al.*, 1985).

From the results of the present study, we hypothesize that VPA can alter these ETMs between the somatic cell components that will shape the gonad, demonstrating alterations in the expression of the morphogens DHH, IGF-1 and FGF-2. Previously, it has been seen that VPA is capable of causing seminiferous tubule degeneration and loss or exfoliation of spermatids in rats (Nishimura *et al.*), as well

as decreased testicular weight and generalized testicular atrophy with spermatogenic arrest in treated animals, having greater effects proportionally to the increased VPA dose (Sveberg Røste *et al.*). In a study on Wistar rats, testicular development was evaluated in a group treated with VPA. It was determined that in the adult stage the relative weights of the testes were significantly lower in the VPA group compared to the control group. The numbers of spermatogonia, pachytene spermatocytes, and round spermatocytes decreased at all stages. In addition, it was shown that apoptosis would be the main mechanism through which VPA causes these effects, with significantly high apoptotic cell counts and p53 immunoreaction and TGF- $\beta$ 1 expression was lower in the VPA group in comparison to control (Cansu *et al.*, 2011). This demonstrated that VPA treatment from prepuberty to adulthood negatively affects spermatogenesis, not only by reducing testicular weight but also by increasing apoptotic death. These findings are related to alterations in oxidative stress generated by VPA, where it has been seen that it decreases antioxidant enzymes such as glutathione peroxidase in testicular tissue (Khan *et al.*) and generally decreases VE levels (Al Deeb *et al.*).

It is because of the previous point that in the present study we postulate VE as an eventual positive modulator to

the damage caused by VPA, demonstrating that it was capable of modulating the immunoreactivity of the morphogens studied. This is consistent with previous studies, where it has been shown that the general effects of VPA could be reversed with the previous administration of antioxidants such as VE (Hsieh *et al.*, 2014; Zhang *et al.*, 2010), being a powerful factor to prevent the oxidation of lipids in the cell membrane. In addition, EV is capable of reducing the deleterious effects of VPA in other tissues, such as in the sciatic nerve and in the development of the nervous system with a prophylactic administration during pregnancy (Aluclu *et al.*, 2009; Conei *et al.* 2016). Specifically, at the testicular level, Ourique *et al.* conducted a study in Wistar rats to evaluate the protective effect of vitamin E on functional abnormalities related to VPA-induced oxidative stress in the male reproductive system, where VE restored the antioxidant potential and prevented oxidative damage in the testes and epididymis, restoring sperm motility and testicular histological conformation, suggesting that EV may be a useful compound to minimize reproductive deterioration in patients requiring treatment with VPA (Ourique *et al.*, 2016).

In the study, the DHH morphogen showed an immunolocation from 12.5 dpc, but with significant differences at 17.5 dpc and 6 weeks postnatal only in its intensity, not in its gonadal distribution, where the percentage of immunoreactive zones was only lower in pubertal VPA groups. DHH is a morphogen secreted by sustentacular cells, which is essential in the differentiation of interstitial cells, together with platelet-derived growth factor (PDGFA) and the Homeobox Arx gene (Pierucci-Alves *et al.*; Griswold & Behringer, 2009). In turn, fetal interstitial cells have Patched1 (PTCH1) receptors for DHH and PDGFRA for PDGFA, and they respond by producing activin A, which acts as a paracrine regulator of the proliferation of sustentacular cells and the expansion of the testicular cord, and the development of adult interstitial cells (Archambeault & Yao, 2010). Due to the above, it is that DHH is observed from the early stages of gonadal development. It has also been seen that embryos that do not express DHH in the sustentacular cells present a reduced population of fetal interstitial cells, with the consequent insufficient production of androgens, causing genital atrophy and development of ambiguous external genitalia (Bitgood *et al.*; Pierucci-Alves *et al.*). Given this last antecedent, the fact that the lower expression of DHH was observed in the pubertal stage is contextualized, where the interstitial cells must activate their endocrine factors for the initiation of reproductive processes.

Another growth factor produced by sustentacular cells is IGF-1. This factor is capable of increasing the availability of cholesterol for steroidogenesis and the activity of steroidogenic enzymes (Griffeth *et al.*). A higher expression

of STAR associated with progesterone production has also been seen in response to the stimulation of interstitial cells of mLTC-1 with paracrine factors to the supporting cells such as IGF-1, and TGFA (Hu *et al.*, 2010). The steroidogenesis process occurs in fetal stages from 16.5 dpc in mice (Heinrich & DeFalco, 2020), which is why it is explained that the expression of this morphogen is observed from 17.5 dpc in the present study, with a lower expression and lower distribution of its marking. This is in addition to the fact that VPA causes endocrine disorders, with decreased serum concentrations of androgens and gonadotropins (Rättyä *et al.*, 2001; Hamed, 2016). Finally, immunolocation is consistent with previous studies where its expression was observed in interstitial cells (Green *et al.*, 2018).

A key modulator of the interaction in sustentacular and peritubular cells is FGF-2. This morphogen would be involved in the interactions between the fetal sustentacular cells and the adjacent mesonephros from which the peritubular cells come (Buehr *et al.*, 1993). In the present study, the marking only occurred at 17.5 dpc, being lower in the groups treated with VPA, expressing itself in sustentacular and peritubular cells. This agrees with a previous study where FGF-2 was expressed in rats from the perinatal fetal stages to 3 days postnatal in both cell types, postulating as an important factor for the maintenance of the tubular structure inside the gonad, in the conformation of the seminiferous tubules (Van Dissel-Emiliani *et al.*, 1996).

The main limitations of the study are the three-dimensional reconstruction of the samples, which, when passing through different reagents during the immunohistochemical assay, caused some samples to expand, causing irregular surfaces that had to be corrected when mounting the respective images during the image processing. That is why the total testicular volumes were not compared, but this variable was used to show the immunolocation of each morphogen throughout the testicular tissue and the percentage of immunoreaction area concerning the total 3D reconstruction of each sample.

In conclusion, VPA is capable of altering epithelial-mesenchymal interactions between somatic cell components in testicular development, decreasing the immunoreactivity of DHH, IGF-1 and FGF-2, showing greater damage in the fetal stage. These effects can be diminished with the joint administration of VE.

**ACKNOWLEDGMENTS.** This work was supported by grants from the Ministry of Science, Technology, Knowledge and Innovation of Chile. CONICYT-PFCHA/Doctorado Nacional/2017-21170693 Scholarship.

**CONEI, D.; ROJAS, M.; SANTAMARÍA, L. & RISOPATRÓN, J.** Efectos de la vitamina E en la interacción epitelio-mesenquimático en el desarrollo testicular expuesto a ácido valproico. *Int. J. Morphol.*, 39(4):947-955, 2021.

**RESUMEN:** En la diferenciación testicular, es necesario que las células somáticas adopten un destino específico hacia células sustentaculares, peritubulares e intersticiales, siendo fundamental para la morfogénesis de los túbulos seminíferos, mediado por morfógenos como Desert Hedgehog (DHH), Factor de Crecimiento Fibroblástico 2 (FGF-2) y Factor de Crecimiento similar a Insulina (IGF-1). Su alteración se podría relacionar a fallas en los mecanismos de desarrollo, como los que ocasiona el ácido valproico (VPA), los cuales pueden ser revertidos con la vitamina E (VE). El objetivo de estudio fue evaluar la transición epitelio-mesenquimática (EMT) en el desarrollo testicular de ratones expuestos a VPA y VE. Se conformaron 12 grupos de ratones hembra gestantes que se separaron por días post-coital (dpc) a los 12.5 dpc, 17.5 dpc y 6 semanas post-natal, cada uno subdividido en 4 grupos de 5 gestantes cada uno. Cada subgrupo recibió diferentes tratamientos desde el inicio hasta el término de la gestación vía oral: 600 mg/kg de VPA, 600 mg/kg de VPA y 200 UI de VE, 200 UI de VE y el grupo control 0,3 mL de solución fisiológica 0,9%. Se realizó técnica inmunohistoquímica para la detección de DHH, IGF-1 y FGF-2. Se observó la inmunolocalización de DHH en todos los estadios, con diferencias significativas más evidentes en la densidad óptica integrada (IOD) y porcentaje de área de inmunoreacción a las 6 semanas post-natal, siendo menor en el grupo VPA. En IGF-1, se observó en la etapa fetal y puberal menor intensidad y distribución de la marcación en los grupos VPA, situación similar con la inmunomarcación de FGF-2, pero sólo evidenciándose a los 17.5 dpc, con diferencias significativas. Estos resultados demuestran que el VPA puede alterar la EMT entre las células somáticas en el desarrollo testicular, siendo la VE un agente capaz de atenuar este proceso.

**PALABRAS CLAVE:** Transición epitelio-mesenquimática; Desert hedgehog; Factor de crecimiento fibroblástico 2; Ácido Valproico.

## REFERENCES

- Aitken, R. J. & Baker, M. A. Oxidative stress, sperm survival and fertility control. *Mol. Cell. Endocrinol.*, 250:66-69, 2006.
- Al Deeb, S.; Al Moutaery, K.; Arshaduddin, M. & Tariq, M. Vitamin E decreases valproic acid induced neural tube defects in mice. *Neurosci. Lett.*, 292(3):179-82, 2000.
- Aluclu, M.; Tuncer, M.; Guzel, A.; Aluclu M, Akkus M. The Effects of Valproic Acid on Sciatic Nerve of Fetal Rats and Protective Effects of Folic Acid and Vitamin E. *Int. J. Morphol.*, 27(2):285-94, 2009.
- American Veterinary Medical Association. *Guidelines for the Euthanasia of Animals*. 2013 Edition.
- Archambeault, D. R. & Yao, H. H. Activin A, a product of fetal Leydig cells, is a unique paracrine regulator of Sertoli cell proliferation and fetal testis cord expansion. *Proc. Natl. Acad. Sci. U. S. A.*, 107(23):10526-31, 2010.
- Bitgood, M. J.; Shen, L. & McMahon, A. P. Sertoli cell signaling by Desert hedgehog regulates the male germline. *Curr. Biol.*, 6(3):298-304, 1996.
- Buehr, M.; Gu, S. & McLaren, A. Mesonephric contribution to testis differentiation in the fetal mouse. *Development*, 117:273-81, 1993.
- Cansu, A.; Ekinici, O.; Serdaroglu, A.; Grgen, S. G.; Ekinici, O.; Erdogan, D.; Coskun, Z. K. & Tunc, L. Effects of chronic treatment with valproate and oxcarbazepine on testicular development in rats. *Seizure*, 20(3):203-7, 2011.
- Conei, D.; Soler, B.; Saint-Pierre, G.; Ortz, J. & Rojas, M. Efectos del tratamiento con vitamina E en el tubo neural y mdula espinal en embriones y fetos de ratones *Mus musculus* expuestos al uso de ácido valproico. *Int. J. Morphol.*, 34(2):732-41, 2016.
- Dennery, P. A. Role of redox in fetal development and neonatal diseases. *Antioxid. Redox Signaling*, 6:147-53; 2004.
- El Ramy, R.; Verot, A.; Mazaud, S.; Odet, F.; Magre, S. & Le Magueresse-Battistoni, B. Fibroblast growth factor (FGF) 2 and FGF9 mediate mesenchymal-epithelial interactions of peritubular and Sertoli cells in the rat testis. *J. Endocrinol.*, 187(1):135-47, 2005.
- Gavazza, M. B. & Catal, A. The effect of alpha-tocopherol on lipid peroxidation of microsomes and mitochondria from rat testis. *Prostaglandins Leukot Essent Fatty Acids*. 74(4):247-54, 2006.
- Green, C. D.; Ma, Q.; Manske, G. L.; Shami, A. N.; Zheng, X.; Marini, S.; Moritz, L.; Sultan, C.; Gurczynski, S. J.; Moore, B. B.; Tallquist, M. D.; Li, J. Z. & Hammoud, S. S. A Comprehensive Roadmap of Murine Spermatogenesis Defined by Single-Cell RNA-Seq. *Dev. Cell*. 46(5):651-67.e10, 2018.
- Griffeth, R. J.; Bianda, V. & Nef, S. The emerging role of insulin-like growth factors in testis development and function. *Basic Clin. Androl.*, 24:12, 2014.
- Griswold, S. L. & Behringer, R. R. Fetal Leydig cell origin and development. *Sex. Dev.*, 3(1):1-15, 2009.
- Hamed, S. A. The effect of epilepsy and antiepileptic drugs on sexual, reproductive and gonadal health of adults with epilepsy. *Expert. Rev. Clin. Pharmacol.*, 9(6):807-19, 2016.
- Hamed, S. A.; Moussa, E. M.; Tohamy, A. M.; Mohamed, K. O.; Mohamad, M. E.; Sherif, T. M. & Abdellah, M. M. Seminal fluid analysis and testicular volume in adults with epilepsy receiving valproate. *J. Clin. Neurosci.*, 22(3):508-12, 2015.
- Heinrich, A. & DeFalco, T. Essential roles of interstitial cells in testicular development and function. *Andrology*, 8(4):903-14, 2020.
- Hsieh, C. L.; Chen, K. C.; Lin, P. X.; Peng, C. C. & Peng, R. Y. Resveratrol and vitamin E rescue valproic acid-induced teratogenicity: the mechanism of action. *Clin. Exp. Pharmacol. Physiol.*, 41(3):210-9, 2014.
- Hu, G. X.; Lin, H.; Chen, G. R.; Chen, B. B.; Lian, Q. Q.; Hardy, D. O.; Zirkkin, B. R. & Ge, R. S. Deletion of the Igf1 gene: suppressive effects on adult Leydig cell development. *J. Androl.*, 31(4):379-87, 2010.
- Isojrvi, J. I.; Lfgren, E.; Juntunen, K. S.; Pakarinen, A. J.; Pivnsalo, M.; Rautakorpi, I. & Tuomivaara, L. Effect of epilepsy and antiepileptic drugs on male reproductive health. *Neurology*, 62(2):247-53, 2004.
- Jiang, X.; Skibba, M.; Zhang, C.; Tan, Y.; Xin, Y. & Qu, Y. The roles of fibroblast growth factors in the testicular development and tumor. *J. Diabetes. Res.*, 2013:489095, 2013.
- Khan, S.; Ahmad, T.; Parekh, C. V.; Trivedi, P. P.; Kushwaha, S. & Jena, G. Investigation on sodium valproate induced germ cell damage, oxidative stress and genotoxicity in male Swiss mice. *Reprod. Toxicol.*, 32(4):385-94, 2011.
- Lubarsky, B. & Krasnow, M. A. Tube morphogenesis: making and shaping biological tubes. *Cell.*, 112(1):19-28, 2003.
- Lucas-Herald, A. K. & Bashamboo, A. Gonadal development. *Endocr. Dev.*, 27:1-16, 2014.
- Nakata, H.; Nakano, T.; Iseki, S. & Mizokami, A. Three-dimensional analysis of busulfan-induced spermatogenesis disorder in mice. *Front. Cell. Dev. Biol.*, 8:609278, 2020.
- Nakata, H.; Sonomura, T. & Iseki, S. Three-dimensional analysis of seminiferous tubules and spermatogenic waves in mice. *Reproduction*, 154(5):569-79, 2017.
- Nishimura, T.; Sakai, M. & Yonezawa, H. Effects of valproic acid on fertility and reproductive organs in male rats. *J. Toxicol. Sci.*, 25(2):85-93, 2000.



- O'Shaughnessy, P. J. & Fowler, P. A. Development of the human fetal testis. *Ann. Endocrinol. (Paris)*, 75(2):48-53, 2014.
- Ourique, G. M.; Saccol, E. M.; Pês, T. S.; Glanzner, W. G.; Schiefelbein, S. H.; Woehl, V. M.; Baldisserotto, B.; Pavanato, M. A.; Gonçalves, P. B. & Barreto, K. P. Protective effect of vitamin E on sperm motility and oxidative stress in valproic acid treated rats. *Food Chem. Toxicol.*, 95:159-67, 2016.
- Pierucci-Alves, F.; Clark, A. M. & Russell, L. D. A developmental study of the Desert hedgehog-null mouse testis. *Biol. Reprod.*, 65(5):1392-402, 2001.
- Rättyä, J.; Turkka, J.; Pakarinen, A. J.; Knip, M.; Kotila, M. A.; Lukkarinen, O.; Myllylä, V. V. & Isojärvi, J. I. Reproductive effects of valproate, carbamazepine, and oxcarbazepine in men with epilepsy. *Neurology*, 56(1):31-6, 2001.
- Reeves, P. G.; Nielsen, F. H. & Fahey, G. C., Jr. AIN-93 purified diets for laboratory rodents: final report of the American Institute of Nutrition ad hoc writing committee on the reformulation of the AIN-76A rodent diet. *J. Nutr.*, 123(11):1939-51, 1993.
- Senthil kumar, J.; Banudevi, S.; Sharmila, M.; Murugesan, P.; Srinivasan, N.; Balasubramanian, K.; Aruldas, M. M. & Arunakaran, J. Effects of Vitamin C and E on PCB (Aroclor 1254) induced oxidative stress, androgen binding protein and lactate in rat Sertoli cells. *Reprod. Toxicol.*, 19(2):201-8, 2004.
- Skinner, M. K.; Tung, P. S. & Fritz, I. B. Cooperativity between Sertoli cells and testicular peritubular cells in the production and deposition of extracellular matrix components. *J. Cell. Biol.*, 100(6):1941-7, 1985.
- Sveberg Røste, L.; Taubøll, E.; Berner, A.; Berg, K.A.; Aleksandersen, M. & Gjerstad, L. Morphological changes in the testis after long-term valproate treatment in male Wistar rats. *Seizure*, 10(8):559-65, 2001.
- Van Dissel-Emiliani, F. M.; De Boer-Brouwer, M. & De Rooij, D. G. Effect of fibroblast growth factor-2 on Sertoli cells and gonocytes in coculture during the perinatal period. *Endocrinology*, 137(2):647-54, 1996.
- Wang, G. M.; O'Shaughnessy, P. J.; Chubb, C.; Robaire, B. & Hardy, M. P. Effects of insulin-like growth factor I on steroidogenic enzyme expression levels in mouse leydig cells. *Endocrinology*, 144(11):5058-64, 2003.
- Zhang, B.; Wang, X. & Nazarali, A. J. Ascorbic acid reverses valproic acid-induced inhibition of *hoxa2* and maintains glutathione homeostasis in mouse embryos in culture. *Cell. Mol. Neurobiol.*, 30(1):137-48, 2010.

Corresponding author:

Jennie Risopatrón  
Center of Biotechnology in Reproduction (CEBIOR-BIOREN),  
Department of Basic Sciences  
Faculty of Medicine  
Universidad de La Frontera  
Av. Francisco Salazar 01145  
Temuco  
CHILE

E-mail: [jennie.risopatron@ufrontera.cl](mailto:jennie.risopatron@ufrontera.cl)

Received: 08-06-2021

Accepted: 20-06-2021