

Cranial Bone Regeneration with Collagen Type I and Polyvinylpyrrolidone (Fibroquel®) Combined with Hyaluronic Acid in Wistar Rats: Morphological Study

Regeneración Ósea Craneal con Colágeno Tipo I y Polivinilpirrolidona (Fibroquel®) Combinado con Ácido Hialurónico en Ratas Wistar: Estudio Morfológico

Adolfo Soto-Domínguez¹; Gilberto Zatarain-Hernández²; Rubén García-Garza³; Lydia Enith Nava Rivera⁴; María de los Ángeles Pietschmann-Santamaría²; Enrique Díaz-Palomares²; Edson Josue Pacheco-Herrera²; Rodrigo Lozoya-Martínez⁴; María de la Paz Holguin-Santana⁵; Nadia Denys Betancourt-Martínez⁴; Jair Millán Orozco⁶ & Javier Morán-Martínez⁴

SOTO-DOMÍNGUEZ, A.; ZATARAÍN-HERNÁNDEZ, G.; GARCÍA-GARZA, R.; NAVA-RIVERA, L. E.; PIETSCHMANN-SANTAMARÍA, M. A.; DÍAZ-PALOMARES, E.; PACHECO-HERRERA E. J.; LOZOYA-MARTÍNEZ, R.; HOLGUIN-SANTANA, M. P.; BETANCOURT-MARTÍNEZ, N. D.; MILLÁN-OROZCO, J. & MORÁN-MARTÍNEZ, J. Cranial bone regeneration with collagen type i and polyvinylpyrrolidone (Fibroquel®) combined with hyaluronic acid in wistar rats: morphological study. *Int. J. Morphol.*, 39(3):816-822, 2021.

SUMMARY: The purpose of this study was to evaluate by morphological methods, if a mixture of Fibroquel® and hyaluronic acid implanted in an animal model of cranial bone injury could promote bone regeneration. 12 Wistar rats were divided in three groups, control group, bone injury without treatment and bone injury with treatment. After experimental period, bone samples were taken and stained with H & E, Masson trichrome, PAS-D, immunohistochemistry with anti-PCNA monoclonal antibody and applied a semiquantitative morphometric method. Treatment group showed extensive areas of collagen fibers in contact with normal bone tissue, areas of normal histology, PAS positive material and less cellular proliferation. We demonstrated for the first time that a mixture of Fibroquel® and hyaluronic acid implanted in an animal model of cranial bone injury promotes bone regeneration.

KEY WORDS: Bone; Cranial; Regeneration; Collagen; Wistar Rat.

INTRODUCTION

Collagen is a protein that forms fibers and constitutes 25-30 % of the total protein mass in mammals (Zdzieblik *et al.*, 2015) and it is mainly secreted by fibroblasts (Schwarz, 2015). Collagen fibers are flexible but provide great tensile strength. Type I collagen can be found all around the body's connective tissues, except for cartilage; it is the principal constituent of the bone (Deshmukh *et al.*, 2016) and is synthesized and secreted by fibroblasts in response to bone injury to repair it (Davis *et al.*, 2013; Darby *et al.*, 2014).

The bone lesions may be a consequence of traumatism or attrition, the latter being mainly caused by metabolic alterations. Currently, there are several compounds that are intended to promote early bone regeneration, one of them is Fibroquel®, a biopharmaceutical composed of a combination of two macromolecules: "native" type I collagen and poly vinyl pyrrolidone (clg-PVP) (Furuzawa-Carballeda *et al.*, 2009; Jacinto-Tinajero *et al.*, 2014); it is an inert polymer excreted almost entirely through the kidney (95 %) in over 24 h (Furuzawa-Carballeda *et al.*, 2010). *In vitro* studies

¹ Departamento de Histología. Facultad de Medicina, Universidad Autónoma de Nuevo León. Avenida Madero y E. Aguirre-Pequeño, Monterrey, Nuevo León, México. A. P.1563

² Clínica de Periodoncia, Facultad de Odontología, Universidad Autónoma de Coahuila, Campus Torreón. Av. Juárez y Calle 17 S/N. Colonia Centro. Torreón, Coah. México. C.P. 27000

³ Departamento de Histología. Facultad de Medicina, Universidad Autónoma de Coahuila, Campus Torreón. Avenida Morelos No. 900 Ote. Colonia Centro. Torreón, Coahuila, México. C.P. 27000.

⁴ Departamento de Biología Celular y Ultraestructura, Centro de Investigación Biomédica, Facultad de Medicina, Universidad Autónoma de Coahuila, Campus Torreón. Calle Gregorio A. García 198 Sur. Torreón, Coahuila, México. C.P. 27000

⁵ Clínica de Endodoncia, Facultad de Odontología, Universidad Autónoma de Coahuila, Campus Torreón. Avenida Juárez y Calle 17 S/N. Colonia Centro. Torreón, Coahuila, México. C.P. 27000

⁶ Autónoma Agraria Antonio Narro, Unidad Laguna. Periférico Raúl López Sánchez S/N y Carretera Santa Fe, Colonia Valle Verde. Torreón, Coahuila, México. C.P. 27054,

suggest that clg-PVP acts by promoting the collagen synthesis in fibroblasts, which results in reduced time and improved quality of the reparative process (Cervantes-Sánchez *et al.*, 2003). In vivo studies report that clg-PVP decreases pro-inflammatory factors, such as Platelet Derived Growth Factor (PDGF), Tumor Necrosis Factor- α (TNF- α) and Interleucine-1 β (IL-1 β), transforming growth factor beta (TGF- β) down regulating the inflammatory response (Kröttsch-Gómez *et al.*, 1998; Furuzawa-Carballeda *et al.*, 2003, 2005, 2010; Olmos-Zuñiga *et al.*, 2017). Studies in patients with post mastectomy without reconstruction, described good clinical and esthetic results without adverse effects after the administration of clg-PVP (Furuzawa-Carballeda *et al.*, 2012). Hyaluronic acid (HA) is an unsulfated glycosaminoglycan involved in biological processes such as morphogenesis, wound repair, inflammation and even metastasis (Turley, 1992; Entwistle *et al.*, 1996; Ladeda *et al.*, 1998; Ruiz-Eng *et al.*, 2010). A clinical double-blind assay testing the effect of a HA gel on cell proliferation in gingival biopsies of 15 periodontal patients, reported a significant decrease in the proliferation rate of Ki-67 positive cells per mm², without modifying the expression of p27; also in a significant number of patients, inflammatory Ki-67 positive cells decreased. This study concluded that HA gel significantly reduced cell proliferation in the epithelium, and inflammatory infiltrate (Zhang *et al.*, 1998). In an in vitro study, it was demonstrated that an HA based hydro gel can be used as a vehicle for cells and growth factors for regeneration of bone tissue (Mesa-Aguado *et al.*, 2001). The purpose of this study was to evaluate, by morphological methods if the application of clg-PVP and HA in a bone injury model promotes the regeneration of this tissue in Wistar rats.

MATERIAL AND METHOD

Animals and study groups: For this study, 12 pathogen free Wistar rats of 12 weeks, with an average weight of 242 g were provided by the bioterium of the Faculty of Medicine (Autonomous University of Coahuila (UAdeC), Campus Torreón, Coahuila, México) and were handled by an expert veterinarian. The animals were kept in a controlled environment with room temperature between 25 and 28°C (temperature control: 2H/JT-03, LennoxMR, Mexico), with relative humidity between 30 and 70 % (Minisplit, LennoxMR, México), with light/darkness cycles of 12 h, with food (NUTRI-CUBES, Agribands Purina®, Mexico) and water *Ad libitum*. Experiments were carried out according to the International Guidelines on the Appropriate Use of Experimental Animals and according to Mexican Norm NOM-062-ZOO-1999 on the technical specifications for production, care and use of laboratory animals (Kim *et*

al., 2007). The protocol was approved by the Bioethical Committee of the Faculty of Medicine of the Autonomous University of Coahuila, Torreón Campus, Coahuila, Mexico (Number of approval by the Secretaría de Salud and Comisión Nacional de Bioética in Mexico: CONBIOETICA07CEI00320131015). With protocol approval reference number: AUT.02-08/13.

Animals were organized in groups as follows: Group 1 (n:12): samples from the counterpart of the drilling area of groups 2 and 3 served as control without treatment. Group 2 (n:6): perforation of the left side of skull without implant of clg-PVP and HA. Group 3 (n:6): perforation of right side of the skull and covered with clg-PVP and HA, a resorbable collagen barrier was placed over the site of surgery.

Surgery and treatment in study groups: Rats of the groups 2 and 3 were operated under general anesthesia with Ketamine/Xylazine 75mg/kg+10mg/kg intramuscularly (RompunMR, Bayer, México) and ketamine hydrochloride (VetalarMR, Parke-Davis, USA). The skin of the upper middle part of the head was cut open, and the outside of the skull was ruptured; a surgical motor drill was specially adapted for saline irrigation (Dyna Surg Model 28213 Micro Motors, Inc., USA), reducing anti-angle 1:16 at 1700 rpm, milling burs and surgical instruments were used to access the skullbone. The surgery was performed under the supervision of the veterinarian with caution so as not to pierce or expose the meningeal layers. After the corresponding treatment, the skin was placed back into place and sutured closed. Antibiotics were administered to prevent infection.

Tissue samples collection: 4 weeks after the surgery, the specimens were sacrificed by cervical dislocation and skulls were placed in 10 % formalin with phosphate buffered saline (PBS) pH 7.2-7.4. Tissues samples were placed in 10 % nitric acid during a week to decalcify the bone matrix. Samples were washed with tap water and soap, then processed by conventional histological technique and embedded in paraffin blocks.

Morphological evaluation: 5-micron sections were obtained, mounted, and stained with hematoxylin and eosin (H&E), Masson's trichrome and Periodic acid-Schiff-diastase (PAS-D) stain. Immunohistochemistry (IHC) analysis was carried out using a monoclonal antibody anti-PCNA (Proliferating Cell Nuclear Antigen) (1:200, Dako Cytomation, Inc.) to identify proliferating cells (Matsumoto *et al.*, 1987; SAGARPA, 1999). As detection the Envision® system (Dako Cytomation, Inc.) was employed. Positivity was observed with 3-3'-diaminobenzidine (DAB), nuclei were contrasted with Mayer's hematoxylin and samples were analyzed by light microscopy.

Morphometric analysis: A semi-quantitative morphometric analysis was performed to quantify PCNA positive cells: 10 consecutive fields were analyzed with 40X objective, values were expressed as number of positive cells / per field. This was done by triplicate and the mean and standard deviation (SD) were also obtained. The results were analyzed using Student t-test for comparing the groups with a significance value of $p \leq 0.05$.

RESULTS

Histology analysis: The samples from the group 1 stained with H&E showed a normal histology. In group 2, areas of normal cortical bone were observed alternating with trabecular bone, these also showed a marked disorganization of the collagen fibers, as well as large spaces filled with

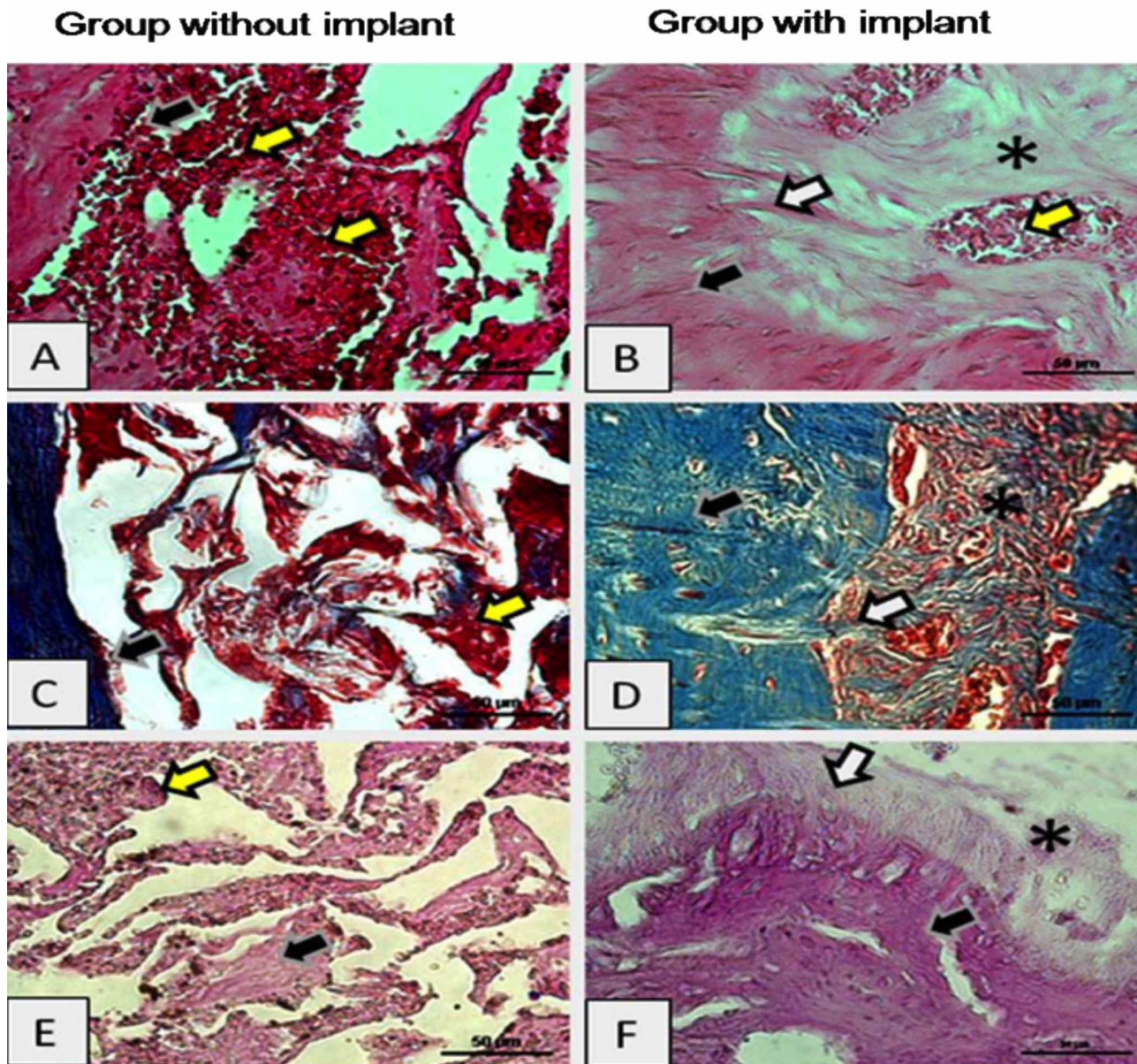


Fig. 1. A) Group 2: abundant erythrocyte areas infiltrated small bone trabeculae (yellow arrows). B) Group 3: Areas of the implant (*), with areas of hemorrhage (yellow arrow) and normal compact bone (black arrow) are observed. C) Group 2: Large areas of hemorrhage (yellow arrow) surrounded by small normal compact bone trabeculae (black arrow). D) Group 3: normal compact bone (black arrow) fibers in contact with fibers (white arrows) of the implant (*). E) Group 2: Areas of hemorrhage (yellow arrow) surrounding small bone trabeculae (black arrow). F) Group 3: Areas of the implant (*) in contact with normal compact bone, and without areas of hemorrhage. A, B: H&E, C, D: Masson trichrome. E, F: PAS + diastase. Bar 50 µm.

erythrocytes (Fig. 1A). In group 3, abundant areas of normal bone were observed with small fibrous projections towards the site of implantation (Fig. 1B); in these samples histological appearance was remarkably similar to group 1. These findings were confirmed in samples stained with Masson trichrome: a larger amount of collagen fibers in bright blue color along with a fewer red cell infiltrate compared with histological appearance of group 2 (Figs. 1C-D).

Histochemical analysis: In group 2, samples pretreated with diastase and analyzed with PAS, few areas PAS positive were

observed, compared to group 3 where extensive areas of material PAS positive was observed (Figs. 1E-F).

Immunohistochemical and morphometric analysis: In group 2 a high number of positive cells was observed (Fig. 2B), followed by group 3 (Fig. 2C). Group 1 showed the lowest number of positive cells (Fig. 2A). In the quantification of PCNA positive cells, it was observed that group 2 had the highest number of positive cells: 10.83 ± 4.368 , then group 3: 3.00 ± 1.089 . Group 1 showed the smallest amount of positive cells: 1.166 ± 0.144 . Contrasting the results of all groups a statistically significant difference was observed for a value of $p \leq 0.05$ (Fig. 2D).

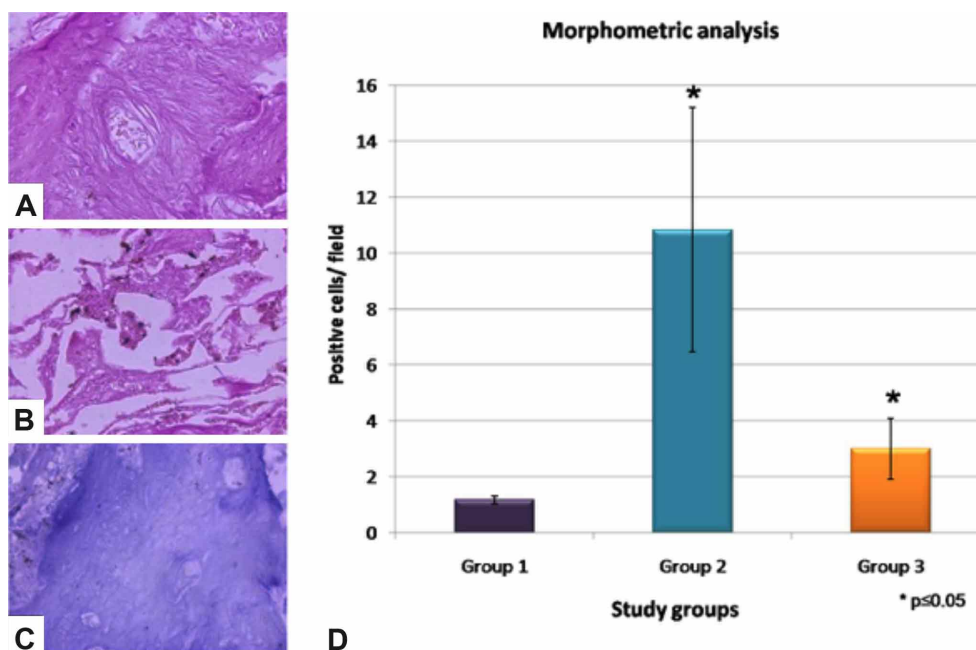


Fig. 2. A) Group 1: negative results for PCNA immunolabeling. B) Group 2: Abundant cells positives are observed. C) Group 3: negative result. Immunohistochemistry. Bar: 50 μ m. D) Graph shows the results of semiquantitative morphometric analysis for PCNA in each study groups. Statistical analysis shows a significant difference among groups (* $P \leq 0.05$).

DISCUSSION

Studies have reported that clg-PVP improves the quality and response time of regenerating process (Furuzawa-Carballeda *et al.*, 2005; Zerón *et al.*, 2007; Furuzawa-Carballeda *et al.*, 2010); they also decreased the production of pro-inflammatory factors (Kröttsch-Gómez *et al.*; Zhang *et al.*, 1999; Furuzawa-Carballeda *et al.*, 2003, 2005). In terms of bone regeneration, clg-PVP potential has been evaluated based on radiological progression in patients with retained third molars (Macías-Hernández *et al.*, 2014) and osseous defects (Furuzawa-Carballeda *et al.*, 2010), promoting a bone regeneration in less time than occurs

physiologically; a similar effect was observed after the application of this biomolecule in diaphyseal fractures in Wistar rats, which presented a rapid replacement of fibrous tissue by cartilage, followed by bone tissue, plus high osteopontin and osteonectin expression, this latter, proteins that led to bone consolidation (Almazán-Díaz *et al.*, 1996). In another study clg-PVP enhanced bone regeneration to higher levels than collagen alone, by allowing the formation of a better matrix for the invasion and migration of osteoprogenitor cells in adult male rats (Chimal-Monroy *et al.*, 1997).

Previous studies have reported that application of HA on gingival periodontal lesions improved evaluated parameters with a nonsignificant decrease of the inflammatory infiltrate (Gontiya & Galgali, 2012; Casale *et al.*, 2016, 2017). The application of HA for bone regeneration has also been described regarding the osteogenic-enhancing effects in vitro (Huang *et al.*, 2003; Zhai *et al.*, 2020) and in vivo where this compound demonstrated an accelerated bone formation process, with earlier angiogenesis and mesenchymal cell differentiation in rat femurs (Sasaki & Watanabe, 1995); this osteogenic effect could be accomplished through the bone morphogenetic protein 2 (BMP-2) enhancement demonstrated in vitro (Kawano *et al.*, 2011) and in vivo (Huang *et al.*, 2017). Recently, the efficacy of HA alone and combined with bone graft material on bone healing in defects created in the rat mandible was evaluated, histopathological analysis resulted in proliferation of bone tissue at the defect borders and a higher bone mineralization in the treated groups (Koca *et al.*, 2019). The combined effect of HA with other compounds has also been evaluated, having effects on the regeneration of cartilage (Suwannaloe *et al.*, 2012) bone healing (Chang *et al.*, 2016) and collagen mineralization in vivo (Nguyen & Lee, 2014). However, the combination of clg-PVP and HA have not been documented previously. In our study the samples in group 3 (treated with the combination of clg-PVP and HA) presented better histological appearance, compared with the group 2 (without clg-PVP and HA treatment). The presence of a larger amount of collagen fibers in treated group suggests an increased synthesis of this protein, compared with untreated group. Previous studies have reported that application of clg-PVP acts by modulating the synthesis of collagen by fibroblasts and that HA affects the process of wound repair (Turley; Entwistle *et al.*; Ladedo *et al.*; Ruiz-Eng *et al.*); these studies support our findings. In a clinical double-blind assay testing the effect of a HA gel on cell proliferation in gingival biopsies, a significant decrease in the proliferation of cells positive for Ki-67 per mm² was observed; also in a significant number of patients, inflammatory Ki-67 positive cells decreased (Zhang *et al.*, 1998; Pini Prato *et al.*, 2003). This correlates with our findings with anti-PCNA where the group without treatment of clg-PVP and HA showed more positive cells compared to the group with treatment and the control group; a statistically significant difference was observed among groups.

CONCLUSION

In conclusion, our study describes for the first time that a combination of clg-PVP and HA and applied in an animal model of cranial bone lesion, promotes repair of tissue

without chemotaxis of inflammatory cells in the site of injury. Currently, studies are being carried out in our laboratory to evaluate if the combination of clg-PVP and HA increases bone repair in other lesion sites and if it promotes the organization of osteons and the subsequent formation of Havers channels.

ACKNOWLEDGMENTS

We acknowledge the work of Biol. René Reynaga-Piña and QFB Adriana I. Gallardo-Gómez for technical assistance involved in processing and immunolabeling of the samples and Lic. Daniel García for checking revised reviewed English manuscript. Nadia Denys Betancourt-Martínez was supported by CONACyT scholarships #18046. Javier Morán Martínez was supported by Fogarty International Center Career Trac, School of Public Health, University of California At Los Angeles: GrantNumber:D43TW623. Program Name: ITREOH. We thank the Dirección de Estudios de Posgrado e Investigación of the Universidad Autónoma de Coahuila by partial support of the study.

SOTO-DOMÍNGUEZ, A.; ZATARAÍN-HERNÁNDEZ, G.; GARCÍA-GARZA, R.; NAVA-RIVERA, L. E.; PIETSCHMANN-SANTAMARÍA, M. A.; DÍAZ-PALOMARES, E.; PACHECO-HERRERA E. J.; LOZOYA-MARTÍNEZ, R.; HOLGUIN-SANTANA, M. P.; BETANCOURT-MARTÍNEZ, N. D.; MILLÁN-OROZCO, J. & MORÁN-MARTÍNEZ, J. Regeneración ósea craneal con colágeno tipo i y polivinilpirrolidona (fibroquel®) combinado con ácido hialurónico en ratas wistar: estudio morfológico. *Int. J. Morphol.*, 39(3):816-822, 2021.

RESUMEN: El propósito de este estudio fue evaluar por métodos morfológicos, si una mezcla de Fibroquel® y ácido hialurónico implantado en un modelo animal de lesión del hueso craneal podría promover la regeneración ósea. Se dividieron 12 ratas Wistar en tres grupos, grupo control, lesión ósea sin tratamiento y lesión ósea con tratamiento. Después del período experimental, se tomaron muestras de hueso y se tiñeron con H & E, tricrómico de Masson, PAS-D, inmunohistoquímica con anticuerpo monoclonal anti-PCNA y se aplicó un método morfométrico semicuantitativo. El grupo de tratamiento mostró áreas extensas de fibras de colágeno en contacto con tejido óseo normal, áreas de histología normal, material PAS positivo y menor proliferación celular. Demostramos por primera vez que una mezcla de Fibroquel® y ácido hialurónico implantado en un modelo animal de lesión del hueso craneal promueve la regeneración ósea.

PALABRAS CLAVE: Hueso; Cráneo; Regeneración; Colágeno; Rata Wistar.

REFERENCES

- Almazán-Díaz, A.; de la Cruz-García, J. C.; Lira-Romero, J. M.; Arrelín, G.; Chimal-Monroy, J.; Díaz de León, L.; Furuzawa-Carballeda, J. & Krötzsch-Gómez, F. E. Investigación experimental de la regeneración ósea en fémures de rata después de la aplicación de colágena I polimerizada: Estudio radiológico, histológico e inmunohistoquímico. *Rev. Mex. Ortop. Traumatol.*, 10(3):142-52, 1996.
- Casale, M., Moffa, A.; Vella, P.; Rinaldi, V.; Lopez, M. A.; Grimaldi, V. & Salvinelli, F. Systematic review: the efficacy of topical hyaluronic acid on oral ulcers. *J. Biol. Regul. Homeost. Agents*, 31(4 Suppl. 2):63-9, 2017.
- Casale, M.; Moffa, A.; Vella, P.; Sabatino, L.; Capuano, F.; Salvinelli, B.; Lopez, M. A.; Carinci, F. & Salvinelli, F. Hyaluronic acid: Perspectives in dentistry. A systematic review. *Int. J. Immunopathol. Pharmacol.*, 29(4):572-82, 2016.
- Cervantes-Sánchez, C. R.; Olaya, E.; Testas, M.; Garcia-López, N.; Coste, G.; Arrellin, G.; Luna, A. & Krötzsch, F. E. Collagen-PVP, a collagen synthesis modulator, decreases intraperitoneal adhesions. *J. Surg. Res.*, 110(1):207-10, 2003.
- Chang, Y. L.; Lo, Y. J.; Feng, S. W.; Huang, Y. C.; Tsai, H. Y.; Lin, C. T.; Fan, K. H. & Huang, H. M. Bone healing improvements using hyaluronic acid and hydroxyapatite/beta-tricalcium phosphate in combination: an animal study. *Biomed Res. Int.*, 2016:8301624, 2016.
- Chimal-Monroy, J.; Bravo-Ruiz, T.; Krötzsch-Gómez, F. E. & Díaz de León, L. Implantes de Fibroquel MR aceleran la formación de hueso nuevo en defectos óseos inducidos experimentalmente en cráneo de rata: Un estudio histológico. *Rev. Biomed.*, 8:81-8, 1997.
- Darby, I. A.; Laverdet, B.; Bonté, F. & Desmoulière, A. Fibroblasts and myofibroblasts in wound healing. *Clin. Cosmet. Investig. Dermatol.*, 7:301-11, 2014.
- Davis, M. E.; Gumucio, J. P.; Sugg, K. B.; Bedi, A. & Mendias, C. L. MMP inhibition as a potential method to augment the healing of skeletal muscle and tendon extracellular matrix. *J. Appl. Physiol.* (1985), 115(6):884-91, 2013.
- Deshmukh, S. N.; Dive, A. M.; Moharil, R. & Munde, P. Enigmatic insight into collagen. *J. Oral Maxillofac. Pathol.*, 20(2):276-83, 2016.
- Entwistle, J.; Hall, C. L. & Turley, E. A. HA receptors: regulators of signalling to the cytoskeleton. *J. Cell Biochem.*, 61(4):569-77, 1996.
- Furuzawa-Carballeda, C. Z.; García-Aranda, R. L. & Furuzawa-Carballeda, J. Estudio piloto sobre la eficacia del uso de la colágena-policaprolactona (Cig-PVP) en la regeneración ósea en cirugía endodóncica. *Rev. Odontol. Mex.*, 9(4):191-6, 2010.
- Furuzawa-Carballeda, J.; Krötzsch, E.; Barile-Fabris, L.; Alcalá, M. & Espinosa-Morales, R. Subcutaneous administration of collagen-polyvinylpyrrolidone down regulates IL-1beta, TNF-alpha, TGF-beta1, ELAM-1 and VCAM-1 expression in scleroderma skin lesions. *Clin. Exp. Dermatol.*, 30(1):83-6, 2005.
- Furuzawa-Carballeda, J.; Lima, G.; Llorente, L.; Nuñez-Álvarez, C.; Ruiz-Ordaz, B. H.; Echevarría-Zuno, S. & Hernández-Cuevas, V. Polymerized-type I collagen downregulates inflammation and improves clinical outcomes in patients with symptomatic knee osteoarthritis following arthroscopic lavage: a randomized, double-blind, and placebo-controlled clinical trial. *ScientificWorldJournal*, 2012:342854, 2012.
- Furuzawa-Carballeda, J.; Muñoz-Chablé, O.; Macías-Hernández, S. & Agualimoia-Janning, A. Effect of polymerized-type I collagen in knee osteoarthritis. II. In vivo study. *Eur. J. Clin. Invest.*, 39(7):598-606, 2009.
- Furuzawa-Carballeda, J.; Rojas, E.; Valverde, M.; Castillo, I.; Lino Diaz de León, L. & Krötzsch, E. Cellular and humoral responses to collagen-polyvinylpyrrolidone administered during short and long periods in humans. *Can. J. Physiol. Pharmacol.*, 81(11):1029-35, 2003.
- Gontiya, G. & Galgali, S. R. Effect of hyaluronan on periodontitis: A clinical and histological study. *J. Indian Soc. Periodontol.*, 16(2):184-92, 2012.
- Huang, H.; Feng, J.; Wismeijer, D.; Wu, G. & Hunziker, E. B. Hyaluronic acid promotes the osteogenesis of BMP-2 in an absorbable collagen sponge. *Polymers (Basel)*, 9(8):339, 2017.
- Huang, L.; Cheng, Y. Y.; Koo, P. L.; Lee, K. M.; Qin, L.; Cheng, J. C. Y. & Kumta, S. M. The effect of hyaluronan on osteoblast proliferation and differentiation in rat calvarial-derived cell cultures. *J. Biomed. Mater. Res. A*, 66(4):880-4, 2003.
- Jacinto-Tinajero, J. C.; Ascencio, D.; Marquina, B.; Barrios-Payán, J.; Gutierrez, M. C.; Lim, M. G. & Hernández Pando, R. Induction of bone formation in abdominal implants constituted by collagen sponges embedded with plant-based human transforming growth factor family proteins in ectopic dog model. *J. Exp. Orthop.*, 1(1):11, 2014.
- Kawano, M.; Ariyoshi, W.; Iwanaga, K.; Okinaga, T.; Habu, M.; Yoshioka, I.; Tominaga, K. & Nishihara, T. Mechanism involved in enhancement of osteoblast differentiation by hyaluronic acid. *Biochem. Biophys. Res. Commun.*, 405(4):575-80, 2011.
- Kim, J.; Kim, I. S.; Cho, T. H.; Lee, K. B.; Hwang, S. J.; Tae, G.; Noh, I.; Lee, S. H.; Park, Y. & Sun, K. Bone regeneration using hyaluronic acid-based hydrogel with bone morphogenic protein-2 and human mesenchymal stem cells. *Biomaterials*, 28(10):1830-7, 2017.
- Koca, C.; Komerik, N. & Ozmen, O. Comparison of efficiency of hyaluronic acid and/or bone grafts in healing of bone defects. *Niger. J. Clin. Pract.*, 22(6):754-62, 2019.
- Krötzsch-Gómez, F. E.; Furuzawa-Carballeda, J.; Reyes-Márquez, R.; Quiróz-Hernández, E. & Díaz de León, L. Cytokine expression is downregulated by collagen-polyvinylpyrrolidone in hypertrophic scars. *J. Invest. Dermatol.*, 111(5):828-34, 1998.
- Ladeda, V.; Aguirre Ghiso, J. A. & Bal de Kier Joffé, E. Function and expression of CD44 during spreading, migration, and invasion of murine carcinoma cells. *Exp. Cell Res.*, 242(2):515-27, 1998.
- Macías-Hernández, S. I.; González-Muñoz, C. G.; Ortega-Martín del Campo, J. & Morones-Alba, J. D. Efectos de la colágena-policaprolactona en la regeneración ósea posterior a la cirugía de terceros molares retenidos. Ensayo clínico controlado. *Rev. Asoc. Dent. Mex.*, 71(6):280-4, 2014.
- Matsumoto, K.; Moriuchi, T.; Koji, T. & Nakane, P. K. Molecular cloning of cDNA coding for rat proliferating cell nuclear antigen (PCNA)/cyclin. *EMBO J.*, 6(3):637-42, 1987.
- Mesa-Aguado, F. L.; Aneiros-Cachaza, J. & O'Valle-Ravassa, F. Estudio Inmunohistoquímico del Efecto-Antiproliferativo del Ácido Hialurónico sobre la Mucosa Gingival en Pacientes con Enfermedad Periodontal. En: Granada, IV Congreso Virtual Hispano Americano De Anatomía Patológica (IV-CVHAP), Póster-E-036, 2001.
- Nguyen, T. B. L. & Lee, B. T. A combination of biphasic calcium phosphate scaffold with hyaluronic acid-gelatin hydrogel as a new tool for bone regeneration. *Tissue Eng. Part A.*, 20(13-14):1993-2004, 2014.
- Olmos-Zuñiga, J. R.; Silva-Martínez, M.; Jasso-Victoria, R.; Baltazares-Lipp, M.; Hernández-Jiménez, C.; Buendía-Roldan, I.; Jasso-Arenas, J.; Martínez-Salas, A.; Calyeca-Gómez, J.; Guzmán-Cedillo, A. E.; et al. Effects of pirfenidone and collagen-polyvinylpyrrolidone on macroscopic and microscopic changes, TGF- β 1 expression, and collagen deposition in an experimental model of tracheal wound healing. *Biomed Res. Int.*, 2017:6471071, 2017.
- Pini Prato, G. P.; Rotundo, R.; Magnani, C.; Soranzo, C.; Muzzi, L. & Cairo, F. An autologous cell hyaluronic acid graft technique for gingival augmentation: a case series. *J. Periodontol.*, 74(2):262-7, 2003.

- Ruiz-Eng, R.; Montiel-Jarquín, Á.; De la Rosa-Pérez, R.; López-Colombo, A.; Gómez-Conde, E. & Zamudio-Huerta, L. Colágeno-polivinilpirrolidona, nueva opción para tratar secuelas de la mastectomía radical en mujeres con cáncer mamario. Informe preliminar. *Cir. Cir.*, 78(4):310-4, 2010.
- SAGARPA Norma Oficial Mexicana NOM-062-ZOO-1999: Especificaciones Técnicas para la Producción, Cuidado y Uso de los Animales de Laboratorio, 1999.
- Sasaki, T. & Watanabe, C. Stimulation of osteoinduction in bone wound healing by high-molecular hyaluronic acid. *Bone*, 16(1):9-15, 1995.
- Schwarz, R. I. Collagen I and the fibroblast: high protein expression requires a new paradigm of post-transcriptional, feedback regulation. *Biochem. Biophys. Rep.*, 3:38-44, 2015.
- Suwannaloet, W.; Laupattarakasem, W.; Sukon, P.; Ong-Chai, S. & Laupattarakasem, P. Combined effect of subchondral drilling and hyaluronic acid with/without diacerein in full-thickness articular cartilage lesion in rabbits. *ScientificWorldJournal*, 2012:310745, 2012.
- Turley, E. A. Hyaluronan and cell locomotion. *Cancer Metastasis Rev.*, 11(1): 21-30, 1992.
- Zdzieblik, D.; Oesser, S.; Baumstark, M. W.; Gollhofer, A. & König, D. Collagen peptide supplementation in combination with resistance training improves body composition and increases muscle strength in elderly sarcopenic men: a randomised controlled trial. *Br. J. Nutr.*, 114(1):1237-45, 2015.
- Zerón, H. M.; Gómez, F. E. K. & Muñoz, R. E. H. Pressure ulcers: a pilot study for treatment with collagen polyvinylpyrrolidone. *Int. J. Dermatol.*, 46(3):314-7, 2007.
- Zhai, P.; Peng, X.; Li, B.; Liu, Y.; Sun, H. & Li, X. The application of hyaluronic acid in bone regeneration. *Int. J. Biol. Macromol.*, 151:1224-39, 2020.
- Zhang, G.; Gibbs, E.; Kelman, Z.; O'Donnell, M. & Hurwitz, J. Studies on the interactions between human replication factor C and human proliferating cell nuclear antigen. *Proc. Natl. Acad. Sci. U. S. A.*, 96(5):1869-74, 1999.
- Zhang, S.; Chang, M. C.; Zylka, D.; Turley, S.; Harrison, R. & Turley, E. A. The hyaluronan receptor RHAMM regulates extracellular-regulated kinase. *J. Biol. Chem.*, 273(18):11342-8, 1998.

Corresponding author:

Dr. Javier Morán Martínez
Departamento de Biología Celular y Ultraestructura
Centro de Investigación Biomédica
Universidad Autónoma de Coahuila Campus Torreón
Av. Gregorio A. García 198 Sur
Torreón
Coah. C.P. 27000
MEXICO

E-mail: javmoran@yahoo.com

Received: 12-01-2021

Accepted: 24-03-2021