

# Clinical Study on the Posterior Occlusal Plane and Morphology of Temporomandibular Joint

Estudio Clínico sobre el Plano Oclusal Posterior y la Morfología de la Articulación Temporomandibular

Hu Rong; Hui-qing Long<sup>1</sup>; Ling-xia Liu<sup>1</sup>; Li Xin<sup>2</sup>; Hee-Moon Kyung<sup>3</sup>; Li Bing<sup>1</sup> & Xiu-Ping Wu<sup>1</sup>

---

**RONG, H.; LONG, H. Q.; LIU, L. X.; XIN, L.; KYUNG, H. M.; BING, L. & WU, X. P.** Clinical study on the posterior occlusal plane and morphology of temporomandibular joint. *Int. J. Morphol.*, 37(4):1347-1352, 2019.

**SUMMARY:** The objective of the study was to investigate the morphological features of the temporomandibular joint in adult patients with posterior occlusal plane and different inclinations. Fifty five skeletal I occlusion patients with average were included, shooting CBCT in the intercuspal position, divided into 3 groups according to OPP-FH angle, and measurement of the temporomandibular joint morphology was calculated with cone beam computed tomography (CBCT) special software Invivo 5.0, Statistical analysis of three groups of data using SPSS23.0. The condyle usually locates in the middle of the fossa, the maximum axial area of the condyle (A) was statistically significant between the group 1 and the group 3. The internal and external diameter (MD) of the condyle was statistically significant between group 1 and group 3, and group 2 and group 3. The bilateral TMJ morphological features of the three groups were basically symmetrical. The position of the condyle in the fossa is mostly centered, and some of the posterior, the maximum axial area and the internal and external diameter of the condyle are different in three groups.

**KEY WORDS:** Morphological characteristics; Temporomandibular joint; Occlusal plane; Condyle; Cone Beam Computed Tomography.

---

## INTRODUCCIÓN

The occlusal plane plays an important role in the occlusion function, stable therapeutic effect, and facial appearance, and is related to the formation mechanism of malocclusion (Marchiori *et al.*, 2013; Shetty *et al.*, 2015), it is often adjusted in orthodontics to achieve a stable and perfect occlusion relationship. In particular, the inclination of the posterior occlusal plane (OPP) is important for the normal physiological function of the temporomandibular joint and the growth of the mandible (Tanaka & Sato, 2008). Some authors have proposed that the cant of the maxillary posterior occlusal plane might affect the and the functional positioning of the mandible, consequently, the condyle functionally adapts to the new adopted position of the mandible (Kim *et al.*, 2006). The relationship between the posterior occlusal plane and the position of the mandible seemed to be closer when comparing the anterior occlusal plane (Tanaka & Sato). The morphology and structure of the TMJ are related to the stress it receives. The occlusal

factors may change the stress acting on the TMJ, leading to TMJ adaptive remodeling (Ueki *et al.*, 2008). Normal structure of TMJ can not only maintain the balance of the stomatognathic system, but also determines the long-term stability after orthodontic treatment (Cordeiro *et al.*, 2018). Thus, it is extremely important to obtain a better understanding of the relationship between the OPP and the TMJ morphological function.

Cone Beam Computed Tomography (CBCT) can observe and measure the temporomandibular joint structure from three dimensions, so as to achieve a more comprehensive and realistic analysis of TMJ morphology and structure. In this paper, the three-dimensional reconstruction images of CBCT are used to investigate the relationship between the OPP and the TMJ morphological characteristics under the premise that the exclusion of osseous deformity caused by differences in the OPP inclination.

<sup>1</sup> Department of Orthodontics, School of Dentistry, Shanxi Medical University, Taiyuan, China.

<sup>2</sup> Department of Stomatology, Dalian Children's Hospital Affiliated to Dalian Medical University, Dalian, China.

<sup>3</sup> Department of Orthodontics, School of Dentistry, Kyungpook National University, Daegu, Korea.

Funding: Major international science and technology cooperation projects of Shanxi Province No. 201803D421062, No. 2015081030. Major science and technology projects of Shanxi Province No. 201803D31065

## MATERIAL AND METHOD

The total sample comprised 55 subjects (25 male and 30 female) who sought orthodontic treatment at the Department of Orthodontics, Shanxi Medical University School and Hospital of Stomatology, Taiyuan, China, between 2016 and 2018. Inclusion criteria were as follows: 1) Han nationality, 18-35 years,  $0.7^{\circ} \leq ANB \leq 4.7^{\circ}$ ;  $22^{\circ} \leq FH-MP \leq 32^{\circ}$ ; 2) with all permanent teeth erupted, no deformed or missing teeth no obvious restorations; 3) coordinated and symmetrical face, no clinical history of TMJ disorder; 4) orthodontic untreated, no clinical history of facial trauma; 5) no systemic disease or congenital disease. The sample was divided into 3 groups according to the size of OPP-FH. 1) Group 1:  $12^{\circ} \leq OPP-FH < 15^{\circ}$ ; 2) Group 2:  $15^{\circ} \leq OPP-FH < 18^{\circ}$ ; 3) Group 3:  $18^{\circ} \leq OPP-FH < 21^{\circ}$ , the number of each group is 15 people, 24 people, 16 people.

**Instrument and software.** CBCT scanner (KaVo Dental GmbH, Germany); Invivo software (version 5.0, Anatomage, San Jose, Calif); SPSS23.0 software.

**Acquiring and reconstructing of images.** All the images were acquired before orthodontic treatment by using a CBCT scanner, with the patients in the same position (maximum dental intercuspation and heads were positioned with the Frankfurt plane parallel to the floor). The data obtained were exported as digital imaging and communications in medicine (DICOM) format files, which were reconstructed into

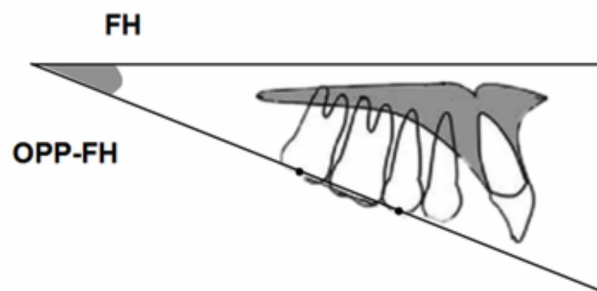


Fig. 1. Illustration of posterior occlusal plane.

3D craniomaxillofacial models by using the Invivo software, thereafter and then entering the TMJ view.

**Selecting the measurement view.** We used the same protocol as Tabrizi *et al.* (2016) for making sagittal, axial and coronal slices through TMJ. The axial section of the condylar process that had the widest mediolateral diameter on the left and right side condyles was chosen as the reference view. A line parallel to the long axis of the condylar process was drawn and sagittal images were reconstructed. In total, 12 angular and linear measurements were performed on the reconstructed structures to measure and analysis the models, were divided into in three parts.

1. Posterior occlusal plane inclination: The angle between the OPP (a line drawn from the cusp tip of the maxillary second premolar to the midpoint of the maxillary second molar at the occlusal surface) and the FH plane (Fig. 1).

Table I. Variables for the evaluation of condyle and condylar fossa.

Variables	Definition
Condylar anteroposterior diameter (mm)	The distance between the anterior and posterior points of the condyle
Condylar mediolateral diameter (mm)	The distance between the innermost and outermost points of the condyle
Condylar angle ( $^{\circ}$ )	The angle between the extension of the long axis of the condyle and the median sagittal line
The length between the condyle and the median sagittal line (mm)	The vertical distance from the center of the condyle to the median sagittal line
Maximum axial area of the condyle ( $mm^2$ )	The maximum area of the condyle on the axis
Anterior joint space (mm)	The shortest distance between the anterior point of the condyle and the posterior wall of the articular tubercle
Superior joint space (mm)	The shortest distance between the uppermost point of the condyle and the deepest point of the articular fossa
Posterior joint space (mm)	The shortest distance between the last point of the condyle and the posterior wall of the articular fossa
Width of the articular fossa (mm)	The distance from the lowest point of the articular tubercle to the most concave point of the posterior wall of the articular fossa
Depth of the articular fossa (mm)	The shortest distance from the highest point of the fossa to the connection between the external auditory canal and the lowest point of the articular tubercle
Inclination of the posterior wall of the articular tuberosity ( $^{\circ}$ )	The angle between the tangent to the posterior wall of the articular tubercle and the Frankfurt plane

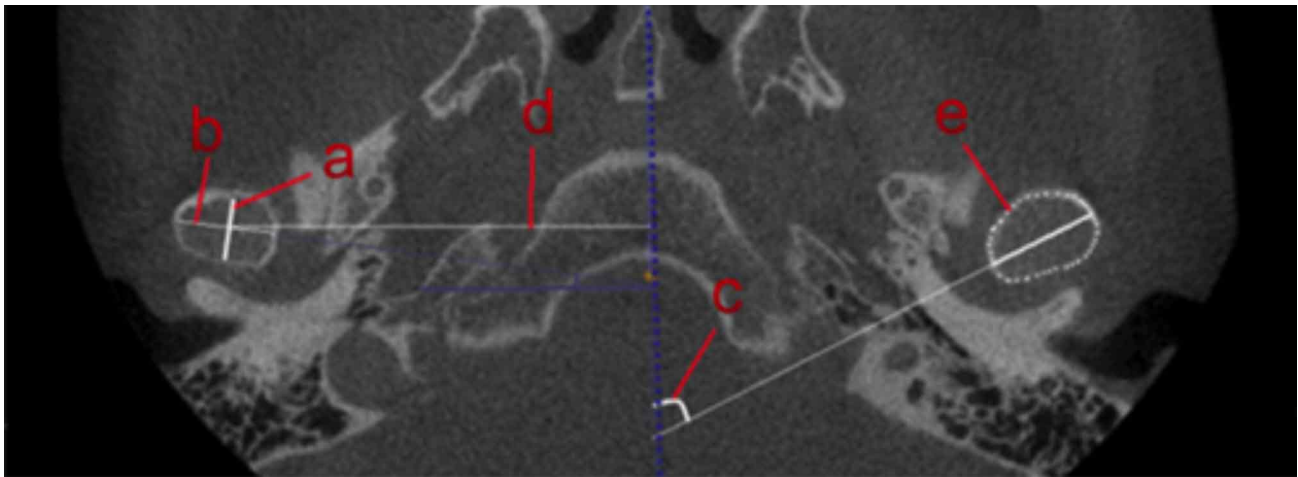


Fig. 2. Axial section measurements of temporal mandibular joint.

2. The temporomandibular joint in axial section measurement project including: condylar anteroposterior diameter (CAD), condylar mediolateral diameter (CMD), condylar angle (a), the length between the condyle and the median sagittal line (LCL), maximum axial area of the condyle (MA) (Fig. 2; Table I).

The measurements of temporomandibular joint in sagittal section, were performed by measuring anterior joint space (AJS), superior joint space (SJS), posterior joint space (PJS), width and depth of the articular fossa (WG and HG), inclination of the posterior wall of the articular tubercle (IPA) (Fig. 3; Table I). For the location analysis of the condyle in the socket, we use the same method as the Pullinger (Pullinger & Hollender, 1987): calculate the linear ratio of the anterior and posterior gaps of the bilateral joint:  $LR = \frac{PA}{P+A} * 100$  (P- posterior space, A - anterior space),  $LR < -12\%$  condyle posterior position,  $-12\% < LR < 12\%$  condylar neutral position,  $LR > 12\%$  condyle anterior position.

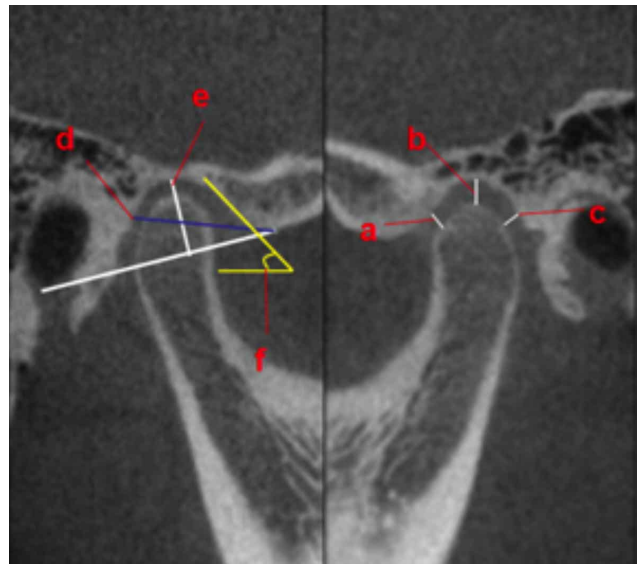


Fig.3. Sagittal section measurements of temporal mandibular joint

**Statistical analysis.** Statistical analysis of measurement results was performed on the SPSS 23.0, paired sample t test was conducted within the group, One-way ANOVA was used for comparison among multiple groups, and the SNK test was conducted for the measurement parameters with statistical significance. All statistical tests were set at 95 % confidence level ( $p < 0.05$ ).

## RESULTS

The results of paired t-test within the group were shown in Table II. The difference was not statistically significant ( $P > 0.05$ ), indicating that the shape and position

of the TMJ on the left and right sides were basically symmetrical. Therefore, the left and right sides were combined for statistical analysis. As for the position of the condyle in the condylar fossa, group 1 and group 3 were mainly in the neutral position, accounting for 88 % and 75 % respectively; in group 2, patients with condylar neutral position accounted for 50 % and those with condylar posterior position accounted for 33 % (Table III). One-way ANOVA for the variables showing statistically significant differences in MA (mm<sup>2</sup>) and CMD (mm) are listed in Table IV. The results of SNK test revealed that MA (mm<sup>2</sup>) had a statistically significant difference in group 1 and group 3 while CMD (mm) was statistically significant in group 1, group 3 and group 2, group 3 (Table V).

Table II. Comparison of TMJ on the left and right sides of three groups. n=55 ±SD

	Group 1			Group 2			Group 3		
	right	left	P	right	left	P	right	left	P
CAD	7.87 ± 0.95	7.94 ± 1.05	0.8	7.33 ± 1.37	6.9 ± 1.25	0.25	7.91 ± 1.34	7.38 ± 0.77	0.19
CMD	19.19 ± 2.06	19.14 ± 1.66	0.92	17.85 ± 2.29	17.65 ± 2.59	0.62	14.18 ± 2.28	14.02 ± 2.62	0.77
α	62.5 ± 26.84	57.57 ± 26	0.4	45.22 ± 26.56	44.55 ± 27.53	0.36	62.75 ± 25.44	62.52 ± 26.92	0.93
LCL	52.73 ± 1.87	53.86 ± 2.44	0.48	53.57 ± 3.96	52.12 ± 1.91	0.29	50.96 ± 1.48	51.78 ± 4.21	0.61
MA	132.82 ± 17.91	126.02 ± 7.1	0.45	108 ± 26.81	106.48 ± 27.21	0.62	92.42 ± 21.7	85.84 ± 13.59	0.33
AJS	2.04 ± 0.63	2.1 ± 0.79	0.86	2.04 ± 0.49	2.21 ± 0.72	0.64	1.93 ± 0.39	1.67 ± 0.71	0.27
SJS	2.91 ± 1.11	2.66 ± 0.48	0.53	3.01 ± 0.48	2.8 ± 0.6	0.42	2.41 ± 1.04	2.05 ± 1.15	0.22
PJS	1.67 ± 0.49	1.63 ± 0.56	0.58	2.19 ± 0.54	1.98 ± 0.32	0.27	2.07 ± 0.72	1.32 ± 0.63	0.12
WG	16.32 ± 2	15.75 ± 3.1	0.57	15.58 ± 1.24	15.53 ± 1.4	0.95	15.7 ± 0.88	16.39 ± 0.73	0.38
HG	8.85 ± 0.58	8.8 ± 1.44	0.94	8.41 ± 1.03	8.38 ± 1.15	0.92	8.83 ± 1.25	9.49 ± 1.43	0.05
IPA	53.3 ± 19.98	47.43 ± 15.04	0.13	51.83 ± 14.46	46.78 ± 12.64	0.28	45 ± 8.12	39.53 ± 10.48	0.12

Note: \* indicates P < 0.05.

Table III. Comparative analysis of condyle position in three groups. n=55).

Group	Condyle position(n%)		
	Anterior position	Neutral position	Posterior position
Group 1	00	28 (88)	2(12)
Group 2	00	28 (58)	20(42)
Group 3	00	24 (75)	8(25)

Table V. Results of three groups of temporomandibular joint parameters by SNK test.

Variable	P		
	1-2	1-3	2-3
MD/mm	0.35	0.009**	0.029*
AP/mm <sup>2</sup>	0.11	0.005**	0.06

Note: \* indicates P < 0.05

Table IV Result of three groups of TMJ parameters by One-way ANOVA n=55,±s

Variable	Group 1	Group 2	Group 3	F	P
OPP-FH	12.99 ± 2.43	17.19 ± 0.83	19.57 ± 0.74	21.49	<0.001**
AD	7.91 ± 0.97	7.12 ± 1.25	7.64 ± 1.04	0.64	0.55
MD	19.16 ± 1.83	17.75 ± 2.4	14.1 ± 2.4	5.45	0.023*
α	60.04 ± 25.95	44.88 ± 27.04	62.64 ± 26.1	0.67	0.53
LCL	53.3 ± 1.67	52.85 ± 2.72	51.37 ± 2.81	0.67	0.53
MA	129.42 ± 11.17	107.24 ± 26.78	81.13 ± 8.32	6.17	0.016*
AJS	2.07 ± 0.64	2.12 ± 0.45	1.8 ± 0.54	0.49	0.63
SJS	2.78 ± 0.78	2.9 ± 0.46	2.23 ± 1.07	1.01	0.4
PJS	1.65 ± 0.52	2.09 ± 0.4	1.7 ± 0.58	1.24	0.33
WG	16.03 ± 2.46	15.56 ± 0.89	16.04 ± 0.46	0.19	0.83
HG	8.82 ± 0.89	8.39 ± 1.04	9.16 ± 1.33	0.61	0.56
IPA	50.36 ± 17.45	49.31 ± 12.59	42.26 ± 9.03	0.46	0.65

Note: \* indicates P < 0.05

## DISCUSSION

The experimental design Traditional maxillary occlusal plane is defined as the line connecting the midpoint of the upper and lower incisors and the midpoint of the upper and lower first molars, nevertheless the true occlusal plane is a curved surface connected by all the incisal ridges or occlusal surface, not a line. Furthermore the posterior occlusal plane has important significance for the normal physiological function of the temporomandibular joint

(Tanaka & Sato), therefore, this study is based on the post-plane inclination to group the objects. Most of the previous related studies focused on comparing skeletal malocclusion with individual normal occlusion. In this study, patients with skeletal class I mean angle were studied individually in order to rule out the effects of differences in sagittal plane and mandibular plane angle on the results of the subjects.

TMJ symmetry may be related to skull symmetry, facial symmetry and maxillofacial muscle coordination (Al-koshab *et al.*, 2015). The occlusal factors are closely related to the morphological

structure of TMJ, the lack of teeth and sputum interference are the causes of TMJ bilateral asymmetry have been associated with tooth loss and occlusal disturb. In this study, the TMJ measurement parameters have no significantly difference between the two sides, consistent with the findings of Miranda, this may be related to the study of patients who have no joint symptoms in this study (Arieta-Miranda *et al.*, 2013). This may be related to the study of patients with no TMJ disorder. Since bilateral joint symmetry is of great significance in maintaining the balance of force in the TMJ and avoiding TMD, orthodontists should be pay attention to whether the TMJ is symmetry.

Maryam *et al.* obtained the position of the condyle in articular of patients with different sagittal skeletal and mean angle (Maryam *et al.*, 2016), most of the condylar position of class I patients were in the middle of the fossa, part of it is posterior; in class II, the condyle numerously located in posterior part of the socket, while the condylar position in class III patients is in the anterior position currently. The condyle of TMJ has different morphological and positional in patients with different types of malocclusion (Katsavrias, 2006). Patients with high class II and III had the most condylar anterior displacements (Rodrigues *et al.*, 2009). This suggests that the joint space may be related to the sagittal and vertical malocclusion. In order to evaluate the position of condyle, we measured the joint space, our findings suggested that the condylar position in three groups were mostly centered in the socket, the proportions in Group 1, Group 2, and Group 3 were 88 %, 58 %, and 75 %, respectively, were in line with the results of Paknahad *et al.* (2016). No differences were shown among group 1, 2, 3 above inclination of posterior occlusal plane, this may be related to the inclusion of skeletal class I mean-angle patients as subjects in this study.

Temporomandibular joint articular disk, as a component of craniofacial, its morphological and structure changes may affect the growth and development of the mandible by affecting the condyle, our results showed that there was no significant difference in the correlation index of the articular disk between patients with skeletal class I mean angles with different inclination of the posterior occlusal plane. In patients with skeletal class III, the articular sockets are relatively shallow and wider than those in patients with skeletal class I and range of motion of the mandible increased (Katsavrias & Halazonetis, 2005). During the craniofacial development process, the gentle posterior wall of the articular tuberosity allows the mandible to rotate more clockwise, which tends to form a blunt mandibular angle, while the steeper posterior wall of the articular tuberosity force the mandible to rotate counterclockwise during the process of mandible growth (Krisjane *et al.*, 2009). This suggests that the difference in the correlation index of the condyle is related to the formation of different types of malocclusion.

In the comparison of the morphological measurement values of the condyle, the maximum axis area and mediolateral diameter of the condyle were in the order of group 1 > group 2 > group 3 ( $P < 0.05$ ), and the difference was statistically significant ( $P < 0.05$ ). The results showed that most of the condylar condyles with small inclination were oblong in axial position, while the patients with large inclination showed ellipsoid shape. Park *et al.* (2015) found that the shape of the joint may be related to the vertical

skeletal. The condylar of high angle patients is mostly round on the axial surface, while the condyle of the patients with low angle is more of long ellipse on the axial plane. Patients with skeletal class III malocclusion have larger condylar volume and surface area than class I (Saccucci *et al.*, 2012), which may be related to the flat occlusal plane of skeletal class III patients.

CBCCT is an effective tool for clinical examination. It allows more accurate visualization of complicated anatomic structures with less radiation exposure, shorter scan time, and lower operating cost than does conventional multi slice CT, especially for analyzing TMJ morphology. By analyzing the measured parameters of temporomandibular joint in patients with different posterior occlusal plane inclination, it was found that the condylar position of the patients with skeletal class I mean angle was mostly neutral, and the condylar axis area was smaller in patients with larger inclination of the plane. Understanding normal condylar condyle morphology is conducive to the diagnosis of abnormal condylar bone changes in the clinical treatment of orthodontic treatment. In this study, the condyle morphology values of patients with skeletal class I without joint symptoms were measured, which can provide a reference for the clinical diagnosis of joint morphology and provide a certain reference for clinical orthodontists to formulate orthodontics scheme.

---

**RONG, H.; LONG, H. Q.; LIU, L. X.; XIN, L.; KYUNG, H. M.; BING, L. & WU, X. P.** Estudio clínico sobre el plano oclusal posterior y la morfología de la articulación temporomandibular. *Int. J. Morphol.*, 37(4):1347-1352, 2019.

**RESUMEN:** El objetivo de este estudio fue investigar las características morfológicas de la articulación temporomandibular (ATM) en pacientes adultos con plano oclusal posterior y diferentes inclinaciones. Se incluyeron 55 pacientes con oclusión esquelética tipo I, visualizados por tomografía computarizada de haz cónico (CBCCT) en posición intercuspiana, y se dividieron en 3 grupos según el ángulo OPP-FH. La medición morfológica de la articulación temporomandibular se calculó con CBCCT y mediante el software especial Invivo 5.0. El análisis estadístico de datos se realizó con el software SPSS 23.0. El cóndilo de la mandíbula generalmente se ubica en el centro de la fosa; el área axial máxima del cóndilo de la mandíbula (A) fue estadísticamente significativa entre los grupos 1 y 3. Los datos de los diámetros medial y lateral (DM) del cóndilo de la mandíbula fueron estadísticamente significativos entre los grupos 1 y 3 y los grupos 2 y 3. Las características morfológicas de la ATM de los tres grupos fueron básicamente simétricas. La posición del cóndilo de la mandíbula en la fosa fue principalmente centrada, y parte del área axial máxima, posterior y los diámetros medial y lateral del cóndilo de la mandíbula fueron diferentes en los tres grupos.

**PALABRAS CLAVE:** Características morfológicas; Articulación temporomandibular; Plano oclusal; Cóndilo; Tomografía computarizada de haz cónico.

## REFERENCES

- Al-koshab, M.; Nambiar, P. & John, J. Assessment of condyle and glenoid fossa morphology using CBCT in South-East Asians. *PLoS One*, 10(3):e0121682, 2015.
- Arieta-Miranda, J. M.; Silva-Valencia, M.; Flores-Mir, C.; Paredes-Sampen, N. A. & Arriola-Guillen, L. E. Spatial analysis of condyle position according to sagittal skeletal relationship, assessed by cone beam computed tomography. *Prog. Orthod.*, 14:36, 2013.
- Cordeiro, C. C.; Pozza, D. H.; Tamaki, T. & Guimarães, A. S. The importance of the posterior joint space for functional mandibular movements: A laboratory cross-sectional study. *J. Clin. Exp. Dent.*, 10(1):e61-e65, 2018.
- Katsavrias, E. G. & Halazonetis, D. J. Condyle and fossa shape in Class II and Class III skeletal patterns: a morphometric tomographic study. *Am. J. Orthod. Dentofacial Orthop.*, 128(3):337-46, 2005.
- Katsavrias, E. G. Morphology of the temporomandibular joint in subjects with Class II Division 2 malocclusions. *Am. J. Orthod. Dentofacial Orthop.*, 129(4):470-8, 2006.
- Kim, J. I.; Hiyama, T.; Akimoto, S. & Shinji, H. Longitudinal study regarding relationship among vertical dimension of occlusion, cant of occlusal plane and antero-posterior occlusal relation. *Bull. Kanagawa Dent. Coll.*, 41(1):31-42, 2006.
- Krisjane, Z.; Urtane, I.; Krumina, G. & Zepa, K. Three-dimensional evaluation of TMJ parameters in Class II and Class III patients. *Stomatologija*, 11(1):32-6, 2009.
- Marchiori, E. C.; Garcia, R. R. & Moreira, R. W. Importance of occlusal plane reproduction on the semi-adjustable articulator in planning maxillary impactions for orthognathic surgery. *Oral Maxillofac. Surg.*, 17(2):109-14, 2013.
- Paknahad, M.; Shahidi, S. & Abbaszade, H. Correlation between condylar position and different sagittal skeletal facial types. *J. Orofac. Orthop.*, 77(5):350-6, 2016.
- Park, I. Y.; Kim, J. H. & Park, Y. H. Three-dimensional cone-beam computed tomography based comparison of condylar position and morphology according to the vertical skeletal pattern. *Korean J. Orthod.*, 45(2):66-73, 2015.
- Pullinger, A. & Hollender, L. Variation in condyle-fossa relationships according to different methods of evaluation in tomograms. *Oral Surg. Oral Med. Oral Pathol.*, 62(6):719-27, 1987.
- Rodrigues, A. F.; Fraga, M. R. & Vitral, R. W. Computed tomography evaluation of the temporomandibular joint in Class II Division 1 and Class III malocclusion patients: condylar symmetry and condyle-fossa relationship. *Am. J. Orthod. Dentofacial Orthop.*, 136(2):199-206, 2009.
- Saccucci, M.; D'Attilio, M.; Rodolfo, D.; Festa, F.; Polimeni, A. & Tecco, S. Condylar volume and condylar area in class I, class II and class III young adult subjects. *Head Face Med.*, 8:34, 2012.
- Shetty, S.; Zargar, N. M.; Shenoy, K. & D'Souza, N. Position of occlusal plane in dentate patients with reference to the ala-tragal line using a custom-made occlusal plane analyzer. *J. Prosthodont.*, 24(6):469-74, 2015.
- Tabrizi, R.; Shahidi, S.; Bahramnejad, E. & Arabion, H. Evaluation of condylar position after orthognathic surgery for treatment of class II vertical maxillary excess and mandibular deficiency by using Cone-Beam computed tomography. *J. Dent. (Shiraz)*, 17(4):318-25, 2016.
- Tanaka, E. M. & Sato, S. Longitudinal alteration of the occlusal plane and development of different dentoskeletal frames during growth. *Am. J. Orthod. Dentofacial Orthop.*, 134(5):602.e1-11, 2008.
- Ueki, K.; Nakagawa, K.; Takatsuka, S.; Yamamoto, E. & Laskin, D. M. Comparison of the stress direction on the TMJ in patients with class I, II, and III skeletal relationships. *Orthod. Craniofac. Res.*, 11(1):43-50, 2008.

Corresponding author:

Li Bing & Xiu-Ping Wu  
Stomatology Hospital  
Shanxi Medical University  
63 Xinjian Road  
Taiyuan 030001  
CHINA

Email: libing-1975@163.com

Received: 13-04-2019

Accepted: 21-06-2019