

Foramen Venosum: Prevalence, Patency and Correlation with Cephalic Index

Foramen Venoso: Prevalencia, Permeabilidad y Correlación con el Índice Cefálico

Jefferson Sing Toledo Junior*; **Marcondes Silva de Lima***; **Marley Moreira Correia***;
Rafael Rodrigues Coutinho* & **Diego de Faria Magalhães Torres****

TOLEDO JUNIOR, J. S.; SILVA DE LIMA, M.; MOREIRA CORREIA, M.; RODRIGUES COUTINHO, R. & MAGALHÃES TORRES, D. F. *Foramen Venosum: prevalence, patency and correlation with cephalic index. Int. J. Morphol.*, 34(4):1328-1332, 2016.

SUMMARY: The *foramen venosum* (FV) is an anatomical structure situated at the base of the skull, generally posteromedial to the foramen rotundum and anteromedial to the foramen ovale. Its prevalence and patency may be related to the shape of the skull. The objective of this study was to verify the prevalence and patency of the FV and its association with the different skull types. Overall, 143 dry skulls were screened. Of these, 84 were considered to be in an adequate state of conservation and were included in the analysis, which was conducted through a cross-sectional view of the skullcap. The transverse (T) and anteroposterior (AP) diameters of the skull were evaluated by pachymetry and the skull type was classified according to the cephalic index (CI) ($CI = T/AP \times 100$). The presence and patency of the FV were evaluated. Overall, 25 % of the skulls were dolichocephalic, 21.4 % sub-dolichocephalic, 26.2 % mesaticephalic, 16.7 % sub-brachycephalic and 10.7 % brachycephalic. Overall, the FV was found in 41.6 % of the skulls (n=35), with this prevalence being greater in the mesaticephalic skulls (50 %; n=11). Patency was 25 % (n=21). A positive correlation was found between the CI and the presence of the FV in dolichocephalic skulls (on the right-hand side only) and in sub-brachycephalic skulls (bilaterally). In conclusion, the prevalence of the FV was considerable in the sample analyzed and was directly associated with the CI in dolichocephalic and sub-brachycephalic skulls.

KEY WORDS: Anatomy; Base of the skull; Craniometry; *Foramen venosum*.

INTRODUCTION

The small *foramen venosum* (FV) is generally situated posteromedially to the foramen rotundum and anteromedially to the foramen ovale, the foramen spinosum and the carotid canal, with the foramen ovale being the closest structure to the FV (Chaisuksunt *et al.*, 2012). Its frequency in human skulls is extremely variable, ranging from 5 % to 80 % (Aviles-Solis *et al.*, 2011; Lazarus *et al.*, 2015).

The FV gives passage to an emissary vein that connects the pterygoid venous plexus with the cavernous sinus (Aviles-Solis *et al.*). It has also been reported that a small nerve (the nervulus sphenoidalis lateralis) may cross the foramen and the cavernous sinus. Another variation is the passage of the accessory meningeal artery through the FV in 20 % of cases (Gupta *et al.*, 2005).

The prevalence of the FV may be associated with the different skull shapes, described in the literature as a function of the cephalic index (CI), according to which skulls are classified as: dolichocephalic, sub-dolichocephalic, mesaticephalic, sub-brachycephalic and brachycephalic (Testut & Jacob, 1952). The CI is measured by craniometry, a technique performed to complement visual inspection of the cranium (cranioscopy). Craniometry corrects observer subjectivity and provides information on the morphologic variations in human skulls, enabling associations to be made between morphological characteristics and specific clinical conditions (Pereira & Alvim, 1979; Seema & Verma, 2016).

The variations in the FV can be explained by the complex formation of the sphenoid bone during the embryological period

* Medical School, Estácio de Sá University (UNESA), Rio de Janeiro, RJ, Brazil

** University Hospital of the Federal University of Rio de Janeiro (UFRJ), Rio de Janeiro, RJ, Brazil.

and also because the location of the FV is a site of sphenoid bone fusion. Before the mesenchyme condenses to form the cartilage of the skull, the vessels and nerves are already in place (Gupta *et al.*; Raval *et al.*, 2015). The objective of the present study was to verify the prevalence and patency of the FV and its association with the different skull types.

MATERIAL AND METHOD

This was a descriptive, observational study in which dry skulls obtained from anatomy laboratories at universities in Rio de Janeiro, Brazil were selected. The internal review board of the Estácio de Sá University, Rio de Janeiro approved the study protocol. Skulls in an adequate state of conservation were included in the study and prepared for

analysis, which was conducted through a cross-sectional view of the skullcap. The following craniometric points were taken into consideration: the glabella-inion line (anteroposterior diameter) and the eurion-aurion distance (transverse diameter) (Pereira & Alvim).

The transverse (T) and anteroposterior (AP) diameters were then used to calculate the cephalic index (CI): $(CI = T / AP \times 100)$. The presence and patency of the FV were recorded. To perform craniometry, a 200 mm pachymeter (Marberg®) was used. Simple observation was used to establish the presence of the FV and photographic evidence was obtained (Fig. 1). A 0.30 mm nylon thread (Dourado Premium®) was used to test for patency.

The Sigmastat software program, version 3.1 (Systat Software, Inc., Point Richmond, CA, USA) was used for the statistical analysis. Normal distribution was assessed by the Kolmogorov-Smirnov test. Pearson's test was used to analyze the measures of association between variables and Student's t-test for comparisons. The differences and correlations were considered statistically significant when $p < 0.05$.

RESULTS

A total of 143 dry skulls were screened. Of these, 84 fulfilled the established inclusion criteria and were selected for analysis. These skulls were found to be relatively heterogeneous with respect to the cephalic index classification: 25 % of the skulls were classified as dolichocephalic, 21.4 % as sub-dolichocephalic, 26.2 % as mesocephalic, 16.7 % as sub-brachycephalic and 10.7 % as brachycephalic (Fig. 2).

Overall, the FV was present in 41.6 % of the skulls ($n=35$). In 30.9 % of cases, it was present on the right-hand side and in 27.3 % of cases on the left-hand side, with patency of 38.4

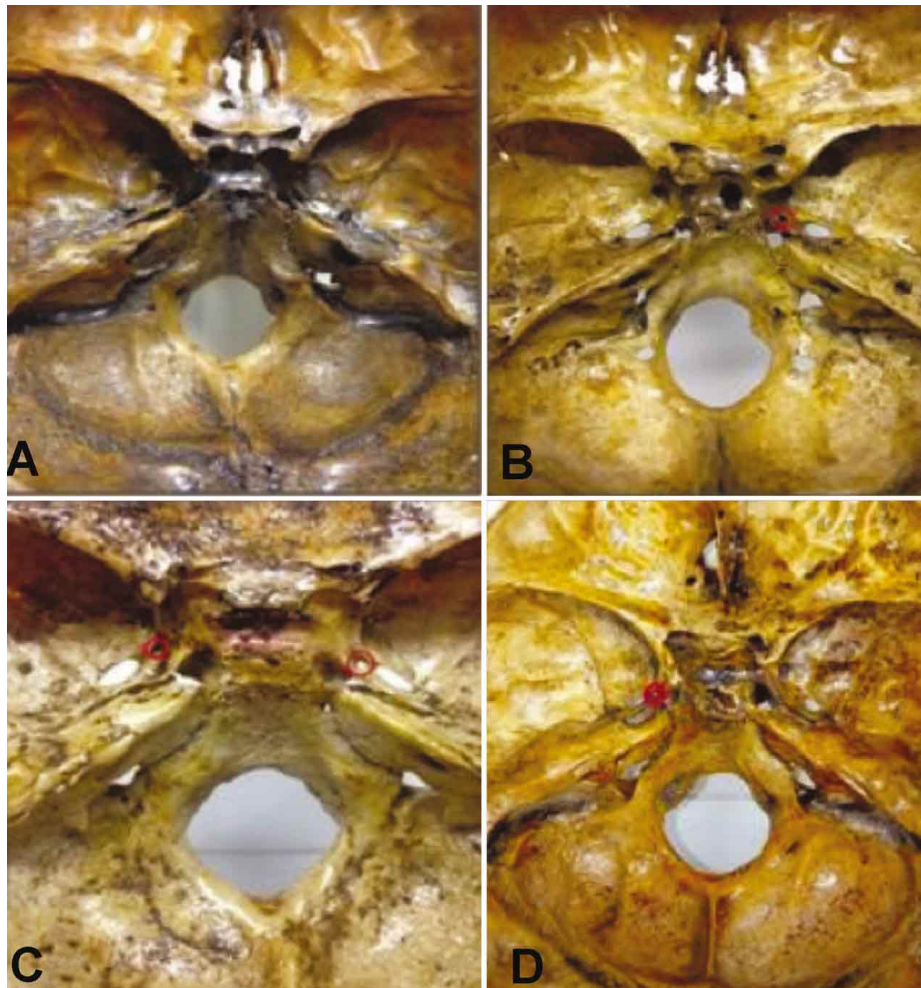


Fig. 1. Upper view of the base of the skull. A) Foramen venosum absent; B) Foramen venosum situated unilaterally, on the right-hand side (red); C) Upper view from the internal base of the skull showing the foramen venosum situated bilaterally (red); D) Foramen venosum situated unilaterally, on the left-hand side (red).

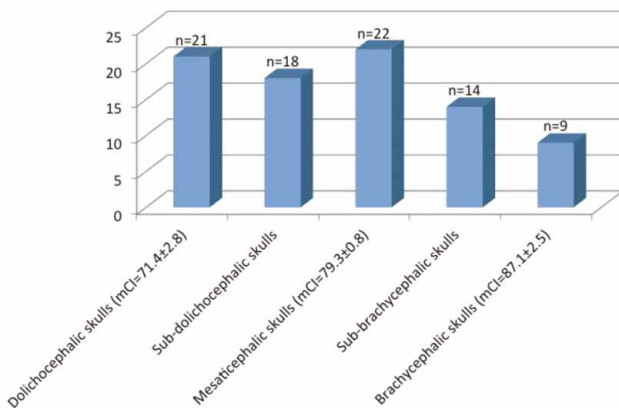


Fig. 2. Classification in accordance with the cephalic index. mCI: mean cephalic index.

% and 65.2 %, respectively. The analysis according to each skull type is summarized in Table I.

When the CI for each type of skull was correlated with the prevalence of the FV on each side and as a whole, a positive association was found between dolichocephalic skulls and unilateral FV situated on the right-hand side ($p < 0.01$; $r = 0.54$) and between sub-brachycephalic skulls and bilateral FV ($p < 0.01$; $r = 0.74$) (Table II).

After refining the analysis and taking only the CI from the skulls in which the FV was present bilaterally into consideration ($n = 14$), no associations were found with patency, either for the right-hand side ($p = 0.61$; $r = 0.14$) or for the left-hand side ($p = 0.36$; $r = 0.26$).

Table I. Prevalence and patency of the Foramen venosum (FV).

Skull type	n (%)	Prevalence of FV (right-hand side) (%)	Patency of FV (right-hand side) (%)	Prevalence of FV (left-hand side) (%)	Patency (left-hand side) (%)
Dolichocephalic	21 (25)	4 (19)	0 (0)	4 (19)	1 (25)
Sub-dolichocephalic	18 (21.4)	5 (27.8)	4 (80)	2 (11.1)	1 (50)
Mesaticephalic	22 (26.2)	9 (40.9)	5 (55.5)	10 (45.4)	7 (70)
Sub-brachycephalic	14 (16.7)	5 (35.7)	0 (0)	7 (50)	6 (85)
Brachycephalic	9 (10.7)	3 (33.3)	1 (33.3)	0 (0)	0 (0)
Total	84 (100)	26 (30.9)	10 (38.4)	23 (27.3)	15 (65)

Table II. Association between cephalic index and the foramen venosum (FV).

	Dolichocephalic	Sub-dolichocephalic	Mesaticephalic	Sub-brachycephalic	Brachycephalic	Total
CI vs FV on the right	* $p < 0.0$; $r = 0.54$	$p = 0.55$; $r = 0.14$	$p = 0.9$; $r = 0.02$	* $p < 0.001$; $r = 0.78$	$p = 0.9$; $r = 0.04$	$p = 0.79$; $r = -0.02$
CI vs FV on the left	$p = 0.07$; $r = 0.39$	$p = 0.17$; $r = -0.33$	$p = 0.76$; $r = 0.002$	* $p = 0.02$; $r = 0.61$	$p = 0.28$; $r = 0.4$	$p = 0.96$; $r = 0.004$
CI vs FV overall	$p = 0.07$; $r = 0.4$	$p = 0.75$; $r = -0.07$	$p = 0.87$; $r = -0.03$	* $p < 0.01$; $r = 0.74$	$p = 0.9$; $r = 0.04$	$p = 0.74$; $r = -0.03$

* $p < 0.05$; CI: cephalic index;

DISCUSSION

The *foramen venosum* has already been investigated in human skulls in several studies conducted with different populations and it is now an established fact that this structure is not always present and is not always found bilaterally. In the present study, 84 skulls were analyzed, with the FV being found in 35 (41.6 %). In 14 of these, the FV was present bilaterally (16.6 %), with 4 being patent. In 23 skulls (27.3 %), the FV was on the left-hand side alone, and was patent in 18 cases. In 26 skulls (30.9 %), the FV was only on the right-hand side and in 10 of these cases it was patent.

Chaisuksunt *et al.*, analyzed 377 skulls from universities in Thailand and reported that the FV was present in 65 skulls (17.2 %), unilaterally in 48/377 cases (12.7 %) and bilaterally in 17/377 (4.5 %). According to Aviles-Solis *et al.*, of the 30 skulls analyzed in their study in Mexico, the FV was present unilaterally in 6, being situated on the right-hand side in 3 cases and on the left-hand side in the remaining 3 cases. It was not present bilaterally in any cases. Shinohara *et al.* (2010), analyzed 400 skulls from a laboratory in São Paulo, Brazil, using an imaging method. The FV was found in 135 skulls (33.75 %), bilaterally in 15.5 % and unilaterally in 18.25 %, predominantly on the left-hand side (10.5 %).

In a similar study, also in São Paulo, Rossi *et al.* (2010), evaluated 80 skulls, with the FV being present in 32 (40 %). In 11 of these skulls (13.75 %), the FV was present bilaterally, while in 21 (26.25 %) it was unilateral, predominantly on the right-hand side (31.25 %). Raval *et*

al., evaluated 150 skulls in India and reported the presence of the FV in 60 % (n=90), with the most common presentation being bilateral (32.2 %). Lanzieri *et al.*, (1988) evaluated 54 skulls and reported the presence of the FV in 34 (62.3 %). Kodama *et al.* (1997), evaluated the difference in the prevalence of the FV between adult and juvenile skulls. A total of 420 skulls were analyzed: 20 juvenile skulls and 400 adult skulls, with the FV being found in 11 of the juvenile skulls (55 %) and in 87 of the adult skulls (21.75 %).

In addition, Raval *et al.*, reported a difference in the diameters of the FV on the different sides, with the diameter on the left-hand side being greater (1.12 ± 0.73 mm). Shinohara *et al.*, also evaluated diameter and reported a mean diameter of 0.65 mm, with this measurement being greater on the left-hand side (1.07 ± 0.37 mm). None of the studies conducted up to the present time had correlated the prevalence, patency and cephalic index, as evaluated in the present study, in a search for possible associations applicable in a clinical and surgical context.

During the approach through the foramen ovale for the treatment of trigeminal neuralgia by rhizotomy, errors involving puncture (false puncture) represent a possible complication. In such cases, the principal structure penetrated is the FV due to its topographic proximity (Sindou *et al.*, 1987; Freire *et al.*, 2013). Shinohara *et al.*, described a mean distance between the FV and the foramen ovale of 2.55 mm on the right-hand side and 2.59 mm on the left-hand side. Chaisuksunt *et al.*, reported a mean distance between the FV and the foramen ovale of 2.05 ± 1.09 mm. In agreement with these findings, Ozer *et al.* (2014), reported the mean distance between the FV and the foramen ovale as being 2.30 ± 1.14 mm on the right-hand side and 2.46 ± 0.89 mm on the left-hand side.

The topographic proximity of these structures may result in iatrogenic puncture of the cavernous sinus (Gusmão *et al.*, 2003), which could result in hemorrhage in the parietal lobe (Sweet, 1990). Sindou *et al.* reported the occurrence of this complication in 7 out of 200 cases (3.5 %). Nevertheless, it is important to emphasize that, according to Lanzieri *et al.*, in the absence of the FV, the emissary vein may become contained in the foramen ovale.

Karlin & Robinson (1984) reported that due to the communication between the pterygoid venous plexus and the cavernous sinus through the emissary veins (venosum), thrombophlebitis and/or septic thrombosis may occur as the result of suppurating processes in the orbital regions, from the paranasal sinuses, from the upper half of the face and, rarely, from dental infections. In another study, Lanzieri *et al.*, affirmed that the asymmetry between the FV on the different sides could be associated with an infiltration of the emissary veins by tumors such as nasopharyngeal melanomas and juvenile angiofibromas as well as carotid-cavernous fistulas.

When associating the presence of the FV with the cephalic index, a stronger correlation was found between the sub-brachycephalic skull and bilateral FV and between dolichocephalic skulls and unilateral FV situated on the right-hand side, leading to clinical reflection on the importance of preoperative morphometric evaluation.

In conclusion a correlation was found in this study sample between the cephalic index (in the sub-brachycephalic and dolichocephalic skulls) and the prevalence of the *foramen venosum*, highlighting the importance of being aware of the morphometry of the skull prior to performing certain surgical procedures and of being able to predict possible complications in this topography.

TOLEDO JUNIOR, J. S.; SILVA DE LIMA, M.; MOREIRA CORREIA, M.; RODRIGUES COUTINHO, R. & MAGALHÃES TORRES, D. F. Foramen venoso: prevalencia, la permeabilidad y la correlación con el índice cefálico. *Int. J. Morphol.*, 34(4):1328-1332, 2016.

RESUMEN: El foramen venoso (FV) es una estructura anatómica situada en la base del cráneo, en general, posteromedial al foramen redondo y anteromedial al foramen oval. Su prevalencia y permeabilidad pueden estar relacionados con la forma del cráneo. El objetivo de este estudio fue verificar la prevalencia y permeabilidad del FV y su asociación con los diferentes tipos de cráneo. Se estudiaron 143 cráneos secos. De éstos, 84 fueron considerados en estado adecuado de conservación y se incluyeron en el análisis, realizado mediante la visualización de una sección transversal del cráneo. Los diámetros transversal (T) y anteroposterior (AP) del cráneo se evaluaron mediante paquimetría y el tipo de cráneo se clasificó de acuerdo con el índice cefálico (IC) ($IC = T/AP \times 100$). Se evaluó también la presencia y permeabilidad del FV. El análisis mostró que 25 % de los cráneos eran dolicocefálicos, 21,4 % subdolicocefálicos, 26,2 % mesaticéfalos, 16,7 % sub-braquicéfalos y 10,7 % de braquicéfalos. El FV se encontró en 41,6 % de los cráneos (n=35), con prevalencia mayor en los cráneos mesaticéfalos (50 %, n=11). La permeabilidad fue del 25 % (n=21). Se encontró una correlación positiva entre el IC y la presencia del FV en cráneos dolicocefálicos (sólo en el lado derecho) y en sub-braquicéfalos (bilateral). En conclusión, la prevalencia del FV fue considerable en la muestra analizada y se asocia directamente con el IC en cráneos dolicocefálicos y sub-braquicéfalos.

PALABRAS CLAVE: Anatomía; Base de cráneo; Craneometría; Foramen venoso.

REFERENCES

- Aviles-Solis, J. C.; Olivera-Barrios, A.; De la Garza, O.; Elizondo-Omaña, R. E. & Guzmán-López, S. Prevalence and morphometric characteristics *foramen venosum* in Northeastern Mexico skulls. *Int. J. Morphol.*, 29(1):158-63, 2011.
- Chaisuksunt, V.; Kwathai, L.; Namonta, K.; Rungruang, T.; Apinhasmit, W. & Chompoopong, S. Occurrence of the foramen of Vesalius and its morphometry relevant to clinical consideration. *Scientific World J.*, 2012:817454, 2012.
- Freire, A. R.; Rossi, A. C.; de Oliveira, V. C. S.; Prado, F. B.; Carria, P. H. F. & Botacin, P. R. Emissary foramina of the human skull: Anatomical characteristics and its relations with clinical neurosurgery. *Int. J. Morphol.*, 31(1):287-92, 2013.
- Gupta, N.; Ray, B. & Ghosh, S. Anatomic characteristics of foramen vesalium. *Kathmandu Univ. Med. J. (KUMJ)*, 3(2):155-8, 2005.
- Gusmão, S.; Magaldi, M. & Arantes, A. I. Trigeminal radiofrequency rhizotomy for the treatment of trigeminal neuralgia: results and technical modification. *Arq. Neuropsiquiatr.*, 61(2B):434-40, 2003.
- Karlin, R. J. & Robinson, W. A. Septic cavernous sinus thrombosis. *Ann. Emerg. Med.*, 13(6):449-55, 1984.
- Kodama, K.; Inoue, K.; Nagashima, M.; Matsumura, G.; Watanabe, S. & Kodama, G. Studies on the foramen vesalium in the Japanese juvenile and adult skulls. *Hokkaido Igaku Zasshi*, 72(6):667-74, 1997.
- Lanzieri, C. F.; Duchesneau, P. M.; Rosenbloom, S. A.; Smith, A. S. & Rosenbaum, A. E. The significance of asymmetry of the foramen of Vesalius. *A. J. N. R. Am. J. Neuroradiol.*, 9(6):1201-4, 1988.
- Lazarus, L.; Naidoo, N. & Satyapal, K. S. An osteometric evaluation of the foramen spinosum and venosum. *Int. J. Morphol.*, 33(2):452-8, 2015.
- Ozer, M. A. & Govsa, F. Measurement accuracy of foramen of vesalium for safe percutaneous techniques using computer-assisted three-dimensional landmarks. *Surg. Radiol. Anat.*, 36(2):147-54, 2014.
- Pereira, C. B. & Alvim, M. C. M. *Manual para Estudos e Cranioscópicos*. Santa Maria, Imprensa Universitária da Universidade Federal de Santa Maria, 1979.
- Raval, B. B.; Singh, P. R. & Rajguru, J. A A morphologic and morphometric study of foramen vesalium in dry adult human skulls of gujarat region. *J. Clin. Diagn. Res.*, 9(2):AC04-7, 2015.
- Seema & Verma, P. The study of cephalic index in North Indian population. *Int. J. Morphol.*, 34(2):660-4, 2016.
- Shinohara, A. L.; de Souza Melo, C. G.; Silveira, E. M.; Lauris, J. R.; Andreo, J. C. & de Castro Rodrigues, A. Incidence, morphology and morphometry of the foramen of Vesalius: complementary study for a safer planning and execution of the trigeminal rhizotomy technique. *Surg. Radiol. Anat.*, 32(2):159-64, 2010.
- Sindou, M.; Keravel, Y.; Abdennebi, B. & Szapiro, J. Neurosurgical treatment of trigeminal neuralgia. Direct approach of percutaneous method? *Neurochirurgie*, 33(2):89-111, 1987.
- Sweet, W. H. *Treatment of Trigeminal Neuralgia by Percutaneous Rhizotomy*. In: Youmans, J. R. (Ed.). *Neurological Surgery: A Comprehensive Reference Guide to the Diagnosis and Management of Neurosurgical Problems*. Philadelphia, W. B. Saunders Co., 1990. pp.3888-921.
- Testut, L. & Jacob, O. *Anatomia Topográfica*. Vol. I. 8ª ed. Barcelona, Salvat Editores S. A., 1952.

Correspondence to:
Diego de Faria Magalhães Torres
Professor, Estácio de Sá University (UNESA) and
University Hospital of the Federal University of Rio de Janeiro (UFRJ)
Rio de Janeiro, RJ.
BRAZIL.

Email: diegofmtorres@gmail.com

Received:29-08-2016

Accepted:22-09-2016