

A Communicating Branch between the Dorsal and Superficial Ramus of the Ulnar Nerve (Kaplan's Anastomosis) – Clinical and Surgery Discussion

Ramo Comunicante entre los Ramos Dorsal y Superficial del Nervio Ulnar (Anastomosis de Kaplan) - Discusión Clínica y Quirúrgica

Torre, F.*; Erthal, R.*; Fernandes, R. M. P.*; Babinski, M. A.* & Cisne, R.**

TORRE, F.; ERTHAL, R.; FERNANDES, R. M. P.; BABINSKI, M. A. & CISNE, R. A communicating branch between the dorsal and superficial ramus of the ulnar nerve (Kaplan's anastomosis) – clinical and surgery discussion. *Int. J. Morphol.*, 33(3):865-867, 2015.

SUMMARY: The Kaplan's anastomosis represents the communication between the dorsal and superficial branch of the ulnar nerve distal to ulnar canal. In the present study, a case about this nerve communication, found in a male adult cadaver, is reported. Information about brachial plexus distal anastomosis is fundamental for interpretation of clinical and electrophysiological findings, in order to establish the precise diagnosis of neurological lesions at this level. Its relations with flexor carpi ulnaris muscle's tendon and with pisiform bone exposes it to iatrogenic lesions during surgery.

KEY WORDS: Kaplan's anastomosis; Ulnar nerve; Nerve lesion.

INTRODUCTION

The upper limb buds lie opposite to the lower five cervical and upper two thoracic segments. As soon as the buds form, the ventral primary rami of the spinal nerves penetrate into the mesenchyme of limb bud. Immediately the nerves enter the limb bud, they establish intimate contact with the differentiated mesodermal condensations and the early contact between nerve and muscle cell is a prerequisite for the incomplete functional differentiation (Saddler, 2006).

The growth as well as the path finding of nerve fibers towards the target is dependent upon concentration gradient of a group of cell surface receptors on the environment (Williams *et al.*, 1999) Several signaling molecules and transcription factors which induce the differentiation of the dorsal and ventral motor horn cells have been identified. Signaling of any of these molecules can lead to abnormalities in the formation and distribution of particular nerve fibers (Williams *et al.*).

The ulnar nerve is divided into superficial and dorsal branches at the level of the average distance between proximal and distal margins of the flexor retinaculum, very close to the radial side of pisiform. The superficial branch

of ulnar nerve (SBUN), given the common palmar digital nerve of the fourth interosseous space, where it divides into ulnar proper palmar digital nerve of the ring finger and the radial proper palmar digital nerve of the little toe, as well as issue the proper palmar digital nerve finger ulnar latter (Pacheco & Olave, 2009). The dorsal branch of the ulnar nerve (DBUN) continues in distal direction, close to flexor carpi ulnaris muscle, passing through the muscular fasciae and continues on the medial part of dorsal side of hand. Then, it is divided in two or three dorsal digital nerves (Bonnel & Vila, 1985).

The anomalous branch, known as Kaplan anastomosis, was originally described by Kaplan in 1963, as a communication which was originated from the DBUN, crossing from the posterior to the anterior side, close to the pisiform bone, anastomosing with the superficial branch of the ulnar nerve (SBUN), close to the ulnar canal (Kaplan, 1963). After this study, some descriptions of other anastomosis variations have been reported, changing only the communication point of the branch, since the ulnar trunk goes the fifth finger as the proper digital branch for the latter (Hoogbergen & Kauer, 1992).

* Department of Morphology, Biomedical Center, Fluminense Federal University, RJ, Brazil.

** Department of Surgery, Faculty of the Veterinary Medicine and Zootecny, São Paulo University, São Paulo, Brazil.

CASE REPORT

This case report follows the Declaration of Helsinki from 1995. During a workaday dissection at the Morphology Department of Federal Fluminense University, it was observed, in a male adult cadaver fixed in 10% formaldehyde, a tenuous communication between DBUN and SBUN at forearm distal extremity (Fig. 1).

Close to styloid process, the branch contours the hand dorsal side and goes to the ventral side, passing through medial and distal border of pisiform bone. It continues by crossing deep at the pisohamate ligament and communicating with the ulnar nerve, near to ulnar canal (Fig. 1).

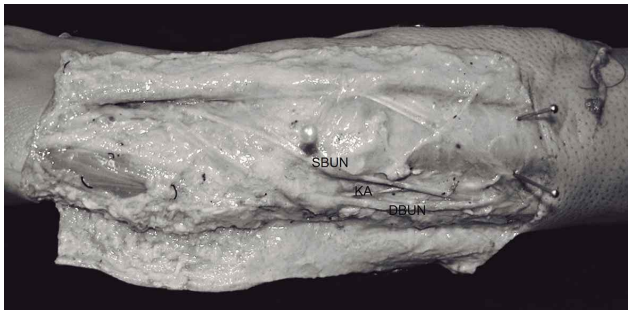


Fig. 1. Kaplan's anastomosis showing communication with the ulnar trunk proximally to its division in superficial and deep branch. DBUN dorsal branch of ulnar nerve; SBUN superficial branch of ulnar nerve; KA Kaplan's anastomosis.

DISCUSSION

This anatomical variation drew attention because there are few studies about it in the literature, and no Brazilian reports were found as well.

Hankins & Flemming (2005) described a classification for the variations of Kaplan's anomalies: type 1, communication with the ulnar trunk proximally to its division in superficial and deep branch; type 2, proximal communication with the superficial branch; type 3, proximal communication with deep branch; type 4, communication with proper digital nerve for the lateral side of little finger in the middle of hypothenar; type 5, communication with proper digital nerve for the lateral side of little finger close to proximal interphalangeal articulation; type 6, it passes to the lateral palmar side of little finger with no communication with ulnar nerve (Hankins & Flemming). According to Hankins & Flemming, this case would be better classified in type 1.

The Kaplan's anastomosis, because of its particular relation with flexor carpi ulnaris muscles tendon and pisiform bone, may be wounded during Dupuytren's contracture surgery and other procedures which access the area near the anastomosis. Besides that, the understanding of this anatomic variation can help clinic and electromyography's diagnose of peripheral nerve lesions, as this anomalous branch might contain both sensory and motor fibers of palmar region. This knowledge could be applicable in cases of pain and sensory loss in the region of anastomosis during injuries or procedures (O'Hara & Stone, 1988; Zook et al., 1988).

As an example, a case reported by McCarthy & Nalebuff (1980) where there were suggestive symptoms of flexor carpi ulnaris muscles tendon tendinitis. It was found an adherence between the Kaplan's anastomosis and pisiform bone during an explorer surgery. This adherence was revised bringing relief to the patient's symptoms (McCarthy & Nalebuff).

Therefore, as there are not many cases in literature, our attention has been drawn to the importance of research about anatomical variations, such as Kaplan's anastomosis, in order to improve knowledge and create solutions to correct surgical and clinical anomalous findings.

ACKNOWLEDGMENTS

The authors express gratitude for Emerson. M. Casagrande and Luis F. Amâncio, who contributed for the preparation of the cadaveric piece.

TORRE, F.; ERTHAL, R.; FERNANDES, R. M. P.; BABINSKI, M. A. & CISNE, R. Ramo comunicante entre los ramos dorsal y superficial del nervio ulnar (anastomosis de Kaplan) - Discusión clínica y quirúrgica. *Int. J. Morphol.*, 33(3):865-867, 2015.

RESUMEN: La anastomosis de Kaplan representa la comunicación entre la rama dorsal y superficial del nervio ulnar distal al canal ulnar. En el presente estudio se informa de un caso de esta comunicación nerviosa, encontrado en un cadáver adulto de sexo masculino. Información sobre el plexo braquial y sus anastomosis distales son fundamentales para la interpretación de los hallazgos clínicos y electrofisiológicos, a fin de establecer el diagnóstico preciso de las lesiones neurológicas a este nivel. Sus relaciones con el tendón del músculo flexor ulnar del carpo, como con el hueso pisiforme, pueden facilitar la ocurrencia de lesiones iatrogénicas durante la cirugía.

PALABRAS CLAVE: Anastomosis de Kaplan; Nervio ulnar; Lesión nerviosa.

REFERENCES

- Bonnel, F. & Vila, R. M. Anatomical study of the ulnar nerve in the hand. *J. Hand Surg Br.*, 10(2):165–168, 1985.
- Hankins, C. L. & Flemming, S. A variant of Kaplan's accessory branch of the dorsal cutaneous branch of the ulnar nerve: a case report and review of the literature. *J. Hand Surg. Am.*, 3(6):1231-5, 2005.
- Hoogbergen, M. M. & Kauer, J. M. An unusual ulnar nerve median nerve communicating branch. *J. Anat.*, 181(Pt. 3):513-6, 1992.
- Kaplan, E. B. Variation of the ulnar nerve at the wrist. *Bull. Hosp. Joint Dis.*, 24:85-8, 1963.
- McCarthy, R. E. & Nalebuff, E. A. Anomalous volar branch of the dorsal cutaneous ulnar nerve: A case report. *J. Hand Surg. Am.*, 5(1):19-20, 1980.
- O'Hara, J. J. & Stone, J. H. Ulnar neuropathy at the wrist associated with aberrant flexor carpi ulnaris insertion. *J. Hand Surg. Am.*, 13(3):370-2, 1988.
- Pacheco, J. P. & Olave, E. Contribución proximal del nervio ulnar para la formación del nervio digital palmar propio ulnar del dedo mínimo. *Int. J. Morphol.*, 27(4):1169-72, 2009.
- Saddler, T. W. *Langman's Medical Embryology*. In: Muscular system. 10th ed. Philadelphia, Lippincott Williams and Wilkins, 2006. pp.146-7.
- Williams, P. L.; Bannister, L. H.; Berry, M. M.; Collins, P.; Dussek, J. E. & Ferguson, M. W. J. *Gray's Anatomy*. In: Embryology and development. 38th ed. London, Churchill Livingstone, 1999. pp.231-2.
- Zook, E. G.; Kucan, J. O. & Guy, R. J. Palmar wrist pain caused by ulnar nerve entrapment in the flexor carpi ulnaris tendon. *J. Hand Surg. Am.*, 13(5):732-5, 1988.

Correspondence to:
Prof. Rafael Cisne
Departamento de Morfologia – Instituto Biomédico – UFF
Rua: Prof. Ernani Melo 101 (Anatomia), São Domingos
24210-150 – Niterói (RJ)
BRAZIL

Email: rafael.cisne@gmail.com

Received: 25-02-2013
Accepted: 19-11-2013