

Prevalence and Distribution of Sesamoid Bones of the Hand. A Radiographic Study in Turkish Subjects

Prevalencia y Distribución de los Huesos Sesamoideos de la Mano;
Un Estudio Radiográfico en Sujetos Turcos

*Ozkan Kose; *Ferhat Guler; *Adil Turan; **Kerem Canbora & *Serdar Akalin

KOSE, O; GULER, F.; TURAN, A.; CANBORA, K. & AKALIN, S. Prevalence and distribution of sesamoid bones of the hand. A radiographic study in Turkish subjects. *Int. J. Morphol.*, 30(3):1094-1099, 2012.

SUMMARY: The purpose of this study was to examine the plain anteroposterior radiographs of the hands in Turkish subjects in order to determine the prevalence of sesamoid bones and their distribution. A total of 923 hand radiographs from 459 men and 464 women with a mean age of 43.76 ± 14.8 years (range, 18-85 years) were examined. Two sesamoid bones (ulnar and radial) were always present at the metacarpophalangeal (MCP) joint of the thumb (100%). One sesamoid bone in the thumb interphalangeal (IP) joint was observed in 21.3% of the cases. The prevalence of sesamoid bone of the index and little MCP joint were 36.6% and 53.2% respectively. Sesamoid bones palmar to the MCP joints of the middle finger and ring finger were rare; the incidence for these locations being 1.3% (12 hands) and 0.9% (8 hands), respectively. There were no significant differences between left and right hand digits. The distribution of sesamoid bones in different locations between male and female subjects were statistically similar in 1st IP joint ($p=0.530$), 4th MCP ($p=0.631$), 5th MCP ($p=0.067$) joints. However, the sesamoid bones in 2nd MCP and 3rd MCP joints were statistically more frequent in female subjects ($p=0.024$ and $p=0.018$ respectively). The present study represents the first report on the prevalence and distribution of sesamoid bones in the hand in Turkish subjects. The prevalence of sesamoid bones in Turkish population is considerably different from the Africans and Europeans, but rather resembles Mediterranean and Arab populations.

KEY WORDS: Sesamoid bone; Hand; Prevalence; Turkish population

INTRODUCTION

Sesamoid bones are small round or oval shaped nodules that are imbedded within certain tendons. They are called sesamoid bones, because they are similar in size and shape to the flat oval seed of *Sesamum Indicum*, an ancient East Indian plant used for purging by the Greeks (Amar *et al.*, 2011; Wood, 1984). Sesamoid bones are typically found in locations where a tendon passes over a joint, such as the hand, wrist, knee, and foot. Sesamoid bones have some functions. They act to protect the tendon and to increase its mechanical effect by holding the tendon further away from the center of the joint thus increasing its lever arm. Furthermore, they modify the pressure, diminish the friction and, occasionally alter the direction of muscle pull (Amar *et al.*; Sarin *et al.*, 1999). Excluding some exceptional circumstances such as congenital agenesis, certain sesamoid bones are invariably present in all individuals like patella. However, some sesamoid bones are subject to variations such as sesamoid bones of the hand. Therefore, these variable sesamoid bones are generally considered normal anatomic

variations, and are often recognized as an incidental radiograph finding in clinical practice (Amar *et al.*). However, they may participate in various disease processes (Wood). Traumatic conditions include acute fracture, stress fracture, and pseudoarthrosis (Fig. 1) (van der Lei *et al.*, 1995). Neoplastic and arthritic conditions are also encountered, as well as inflammatory and degenerative disorders (Havulinna *et al.*, 2005; Parks & Hamlin, 1986; Whitehouse *et al.*, 2005).

In the hand the sesamoid bones are found on the palmar surface of the several joints. Two, of which the medial is the the larger, are constant at the metacarpophalangeal joint of the thumb; one at the interphalangeal joint of the thumb; one is frequently present in the corresponding joint of the little finger, and one (or two) at the same joint of the index finger. Sesamoid bones are also found occasionally at the metacarpophalangeal joints of the middle and ring fingers and at the distal interphalangeal joint of the index finger. It

* MD. Antalya Education and Research Hospital, Orthopaedics and Traumatology Department, Antalya, Turkey.

**MD. Haydarpasa Numune Education and Research Hospital, Orthopaedics and Traumatology Department, Istanbul, Turkey.

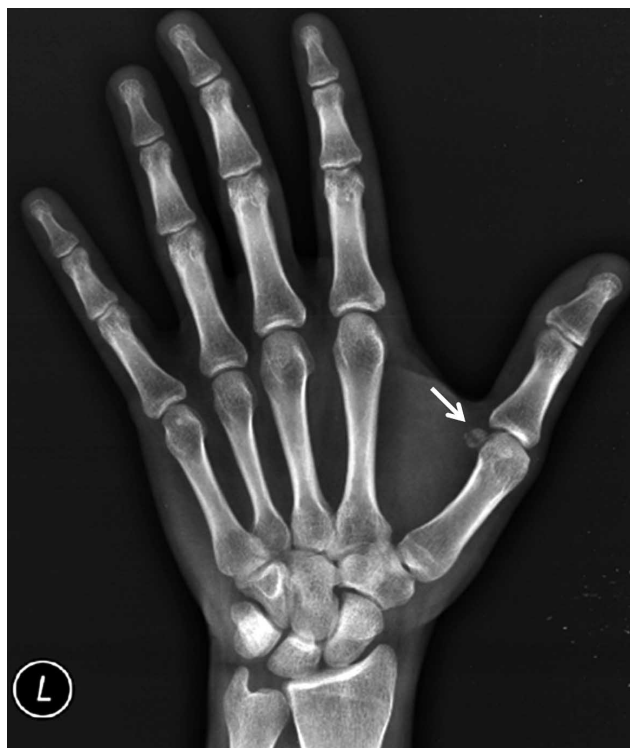

Fig. 1. 30 year-old male patient with fracture of ulnar sesamoid of the thumb (white arrow shows the fracture).

is well known that there is wide variation in the prevalence and distribution of sesamoid bones of the hand in different ethnic groups (Msamati & Igbigbi, 2005). However, the prevalence of sesamoid bones and their distribution in digits of the hand in Turkish population has not been reported yet.

The purpose of this study was to examine the plain anteroposterior radiographs of the hands in Turkish subjects in order to determine the prevalence of sesamoid bones and their distribution. Furthermore, we analyzed the differences between gender and laterality.

MATERIAL AND METHOD

We retrospectively reviewed consecutive adult patients (>18 years of age) whom hand radiographs were taken between January 2011 and December 2011 for all indications from picture archiving and communication systems (PACS) and institutional clinical database. We excluded 94 hand radiographs, in which the sesamoid bones were not clearly depicted due to either incorrect patient positioning making it impossible to judge about the presence of sesamoid bones or all metacarpal and phalangeal bones

of the hand were not demonstrated. Finally, antero-posterior and oblique hand radiographs of 923 (459 male and 464 female) patients with a mean age of 43.76 ± 14.8 years (range, 18-85 years) were eligible and included in this study. There were 530 right and 393 left hand radiographs. All radiographs were of a single hand from each patient, either right or left. The presence of sesamoid bones in various digits and their distribution was recorded by two orthopedic surgeons independently at separate times and any discrepancy was subsequently resolved by consensus. Data on patient age, gender, and hand laterality (right vs. left) were recorded from hospital records. Continuous variables were stated as mean and standard deviation and categorical variables as percentage and frequency distribution. The differences between the sesamoid bones at a particular location and the side and sex were analyzed using Pearson Chi-Square Test. A P-value < 0.05 was considered statistically significant.

RESULTS

In the thumb, two sesamoid bones at the metacarpophalangeal (MCP) joint were present in all subjects (100%). One sesamoid bone was seen palmar to the interphalangeal (IP) joint of the thumb in 197 hands giving an incidence of 21.3%. One sesamoid bone was found palmar to the MCP joint of the index finger in 338 hands showing an incidence of 36.6%. In the little finger one sesamoid bone was seen palmar to the MCP joint in 491 hands showing an incidence of 53.2%. Sesamoid bones palmar to the MCP joints of the middle finger and ring finger were rare; the incidence for these locations being 1.3% (12 hands) and 0.9% (8 hands), respectively. The overall distribution of sesamoid bones and their percentage incidence is shown in Figure 2. The distribution of sesamoid bones in different locations between male and female subjects were statistically similar in 1st IP joint ($p=0.530$), 4th MCP ($p=0.631$), 5th MCP ($p=0.067$) joints. However, the sesamoid bones in 2nd MCP and 3rd MCP joints were statistically more frequent in female subjects ($p=0.024$ and $p=0.018$ respectively) (Table I). There was no statistically significant difference between the laterality and the frequency of sesamoid bones in all locations (Table II). The most common arrangement of sesamoid bones was absence of all sesamoids bones in all locations except 1st MCP joint (Fig. 3). The common arrangement of sesamoid bones is summarized in Table III. The frequency of different sesamoid arrangements between gender and laterality was statistically similar ($p=0.226$ and $p=0.290$ respectively). In one patient, the sesamoid bone of the 2nd MCP joint and in another patient the sesamoid bone of the 5th MCP joint was double in configuration (Fig. 4).

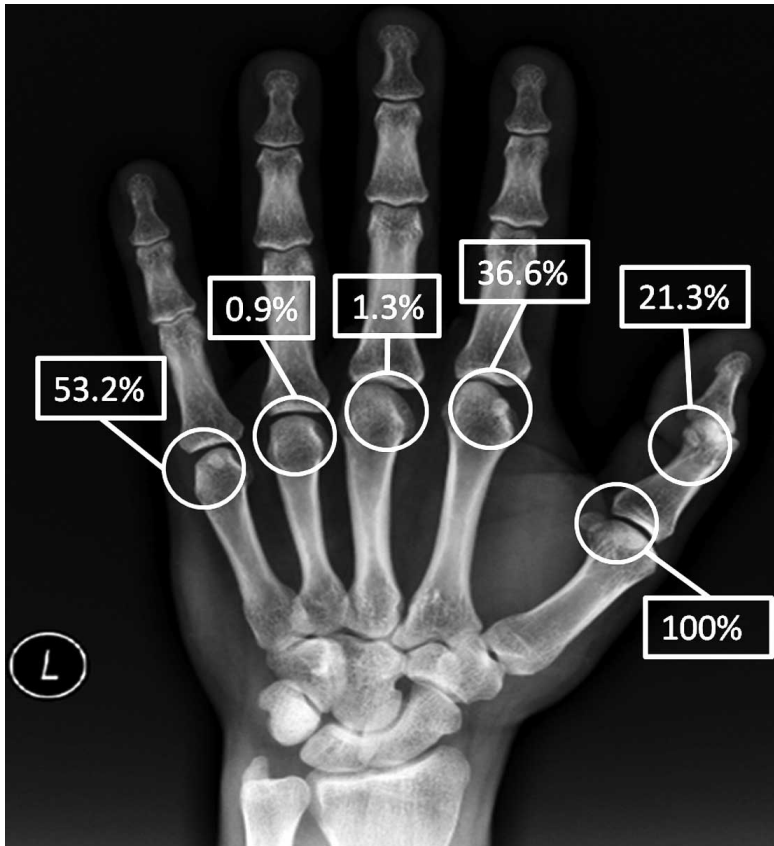


Fig. 2. The distribution of sesamoid bones and their prevalence in the hand.

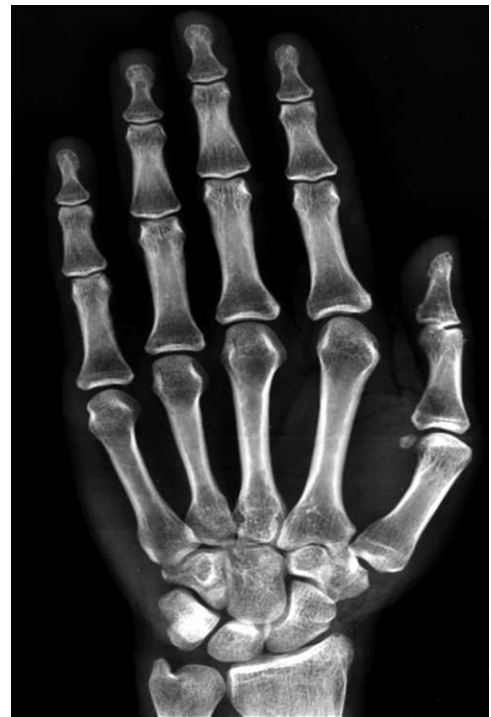

Fig. 3. The most common arrangement of sesamoid bones in Turkish subjects.

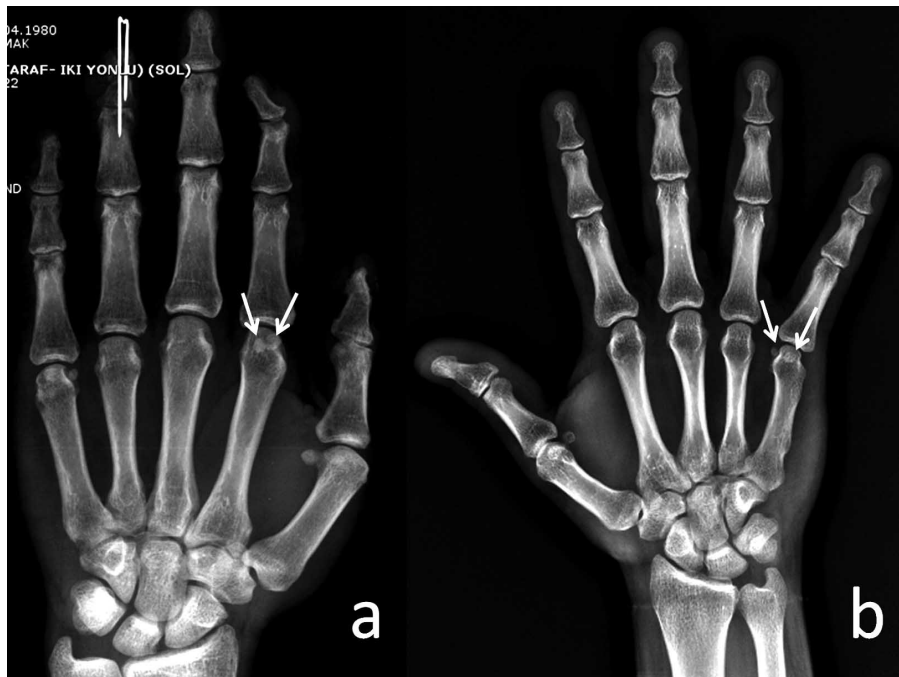


Fig. 4. a. 32 year old male with distal phalangeal fracture had bipartite sesamoid in 2nd MCP joint. b. 28 year old female patient had a bipartite sesamoid in 5th MCP joint (White arrows show the sesamoid bones).

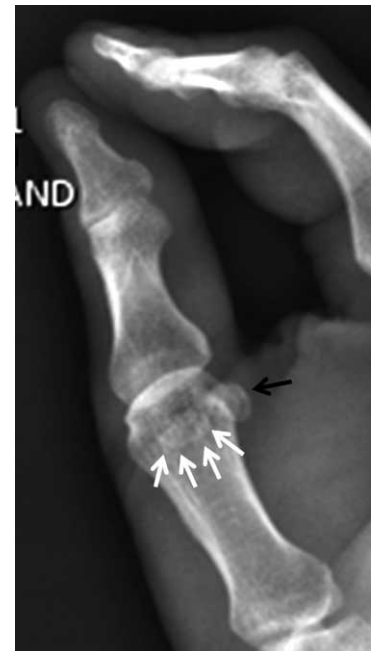


Fig. 5. Superimposition of the radial sesamoid bone with the first metacarpal head. Black arrow shows the ulnar sesamoid which is clearly evident, white arrows show the shadow of the radial sesamoid.

Table I. Differences between male and female subjects. P values are the results of Pearson Chi-Square test.

	1st IP	1st MCP	2nd MCP	3rd MCP	4th MCP	5th MCP
Male (n= 459)	99 (21.3%)	459 (100%)	155 (33.4%)	2 (0.4%)	4 (0.9%)	235 (50.6%)
Female (n= 464)	98 (21.4%)	464 (100%)	183 (39.9%)	10 (2.2%)	4 (0.9%)	256 (55.8%)
Significance (p value)	0.530	--	0.024	0.018	0.631	0.067

Table II. Differences between right and left hands. P values are the results of Pearson Chi-Square test.

	1st IP	1st MCP	2nd MCP	3rd MCP	4th MCP	5th MCP
Right (n= 530)	117 (22.1%)	530 (100%)	192 (36.2%)	10 (1.9%)	5 (0.9%)	284 (53.6%)
Left (n= 393)	80 (20.4%)	393 (100%)	146 (37.2%)	2 (0.5%)	3 (0.8%)	207 (52.7%)
Significance (p value)	0.292	--	0.413	0.058	0.534	0.417

Table III. Most common arrangement of sesamoid bones. [(+) designates the presence, and (-) designates the absence of sesamoid bone.

1st MCP	1st IP	2nd MCP	3rd MCP	4th MCP	5th MCP	Percentage (Frequency)
+	-	-	-	-	-	30.7% (283)
+	-	-	-	-	+	19.9% (184)
+	-	+	-	-	+	19.3% (178)
+	-	+	-	-	-	7.3% (67)
+	+	+	-	-	+	6.9% (64)
+	+	-	-	-	-	6.0% (55)
+	+	-	-	-	+	5.7% (53)
+	+	-	-	-	-	2.2% (20)
+	Other combination of arrangements which included 3rd and/or 4th MCP					2% (19)

DISCUSSION

Several radiographic studies have documented the prevalence and distribution of sesamoid bones of the hand in different ethnic groups (Table IV). The overall prevalence of sesamoid bones palmar to the MCP joint of the thumb ranged between 98.2%-100% in previous studies. In our study and all other studies, authors stated that two sesamoid bones (ulnar and radial) are constant in all cases; expect Bizarro (1921) and Amar *et al.* Bizarro found two cases who lack these almost invariably present sesamoids, and in one case it appeared as a single bone on the ulnar side. On the other hand, Amar *et al.* reported that 27.83% of the cases had only one sesamoid bone palmar to the MCP joint of the thumb (Amar *et al.*). This percentage is considerably high compared to the previously published studies. In standard hand radiographs (antero-posterior and oblique views), the radial sesamoid bone is seen as a shadow just behind the head of first metacarpal due to superimposition (Fig. 5). This

may be an explanation for this different percentage. In Bizarro's hand x-ray series (total 112 hand radiographs) 54 subjects were between 15-25 years of age. Although, the two sesamoid bones in the thumb MCP joint ossifies early at around 10 years of age, ossification thus visibility on x-ray may be completed at around 15 years of age (Bizarro). Dharap *et al.* examined thirty-six 15-year-old children and found 10 children lacking sesamoid bones palmar to the MCP joint (Dharap *et al.*, 2007). This may be the reason why Bizarro found two subjects who lack these sesamoids before these sesamoids ossified. Furthermore, Goldberg *et al.* dissected 50 cadavers, all of whom were elderly individuals. They found that two sesamoids were constantly present in all the dissections (Goldberg & Nathan, 1987). It can be concluded that two sesamoid bones (radial and ulnar) palmar to the MCP joint of the thumb is found in all individuals regardless of ethnic origin, despite extremely rare exceptions.

Table IV. Distribution and percentage frequency of sesamoid bones in the hand. Summary of previous findings and comparison with present results

Author	Year	Ethnicity	Number of subjects	Age	Sex	1st MCP	1st IP thumb	2nd MCP	3rd MCP	4th MCP	5th MCP
Pfitzer ^a	1892	European	388	Adult	-	99.9	72.9	47.9	1.5	0.1	84.7
Fawcett	1896	European	38	Adult	-	100	68.5	55.2	-	-	71
Bizarro	1921	European	112	15-25 years subjects	54 M / 10 F	98.2	22.3	64.2	5.3	7.1	44.6
Joseph	1951	European African	370	Range, 18-63 years	235 M / 135 F	100	100	35	-	-	70
Goldberg	1987	Bedouin	1000	Children	-	100	62	50	3	1	70
Msamati	2001	African	126	Range, 16-66 years	80 M / 46 F	100	100	4.8	-	-	-
Dharap	2007	Arab	213	Range, 18-80 years	178 M / 35 F	100	28.6	40.4	2.3	1.5	45.3
Amar	2011	Mediterranean	442	Mean age 35.4±16.6	296 M / 146 F	99.5	26.2	42.3	1.4	0.2	41.1
Present Study	2012	Turkish	923	Range, 18-85	459 M / 464 F	100	21.3	36.6	1.3	0.9	53.2

^aCited in Fawcett (1896). (Original article: Pfizner W. (1892). Die Sesambeine des Menschlichen Korpers. Morphologische Arbeiten de Schwalbe 1:517-762.)

The prevalence of sesamoid bone in the thumb IP joint shows great variation among different studies. The prevalence of sesamoid bones in the thumb IP joint has been reported to be 100% in two studies (Msamati & Igbigbi; Joseph, 1951). Apart from these two studies, the prevalence of thumb IP joint sesamoid ranged between 72.9% and 22.3% (average 43.1%). In our study, we have found the prevalence to be 21.3% which was the lowest value. Our results are very close to those reported from Arab and Mediterranean populations (28.6% and 26.2% respectively). Similarly, the sesamoid bone of the index and little MCP joint similarly show great variation among different ethnic groups. Interestingly, Msamati *et al.* reported the lowest prevalence both for sesamoid bone of the index and little finger (4.8% and 0%, respectively) in Africans (Msamati & Igbigbi). On the other hand, in other studies, including the present study, the prevalence of index and little sesamoid bone ranged between 35% -64.2% (average, 46.4%), and 41.1%-84.7% (average, 59.9%) respectively. Again, the prevalence of sesamoid bones in the index and little fingers in Turkish subjects seems to be similar to that in Arab and Mediterranean populations. The sesamoid bones of the middle and ring finger are quite rare when compared to other fingers. Bizarro reported the highest frequency in these localizations (5.3% for 3rd digit and 7.1% for 4th digit) but all other previous studies reported similar frequencies ranged between 0%-3% (average, 1.18%) for 3rd digit and 0%-1.5% (average, 0.46%) for 4th digit (Bizarro).

Among previous studies, only Joseph examined the arrangement of sesamoid bones in each individual hand (Joseph). He reported that two thumb MCP sesamoids and thumb IP joint sesamoids were always present. Thus, he classified the hands according to the presence or absence of sesamoid bones in 2nd and 5th digits. According to his study, there was three common type of arrangement of sesamoid bones; absence of all sesamoid bones 2nd through 5th digits (29.9%), presence of 2nd and 5th digit sesamoids (33.4%) and presence of 5th digit sesamoid only (36.6%) (Joseph). In our study we have identified 9 different arrangements of sesamoid bones as shown in Table III. Absence of all sesamoids of the hand, excluding 1st MCP joint, was the most common type of arrangement with a prevalence of 30.7% (283 hands).

Although, Fawcett discussed about the sexual differences, there are only three previous studies which statistically examined the correlation between the gender and laterality with presence or absence of sesamoid bones in the hands (Amar *et al.*; Dharap *et al.*; Fawcett, 1986; Msamati & Igbigbi). All these studies could not show any difference between gender and laterality. Similarly, in our study, we could find any correlation between the laterality and sesamoid bones of the hand in any localization. In contrast to previous findings, we have found sexual differences in 2nd and 3rd MCP joint sesamoid bones. Both were statistically more common in female subjects (p=0.024 and p=0.018 respectively).

Present study has some strengths and limitations. This is largest series of hand radiographs examined in the current literature in adults. All the radiographs were digital, thus observers could subjectively adjust the display parameters such as contrast, opacity and brightness on the

computer screen. This provided a correct identification of all sesamoid bones. Furthermore, two independent observers reviewed all cases to decrease the errors. On the other hand, we could not examine the symmetry patterns, as radiographs were of a single hand from each patient, either right or left.

As a conclusion, the present study represents the first report on the prevalence and distribution of sesamoid bones in the hand in Turkish subjects. The prevalence of sesamoid bones in Turkish population is considerably different from the Africans and Europeans, but rather resembles Mediterranean and Arab populations. Current literature lacks knowledge about the prevalence and distribution of sesamoids of the hand in Asian races that are the significant part of the world population. Furthermore, a symmetry pattern of sesamoid bones of the hand is unknown. Further studies focusing on these lacking issues will be beneficial to improve the knowledge about the sesamoid bones of the hand.

KOSE, O; GULER, F.; TURAN, A.; CANBORA, K. & AKALIN, S. Prevalencia y distribución de los huesos sesamoideos de la mano. Un estudio radiográfico en sujetos turcos. *Int. J. Morphol.*, 30(3):1094-1099, 2012.

RESUMEN: El objetivo de este estudio fue examinar radiografías anteroposteriores de manos en sujetos turcos para determinar la prevalencia y distribución de los huesos sesamoideos. Fueron examinadas 923 radiografías de mano, 459 hombres y 464 mujeres, con edad media de $43,76 \pm 14,8$ años (rango, 18-85 años). Dos huesos sesamoideos (ulnar y radial) estuvieron siempre presentes en la articulación metacarpofalángica (MCF) del primer dedo de la mano (100%). Un solo hueso sesamoideo en la articulación interfalángica (IP) del primer dedo de la mano se observó en el 21,3% de los casos. La prevalencia del hueso sesamoideo, índice y articulación MCP fueron fue de 36,6% y 53,2% respectivamente. Los huesos sesamoideos palmares a las articulaciones metacarpofalángica del dedo medio y dedo anular eran poco frecuentes, su incidencia fue 1,3% (12 manos) y 0,9% (8 manos), respectivamente. No hubo diferencias significativas entre los dígitos izquierdos o derechos. La distribución de los huesos sesamoideos en diferentes lugares entre los sujetos de ambos sexos fueron estadísticamente similares entre las articulaciones primera interfalángica ($p = 0,530$), cuarta MCP ($p = 0,631$) y quinta MCP ($p = 0,067$). Sin embargo, los huesos sesamoideos en las articulaciones segunda MCP y tercera MCP fueron estadísticamente más frecuentes en el sexo femenino ($p = 0,024$ y $p = 0,018$, respectivamente). El presente estudio representa el primer informe sobre la prevalencia y distribución de los huesos sesamoideos en la mano en sujetos turcos. La prevalencia de los huesos sesamoideos en la población turca es considerablemente diferente de los africanos y los europeos, pero se asemeja a las poblaciones mediterráneas y árabes.

PALABRAS CLAVE: Hueso sesamoideo; Mano; Prevalencia; Población turca.

REFERENCES

- Amar, E.; Rozenblat, Y. & Chechik, O. Sesamoid and accessory bones of the hand--an epidemiologic survey in a Mediterranean population. *Clin. Anat.*, 24(2):183-7, 2011.
- Bizarro, A. H. On Sesamoid and Supernumerary Bones of the Limbs. *J. Anat.*, 55(Pt 4):256-68, 1921.
- Dharap, A. S.; Al-Hashimi, H.; Kassab, S. & Abu-Hijleh, M. F. Incidence and ossification of sesamoid bones in the hands and feet: a radiographic study in an Arab population. *Clin. Anat.*, 20(4):416-23, 2007.
- Fawcett, E. The Sesamoid Bones of the Hand: a Skiagraphic Confirmation of the Work done by Pfitzner. *J. Anat. Physiol.*, 31(Pt 1):157-61, 1896.
- Goldberg, I. & Nathan, H. Anatomy and pathology of the sesamoid bones. The hand compared to the foot. *Int. Orthop.*, 11(2):141-7, 1987.
- Havulinna, J.; Parkkinen, J. & Laitinen, M. Aneurysmal bone cyst of the index sesamoid. *J. Hand Surg. Am.*, 30(5):1091-3, 2005.
- Joseph, J. The sesamoid bones of the hand and the time of fusion of the epiphysis of the thumb. *J. Anat.*, 85(3):230-41, 1951.
- Msamati, B. C. & Igbigbi, P. S. Radiographic appearance of sesamoid bones in the hands and feet of Malawian subjects. *Clin. Anat.*, 14(4):248-53, 2001.
- Parks, B. J. & Hamlin, C. Chronic sesamoiditis of the thumb: pathomechanics and treatment. *J. Hand Surg. Am.*, 11(2):237-40, 1986.
- Sarin, V. K.; Erickson, G. M.; Giori, N. J.; Bergman, A. G. & Carter, D. R. Coincident development of sesamoid bones and clues to their evolution. *Anat. Rec.*, 257(5):174-80, 1999.
- van der Lei, B.; van der Linden, E.; Mooyaart, E. L. & Klasen, H. J. Fracture of the thumb sesamoid bone: a report of three cases and a review of the English-language literature. *J. Trauma*, 38(5):836-40, 1995.
- Whitehouse, R. W.; Aslam, R.; Bukhari, M.; Groves, C. & Cassar-Pullicino, V. The sesamoid index in psoriatic arthropathy. *Skeletal Radiol.*, 34(4):217-20, 2005.
- Wood, V. E. The sesamoid bones of the hand and their pathology. *J. Hand Surg. Br.*, 9(3):261-4, 1984.

Correspondence to:
Dr. Ozkan Kose
Kultur mah. 3805.sk Durukent sitesi
F Blok Daire:22 Kepez
Antalya
TURKEY

Received: 08-03-2012
Accepted: 30-06-2012

Email: drozkankose@hotmail.com