

A new Morphological Classification of the Anterior Inferior Iliac Spine. Relevance in Subspine Hip Impingement

Nueva Clasificación Morfológica de la Espina Iliaca Anteroinferior.
Relevancia en el Pinzamiento Subespinoso de la Cadera

Rodolfo Morales-Avalos*; Jorge I. Leyva-Villegas*; Gabriela Sánchez-Mejorada**; Omar Méndez-Aguirre*; Oscar Ulises Galindo-Aguilar*; Alejandro Quiroga-Garza*; Eliud E. Villarreal-Silva*; Félix Vélchez-Cavazos***; José R.B. Galván*; Rodrigo E. Elizondo-Omaña* & Santos Guzmán-López*

MORALES-AVALOS, R.; LEYVA-VILLEGAS, J. I.; SÁNCHEZ-MEJORADA, G.; MÉNDEZ-AGUIRRE, O.; GALINDO-AGUILAR O. U.; QUIROGA-GARZA, A.; VILLARREAL-SILVA, E. E.; VÉLCHEZ-CAVAZOS, F.; GALVÁN, J. R.B.; ELIZONDO-OMANA, R. E. & GUZMÁN-LÓPEZ, S. A new morphological classification of the anterior inferior iliac spine. Relevance in subspine hip impingement. *Int. J. Morphol.*, 33(2):626-631, 2015.

SUMMARY: Femoroacetabular impingement syndrome (FAI) is a clinical entity that has been recognized in recent years as a frequent cause of pain and the early development of hip arthrosis. Subspine hip impingement is characterized by the prominent or abnormal morphology of the anteroinferior iliac spine (AIIS), which contributes to the development of a clinical picture that is similar to FAI. The aims of this study were to propose a new morphological classification of the AIIS, to determine the prevalence of the different AIIS morphologies based on this classification and to correlate the presence of said morphologies with different gender and age groups. The sample consisted of 458 hemipelvises from individuals of known age and sex (264 men and 194 women). Each specimen was analyzed to determine the prevalence of each of the different morphologies of the AIIS based on the classification proposed as Type 1: the presence of a concave surface between the AIIS and the acetabular rim; Type 2A: the presence of a flat surface between the AIIS and the acetabular rim; Type 2B the presence of a convex surface between the AIIS and the acetabular rim; and Type 3: the AIIS protrudes inferiorly toward the anterior acetabulum. A prevalence of 69.87% was determined for Type 1 AIIS (320/458). In regard to abnormal morphology, prevalences of 17.90% (82/458), 3.71% (17/458) and 8.52% (39/458) were determined for type 2A, Type 2B and Type 3, respectively. The prevalence of abnormal AIIS morphology was 30.30% (80/264) in male specimens and 29.90% (58/194) in female specimens. This study demonstrates the prevalence of the different morphologies of the AIIS, providing information that will be useful in determining the role of the AIIS in the emergence of subspine hip impingement.

KEY WORDS: Prevalence; Anterior inferior iliac spine; Subspine impingement; Classification; Morphology; Hip.

INTRODUCTION

Femoroacetabular impingement syndrome (FAI) is a clinical entity that has been recognized in recent years as a frequent cause of pain and the early development of hip arthrosis (Ganz *et al.*, 2003). Structural abnormalities associated with the development of this disease include abnormal morphology of the femoral head-neck complex and the acetabulum, which causes chronic pain and functional limitation of the hip (Beck *et al.*, 2005; Ganz *et al.*, 2008).

Currently of interest are extra-articular sources of FAI, which may cause a small proportion of FAI cases and are exemplified by trochanteric-pelvic, ischiofemoral and subspine impingement (Pan *et al.*, 2011; Hapa *et al.*, 2013; de Sa *et al.*, 2014).

Subspine hip impingement is characterized by the prominent or abnormal morphology of the anteroinferior iliac spine (AIIS), which contributes to the development of a clinical

* Department of Human Anatomy, Faculty of Medicine, Universidad Autónoma de Nuevo León (U.A.N.L.), Monterrey, Mexico.

** Laboratory of Physical Anthropology, Department of Anatomy, Faculty of Medicine, Universidad Nacional Autónoma de México (U.N.A.M.), Mexico City, Mexico.

*** Orthopedics and Traumatology Service, University Hospital "Dr. José Eleuterio González", Universidad Autónoma de Nuevo León (U.A.N.L.), Monterrey, Mexico.

picture that is similar to FAI. In this presentation, hip flexion greater than 90 degrees results in abnormal AIIS contact against the femoral neck and the soft tissues that lie between them. An improvement in pain, function, and range of motion is observed after arthroscopic decompression of a prominent AIIS (Hapa *et al.*; Pan *et al.*).

The diagnosis and treatment of subspine hip impingement due to abnormal morphology or a hypertrophic AIIS have become more common. It is important to consider diagnostic and therapeutic options for this relatively new disease in patients with pain and functional limitation of the hip.

Pan *et al.*, described a case of surgical treatment of hip impingement caused by AIIS hypertrophy with satisfactory clinical results in a 30-year-old male patient with a high degree of physical activity. Hetsroni *et al.* (2012) treated ten patients for extraarticular hip joint impingement of the AIIS using arthroscopic decompression with a mean follow-up of 14.7 months, demonstrating clinical and functional improvement. Larson *et al.* (2011) described the surgical treatment and outcome of three cases of subspine hip impingement due to abnormal AIIS morphology that were treated by surgical decompression with one year of follow-up and favorable outcomes. Amar *et al.* (2013) described the size, position and location of the AIIS in their study with regard to patient sex and age and concluded that there were no significant differences in these parameters. Other studies have reported isolated cases or series of cases with fractures and avulsions of the AIIS (Rajasekhar *et al.*, 2001; Yildiz *et al.*, 2003, 2005).

Hetsroni *et al.* (2013) proposed a morphological classification of AIIS. In this classification, three types of AIIS are identified based on the relationship between the distal extension of the acetabular rim and the AIIS. They proposed their classification using 53 three-dimensional computed tomography (CT) reconstructions in patients with symptomatic hip impingement undergoing arthroscopic treatment, and they determined the ranges of motion associated with each of the morphologies studied. The hypothesis of our study is that additional AIIS morphologies exist that have not been previously analyzed in other studies.

The aim of this study is to propose a new morphological classification of AIIS using a sample of bone specimens and to determine the prevalence of the different AIIS morphologies according to sex, age and laterality.

MATERIAL AND METHOD

We performed an observational, cross-sectional, descriptive, comparative study. The sample consisted of 458 dry hemipelvises from a Mexican population of known gender and age (264 men and 194 women with an age range between 18 and 100 years). Specimens with structural damage were excluded.

The specimens were divided into groups according to sex; these groups were then subdivided into three subgroups based on age, resulting in six study groups (women 18 to 39 years, women 40 to 59 years, women ≥60 years, men 18–39 years, men 40 to 59 years and men ≥60 years), as shown in Table I.

Each specimen was analyzed independently by the first and second authors, who were blinded to each other's findings. The prevalence of each of the different AIIS morphologies was determined based on the new classification proposed in this study (Fig. 1).

Type 1: Presents a notch or a concave surface between the AIIS and the acetabular rim, whereby the surface does not contact and is not part of the acetabular rim.

Type 2A: Presents a flat surface between the AIIS and the acetabular rim, whereby the surface reaches the acetabular rim but is not continuous.

Type 2B: Presents a convex surface (with or without bony prominences) between the AIIS and the acetabular rim, which continues directly with the acetabular rim.

Type 3: Presents an AIIS that protrudes into the acetabulum inferiorly with invasion of the acetabular rim, interfering with the continuity of the same in its anterosuperior portion

Table I. Distribution of specimens used according to sex and age.

Age range (ye ars)	Male	Female	Total
18–39	106 (40.15%)	54 (27.84%)	160
40–59	100 (37.87%)	68 (35.05%)	168
≥60	58 (21.96%)	72 (37.11%)	130
Total	264 (100%)	194 (100%)	458

or presents a large anterior bony prominence with multiple spiculae and/or protruding bone.

Statistical analysis. Statistical analysis was performed using SPSS Version 19.0 for Windows XP. The prevalence of the different AIIS morphologies was determined. Interobserver agreement of the AIIS classification system was determined between the first two authors of the study by calculating the Kappa coefficient.

Ethical Considerations. This protocol was approved by the local Committee for Health Research under registration number AH14-003.

RESULTS

To demonstrate the results of this study, all specimens classified as Type 1 by the proposed classification (the presence of a notch or concave surface between the AIIS and the acetabular rim) were considered as "normal morphology" (based on the classical anatomical literature) (Testud & Latarjet, 1951; Quiroz-Gutierrez, 1977; Lockhart *et al.*, 2001). "Abnormal morphology" was represented by Types 2A, 2B and 3. The interobserver agreement for the application of the proposed morphological classification yielded an excellent concordance (kappa: 0.9031).

Prevalence. A prevalence of 69.87% for AIIS Type 1 (320/458) was obtained. "Abnormal" morphologies (2A, 2B and 3, combined) had a prevalence of 30.13% (138/458).

Regarding abnormal morphology across the entire sample, a prevalence of 17.90% (82/458) was observed for Type 2A, 3.71% (17/458) for type 2B, and 8.52% (39/458) for Type 3.

Among all osteologic specimens in which the presence of an abnormal AIIS morphology was determined (138 hemipelvises), 59.42% were Type 2A, 12.32% were Type 2B, and 28.26% were Type 3.

The prevalence of abnormal AIIS morphology in male specimens was 30.30% (80/264), and in females it was 29.90% (58/194). The prevalence by age group is shown in Table II.

The laterality of the total AIIS with abnormal morphology (138 hemipelvises, regardless of sex), was left sided in 44.93% (62/138) and right sided in 55.07% (76/138).

DISCUSSION

The AIIS is located in the anterior superior portion of the acetabular rim and represents the site of origin of the direct head of the rectus femoris muscle (Hapa *et al.*). The

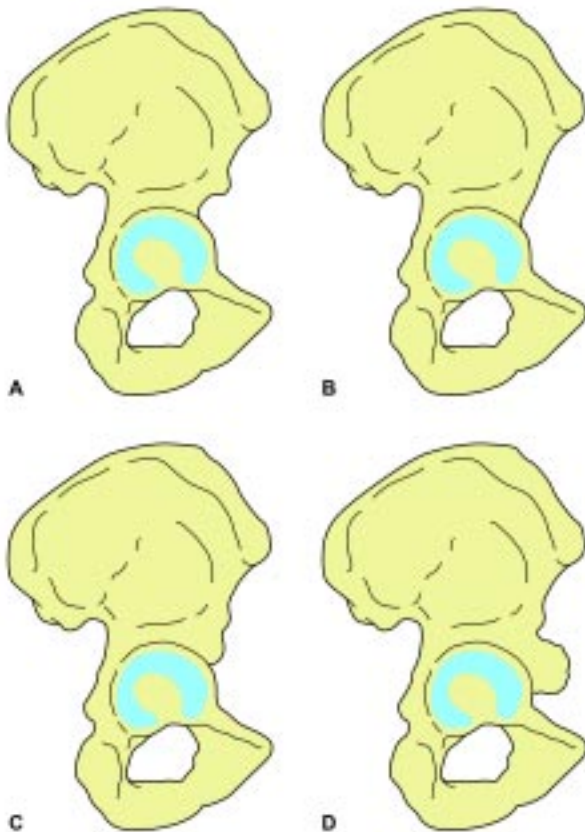


Fig. 1. New morphological classification proposed in this study of the anterior inferior iliac spine. A= Type 1; B= Type 2A; C= Type 2B and D= Type 3.

Table II. Prevalence of different AIIS morphologies in men and women.

Age group (years)	Type 1	Type 2A	Type 2B	Type 3
Men				
18–39 (n= 106)	66.04% (70)	23.58% (25)	1.89% (2)	8.49% (9)
40–59 (n= 100)	69.00% (69)	17.00% (17)	5.00% (5)	9.00% (9)
≥60 (n= 58)	77.59% (45)	8.62% (5)	5.17% (3)	8.62% (5)
Women				
18–39 (n= 54)	79.63% (43)	11.11% (6)	1.85% (1)	7.41% (4)
40–59 (n= 68)	63.24% (43)	26.47% (18)	2.94% (2)	7.35% (5)
≥60 (n= 72)	69.44% (50)	15.28% (11)	5.56% (4)	9.72% (7)

AIIS is located outside the joint capsule of the hip joint, and its abnormal morphology may result in dysfunction of the hip and clinical symptoms (Ryan *et al.*, 2014). The new classification proposed in this study will provide the morphological basis for conducting further clinical studies in different populations and will aid in relating the different types of AIIS with the potential for the development of symptomatic impingement.

The causes of hyperplasia or malformation of the AIIS have not been well described thus far. Because of vigorous contraction of the rectus femoris muscle, an avulsion fracture may occur due to the excessive application of stress on the AIIS. Those forces that are not strong enough to cause an avulsion fracture may result in hypertrophy of the AIIS (Amar *et al.*).

The only existing morphological classification of AIIS was proposed by Hetsroni *et al.* (2013). They used three-dimensional reconstructions of the bony pelvis from 53 CT scans of patients between 15 and 30 years of age who had symptomatic impingement of the hip; these patients were subjected to arthroscopic procedures as part of their treatment. This classification establishes three types (type I, type II and type III) of possible AIIS morphologies. Type I morphology is characterized by a smooth bone wall (without bony prominences) that separates the inferior border of the AIIS from the acetabular ring, which may somewhat be likened to the Type 1 and Type 2A morphologies proposed in this study. However, our study provides a separation between these two types because of the clear morphological differentiation between them and the concept that in Type 2 AIIS, a decrease in the maximum degree of flexion of the hip would be afforded by its morphology along with a reduction in the space available for the glenoid labrum, the joint capsule, and the direct head of the rectus femoris muscle.

In the classification by Hetsroni *et al.* (2013), Type II morphology is characterized by the presence of bony protrusions on the ilium wall that extend from the AIIS to the acetabular ring; alternatively, the AIIS is positioned just above the acetabular ring. This morphology might be compared to the Type 2B classification proposed in this study; however, important differences warrant consideration: in our study, this morphology was classified according to those specimens that had a convex bone surface between the lower edge of the AIIS and the acetabular rim (with or without the presence of bony prominences). Importantly, the AIIS was observed immediately above the acetabular rim in only a few cases; however, a bone surface was present separating the acetabular rim, which was considered in the classification of the different morphologies proposed herein. This morphology may significantly limit

the range of terminal hip flexion, and such patients with this morphology may be more likely to develop subspine hip impingement and to present a more profound clinical picture.

Type III morphology in the classification proposed by Hetsroni *et al.* (2013) is characterized by distal extension of the AIIS to the acetabular ring, interfering with the continuity of the same. In our study, we consider the same morphology, adding an alternate morphology to this class in which a large anterior protrusion of the AIIS with multiple spiculations and/or protruding bone is present. The presence of this morphology correlates with the maximum decrease in ranges of motion of the hip joint, a large decrease in the space available to house the associated soft tissues, and the presence of a more severe clinical picture of hip impingement.

Among the advantages of the proposed new morphological classification is that it was developed in bone specimens; thus, the morphological changes of the AIIS were evaluated in detail. Another advantage over the classification based on three-dimensional reconstructions is that the supine position in which the patient is placed to perform CT might alter the normal position of the AIIS. Additionally, the present study was conducted in osteological specimens from a general population. This feature is a strength of the study because this allowed us to determine more accurately the prevalence of the different morphologies of the AIIS, reducing the possibility of selection and confusion bias. Another strength of this study is a considerably larger number of samples. The morphologies proposed in this classification may easily be evaluated using three-dimensional CT reconstructions.

Variations with respect to age and sex. In men from the 18–39 year-old group, a lower prevalence of Type 1 morphology (66.04%) was observed; this prevalence increased in the 40–59-year age group (69.00%) and in the group aged greater than 60 years (77.59%) (Table II). This finding suggests that the prevalence of "abnormal" morphology (Types 2A, 2B and 3) most commonly occurs in young men. Additionally, this finding may be related to the increased mechanical demand that the AIIS is subjected to due to the large amount of physical activity performed at this stage of life, thus increasing the frequency and the intensity of contractions of the rectus femoris muscle. A decrease in the prevalence of Type 2A morphology was observed with age, with higher prevalence in the 18 to 39 year-old group (23.58%), which decreased in the 40 to 59 year-old group (17.00%) and in the group greater than 60 years of age (8.62%). The lowest prevalence was obtained for the Type 2B morphology in all study groups. We consider

this morphology a "transition stage" between Type 2A and Type 3. The prevalence of Type 3 morphology remained constant throughout the study (Table II).

In women, the prevalent morphology was Type 1, which showed a higher prevalence in the group of 18–39, showing lower prevalences in the older age groups. Type 2A morphology was more prevalent in the group of 40–59 years, the lowest prevalence was obtained in the group of 18-39 years old. The Type 2B morphology followed a progressive pattern of prevalence from younger to older age groups. Type 3 morphology remained a constant prevalence in the group of 18–39 years and 40–59 and the prevalence

increased slightly in the larger group of 60 years (Table II).

This study proposes a morphological classification of the AIIS supported by abundant morphological data and establishes variations according to sex and age.

ACKNOWLEDGEMENTS

The authors wish to thank anthropologist Guillermo Torres for the help and technical assistance he provided in the performance of this study.

MORALES-AVALOS, R.; LEYVA-VILLEGAS, J. I.; SÁNCHEZ-MEJORADA, G.; MÉNDEZ-AGUIRRE, O.; GALINDO-AGUILAR O. U.; QUIROGA-GARZA, A.; VILLARREAL-SILVA, E. E.; VÍLCHEZ-CAVAZOS, F.; GALVÁN, J. R.B.; ELIZONDO-OMAÑA, R. E. & GUZMÁN-LÓPEZ, S. Nueva clasificación morfológica de la espina iliaca anteroinferior. Relevancia en el pinzamiento subespino de la cadera. *Int. J. Morphol.*, 33(2):626-631, 2015.

RESUMEN: El Síndrome de Pinzamiento Femoroacetabular (PFA) es una entidad clínica reconocida en los últimos años como una causa de dolor y desarrollo de artrosis temprana de cadera. El pinzamiento subespino de la cadera se caracteriza por una espina iliaca anteroinferior (EIAI) prominente o con una morfología anormal, lo que contribuye al desarrollo de un cuadro clínico similar al PFA. El objetivo fue proponer una nueva clasificación morfológica de la EIAI y determinar las prevalencias de las distintas morfologías de la EIAI en base a la misma y correlacionarla con los distintos sexos y grupos de edad. La muestra consistió en un total de 458 hemipelvis, de sexo y edad conocidos (264 hombres y 194 mujeres). Cada pieza fue analizada para determinar la prevalencia de variaciones morfológicas de la EIAI en base a la clasificación propuesta. Tipo 1: presencia de una superficie cóncava entre la EIAI y reborde acetabular, Tipo 2A: presencia de una superficie plana entre la EIAI y el reborde acetabular, Tipo 2B: presencia de una superficie convexa entre la EIAI y el reborde acetabular y Tipo 3: la EIAI protruye hacia el acetábulo anterior o inferiormente. Se determinó una prevalencia de 69,87% para la EIAI Tipo 1 (320/458). En cuanto a las morfologías anormales, se determinó una prevalencia de 17,90% (82/458), 3,71% (17/458) y 8,52% (39/459) para los Tipos 2A, 2B y 3, respectivamente. La prevalencia de una morfología anormal en las EIAI de especímenes del sexo masculino fue de 30,30% (80/264) y en el sexo femenino 29,90% (58/194). Se evidencia la prevalencia de las diferentes morfologías que puede tener la EIAI; esta información será de ayuda para determinar el papel de la EIAI en la aparición del pinzamiento subespino de la cadera.

PALABRAS CLAVE: Prevalencia; Espina iliaca anteroinferior; Pinzamiento subespino; Clasificación; Morfología; Cadera.

REFERENCES

- Amar, E.; Druckmann, I.; Flusser, G.; Safran, M. R.; Salai, M. & Rath, E. The anterior inferior iliac spine: size, position, and location. An anthropometric and sex survey. *Arthroscopy*, 29(5):874-81, 2013.
- Beck, M.; Kalhor, M.; Leunig, M. & Ganz, R. Hip morphology influences the pattern of damage to the acetabular cartilage: femoroacetabular impingement as a cause of early osteoarthritis of the hip. *J. Bone Joint Surg. Br.*, 87(7):1012-8, 2005.
- de Sa, D.; Alradwan, H.; Cargnelli, S.; Thawer, Z.; Simunovic, N.; Cadet, E.; Bonin, N.; Larson, C. & Ayeni, O. R. Extra-articular hip impingement: a systematic review examining operative treatment of psoas, subspine, ischiofemoral, and greater trochanteric/pelvic impingement. *Arthroscopy*, 30(8):1026-41, 2014.
- Ganz, R.; Leunig, M.; Leunig-Ganz, K. & Harris, W. H. The etiology of osteoarthritis of the hip: an integrated mechanical concept. *Clin. Orthop. Relat. Res.*, 466(2):264-72, 2008.
- Ganz, R.; Parvizi, J.; Beck, M.; Leunig, M.; Nötzli, H. & Siebenrock, K. A. Femoroacetabular impingement: a cause for osteoarthritis of the hip. *Clin. Orthop. Relat. Res.*, (417):112-20, 2003.

- Hapa, O.; Bedi, A.; Gursan, O.; Akar, M. S.; Güvencer, M.; Havitcioglu, H. & Larson, C. M. Anatomic footprint of the direct head of the rectus femoris origin: cadaveric study and clinical series of hips after arthroscopic anterior inferior iliac spine/subspine decompression. *Arthroscopy*, 29(12):1932-40, 2013.
- Hetsroni, I.; Larson, C. M.; Dela Torre, K.; Zbeda, R. M.; Magennis, E. & Kelly, B. T. Anterior inferior iliac spine deformity as an extra-articular source for hip impingement: a series of 10 patients treated with arthroscopic decompression. *Arthroscopy*, 28(11):1644-53, 2012.
- Hetsroni, I.; Poultides, L.; Bedi, A.; Larson, C. M. & Kelly, B. T. Anterior inferior iliac spine morphology correlates with hip range of motion: a classification system and dynamic model. *Clin. Orthop. Relat. Res.*, 471(8):2497-503, 2013.
- Larson, C. M.; Kelly, B. T. & Stone, R. M. Making a case for anterior inferior iliac spine/subspine hip impingement: three representative case reports and proposed concept. *Arthroscopy*, 27(12):1732-7, 2011.
- Lockhart, R. D.; Hamilton, G. F. & Fyfe, F. W. *Anatomía Humana*. México D. F., McGraw-Hill Interamericana, 2001.
- Pan, H.; Kawanabe, K.; Akiyama, H.; Goto, K.; Onishi, E. & Nakamura, T. Operative treatment of hip impingement caused by hypertrophy of the anterior inferior iliac spine. *J. Bone Joint Surg. Br.*, 90(5):677-9, 2008.
- Quiroz-Gutierrez, F. *Tratado de Anatomía Humana*. México D. F., Porrúa, 1977.
- Rajasekhar, C.; Kumar, K. S. & Bhamra, M. S. Avulsion fractures of the anterior inferior iliac spine: the case for surgical intervention. *Int. Orthop.*, 24(6):364-5, 2001.
- Ryan, J. M.; Harris, J. D.; Graham, W. C.; Virk, S. S. & Ellis, T. J. Origin of the direct and reflected head of the rectus femoris: an anatomic study. *Arthroscopy*, 30(7):796-802, 2014.
- Testut, L. & Latarjet, A. *Tratado de Anatomía Humana*. 9th ed. Barcelona, Salvat, 1951.
- Yildiz, C.; Aydin, T.; Yildiz, Y.; Kalyon, T. A. & Basbozkurt, M. Anterior inferior iliac spine apophyseal avulsion fracture. *J. South Orthop. Assoc.*, 12(1):38-40, 2003.
- Yildiz, C.; Yildiz, Y.; Ozdemir, M. T.; Green, D. & Aydin, T. Sequential avulsion of the anterior inferior iliac spine in an adolescent long jumper. *Br. J. Sports Med.*, 39(7):e31, 2005.

Correspondence to:
Rodrigo E. Elizond-Omaña, M.D. PhD.
Department of Human Anatomy
Faculty of Medicine
Universidad Autónoma de Nuevo León (U.A.N.L.)
Ave. Madero s/n Col. Mitras Centro
Monterrey, Nuevo León
C.P. 64460
MEXICO

Email: rod_omana@yahoo.com

Received: 01-12-2014

Accepted: 09-04-2015